

# The Role of the Dermatopathologist in the Diagnosis of soft Tissue and Skin infectious Diseases

A. Theunis, U. Sass, J. André

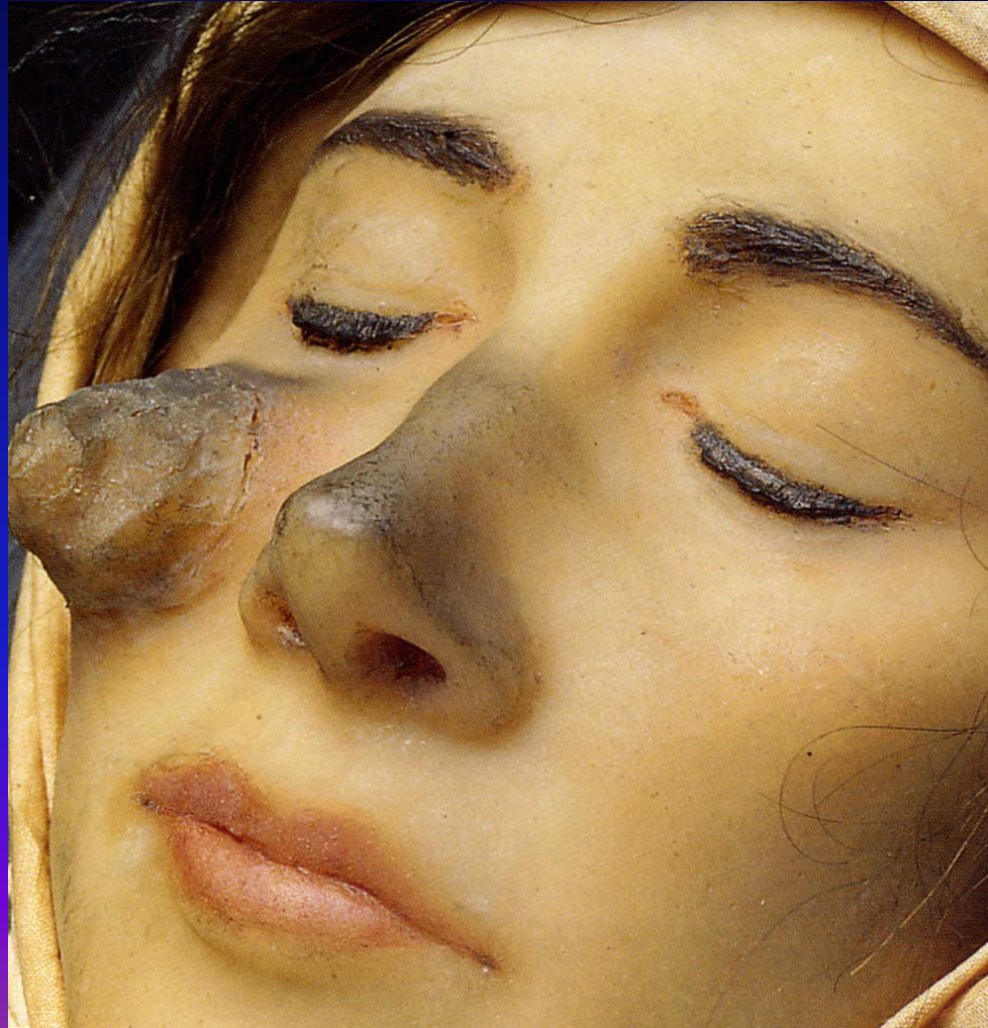**DERMATOPATHOLOGY UNIT**  
**CHU Saint-Pierre, CHU Brugmann, HUDERF**

# **Clinical Cases**

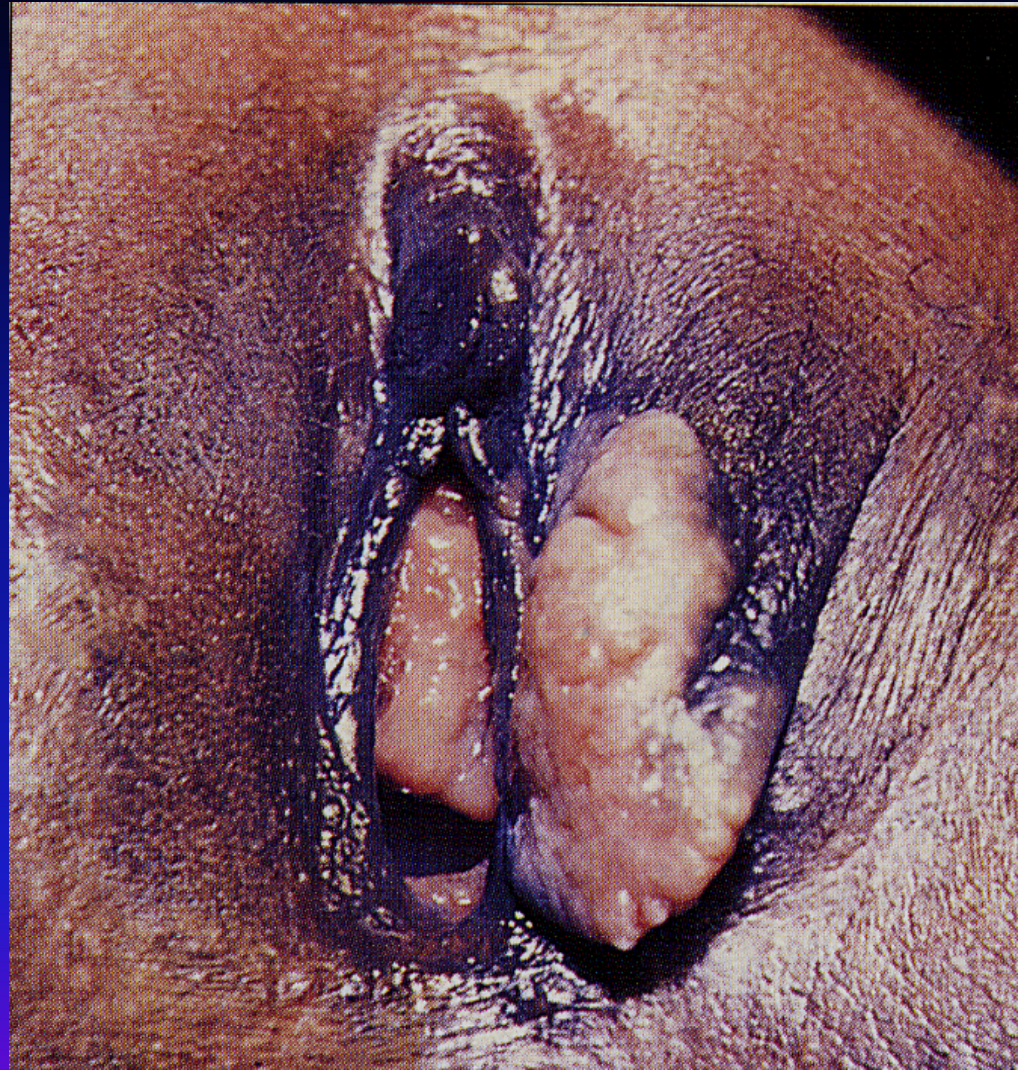- **Infiltrated, nodular and pseudotumoral lesions**
- **Erythematous-squamous and atrophic lesions**
- **Ulcerative lesions**
- **Blistering lesions**
- **Fasciitis**



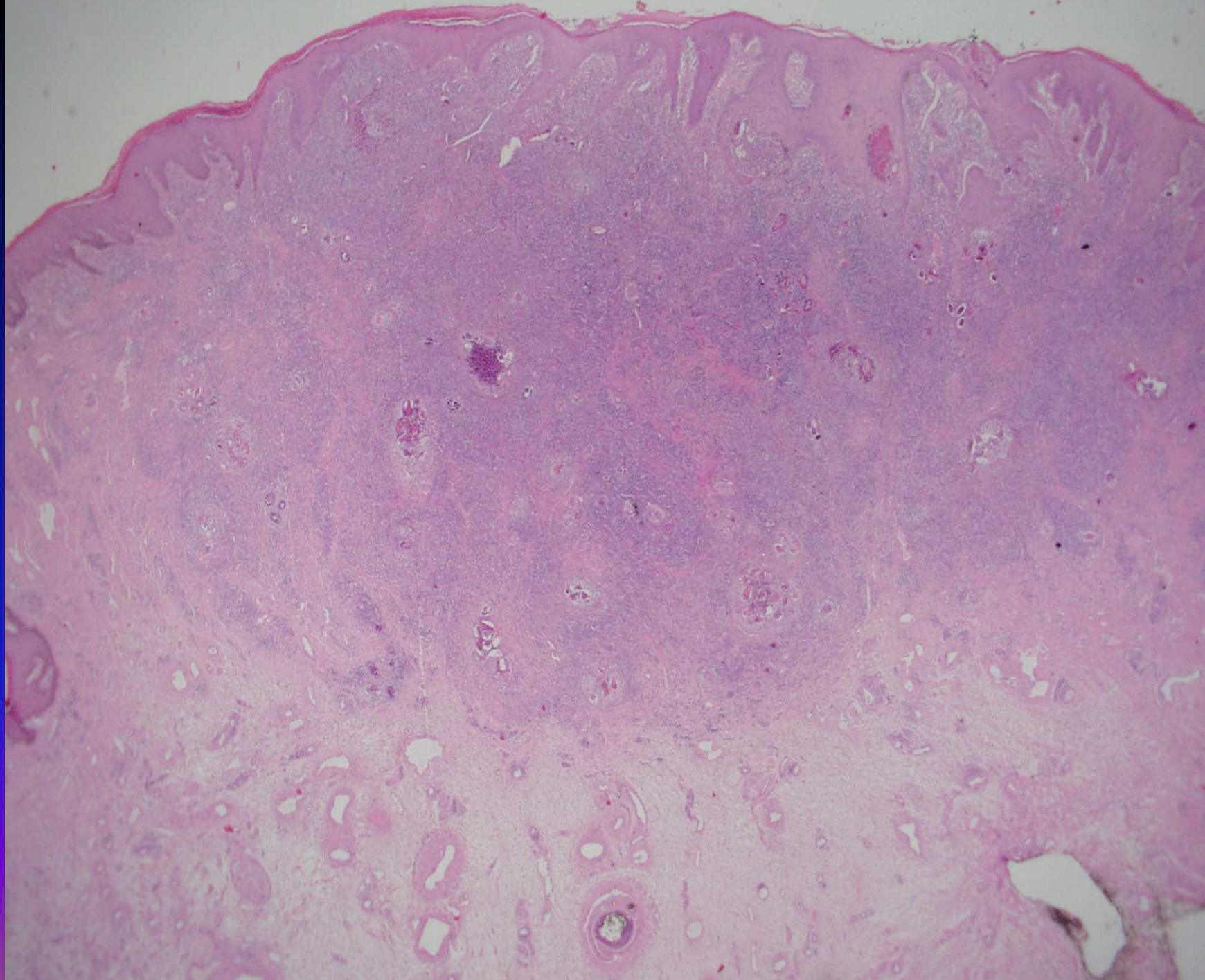
# Infiltrated, nodular and pseudotumoral lesions



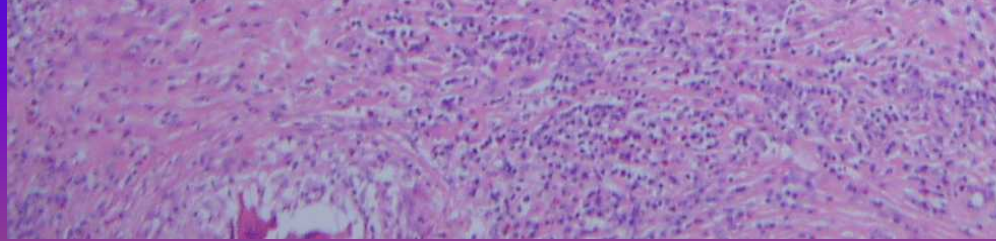
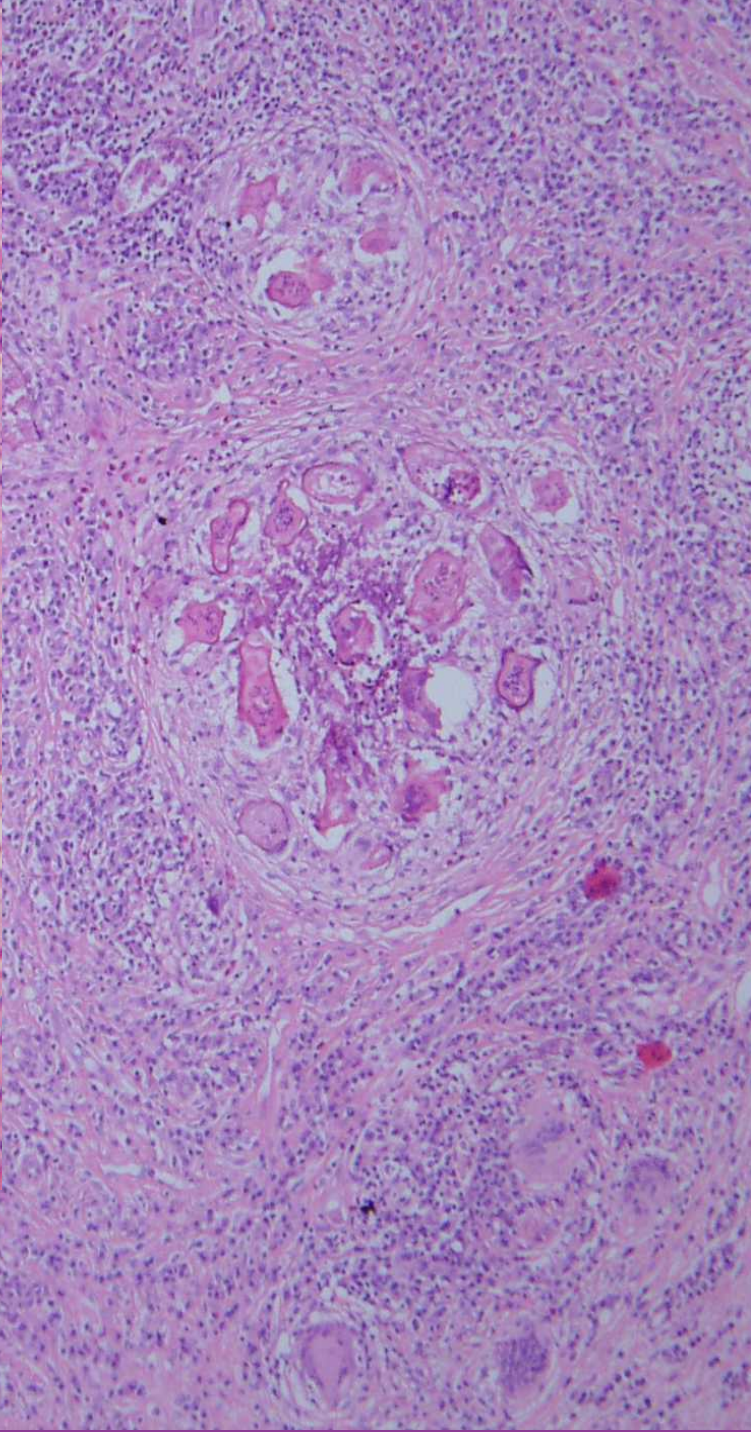
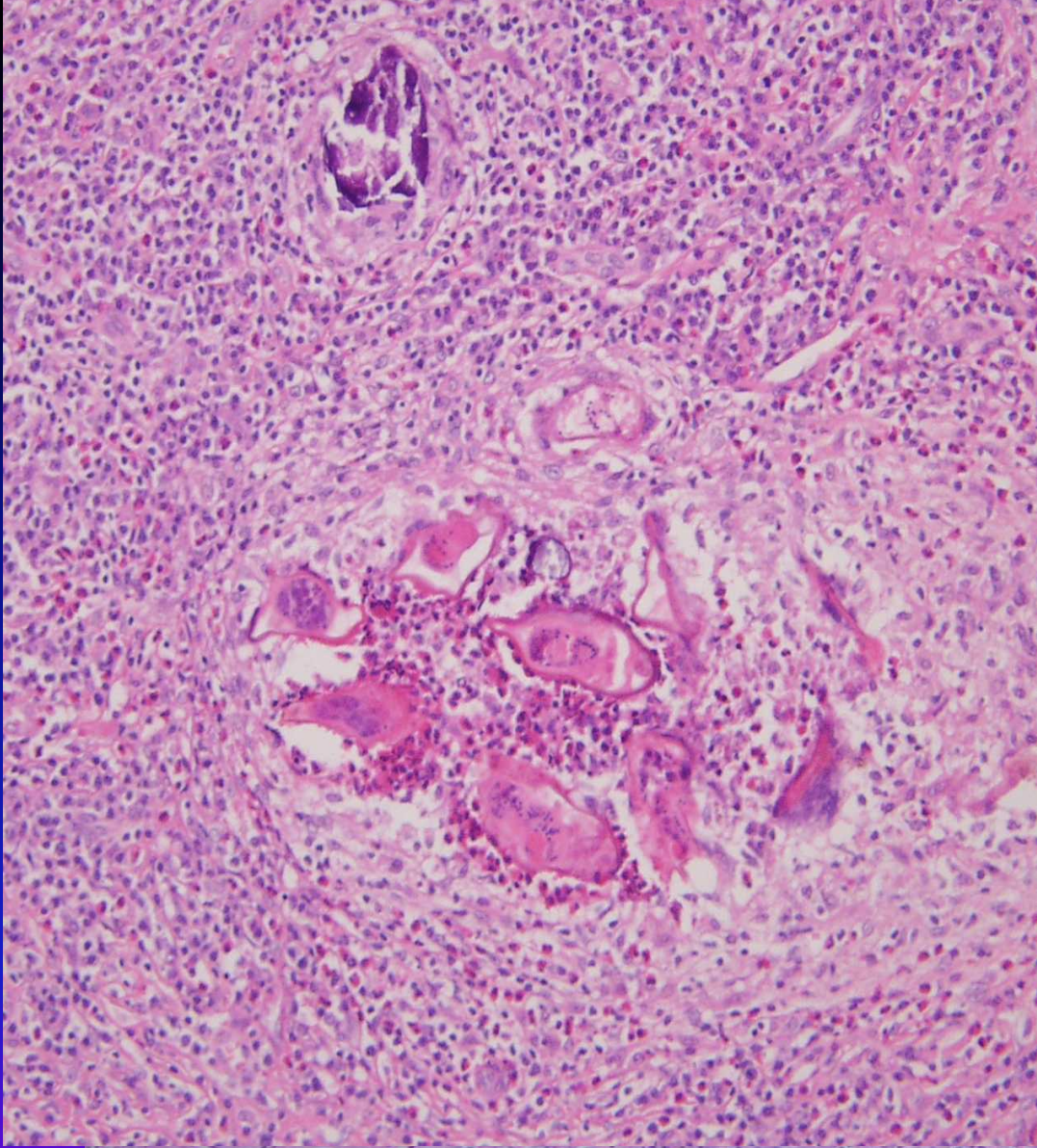
- 19-year-old, African, pregnant woman
- At delivery, removal of a verrucous lesion located on the vulva, evolving for several months



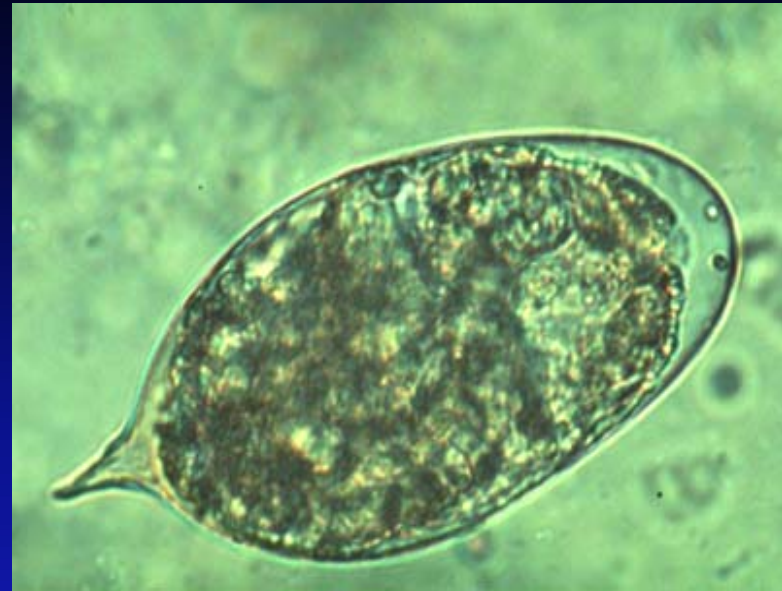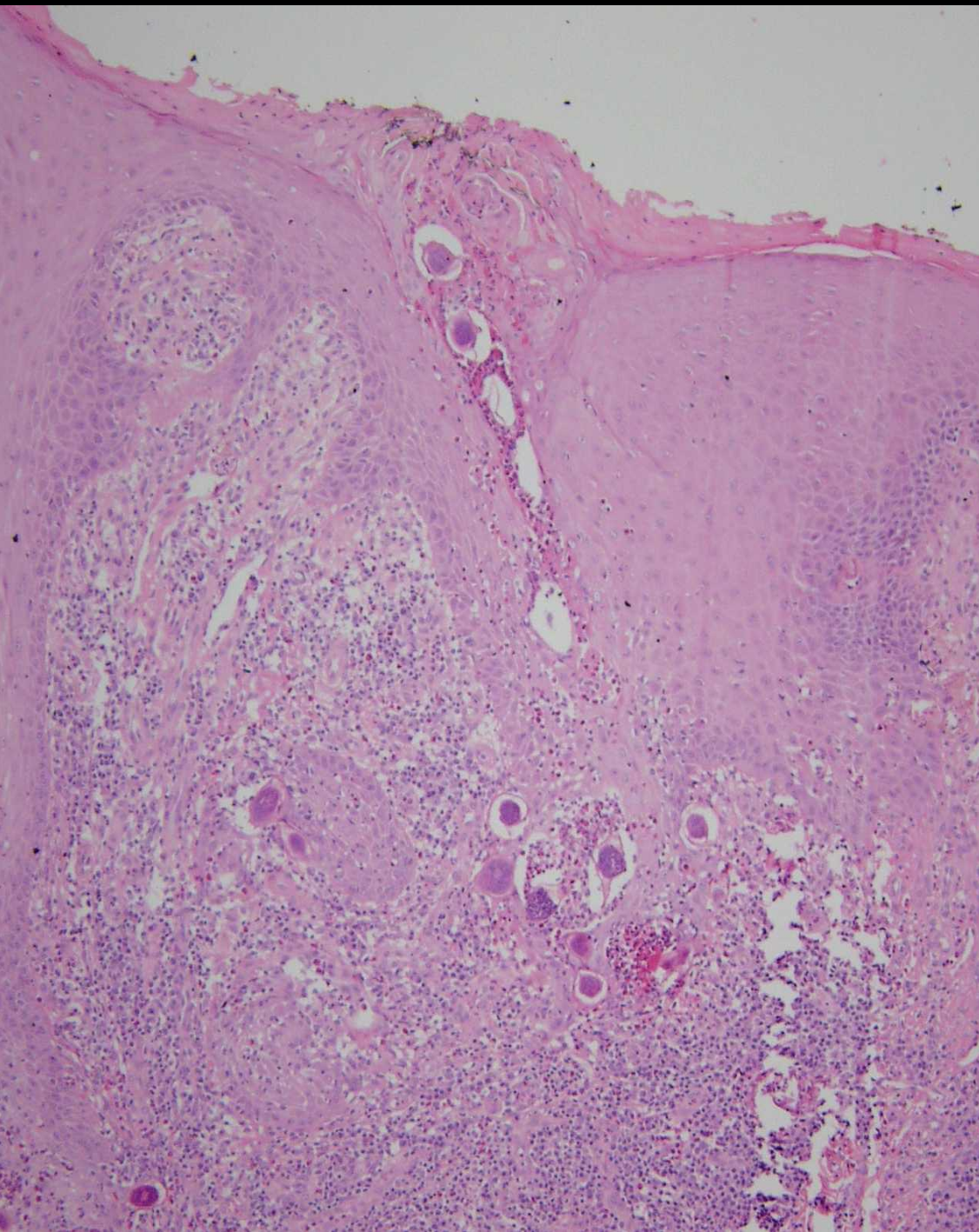




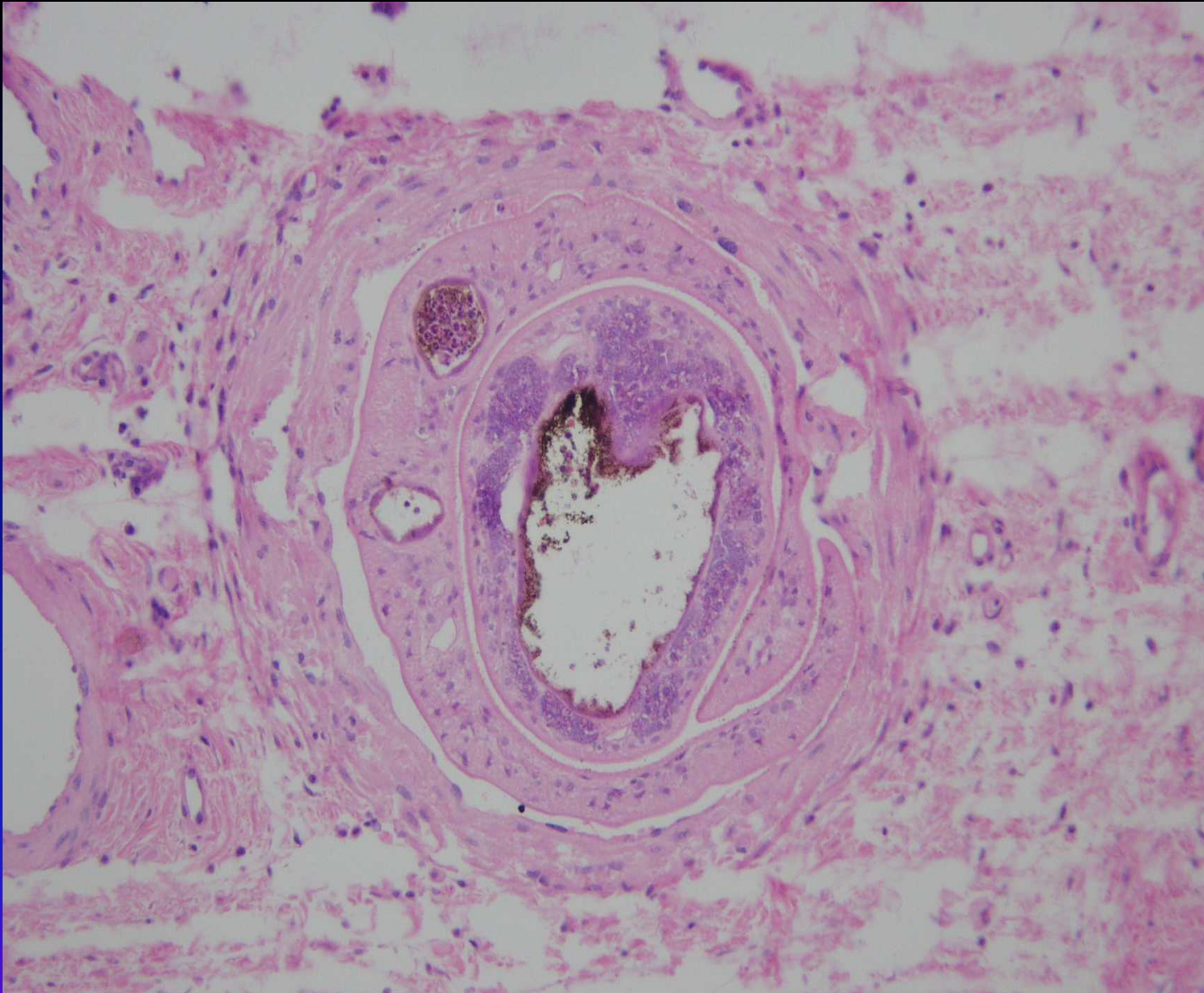




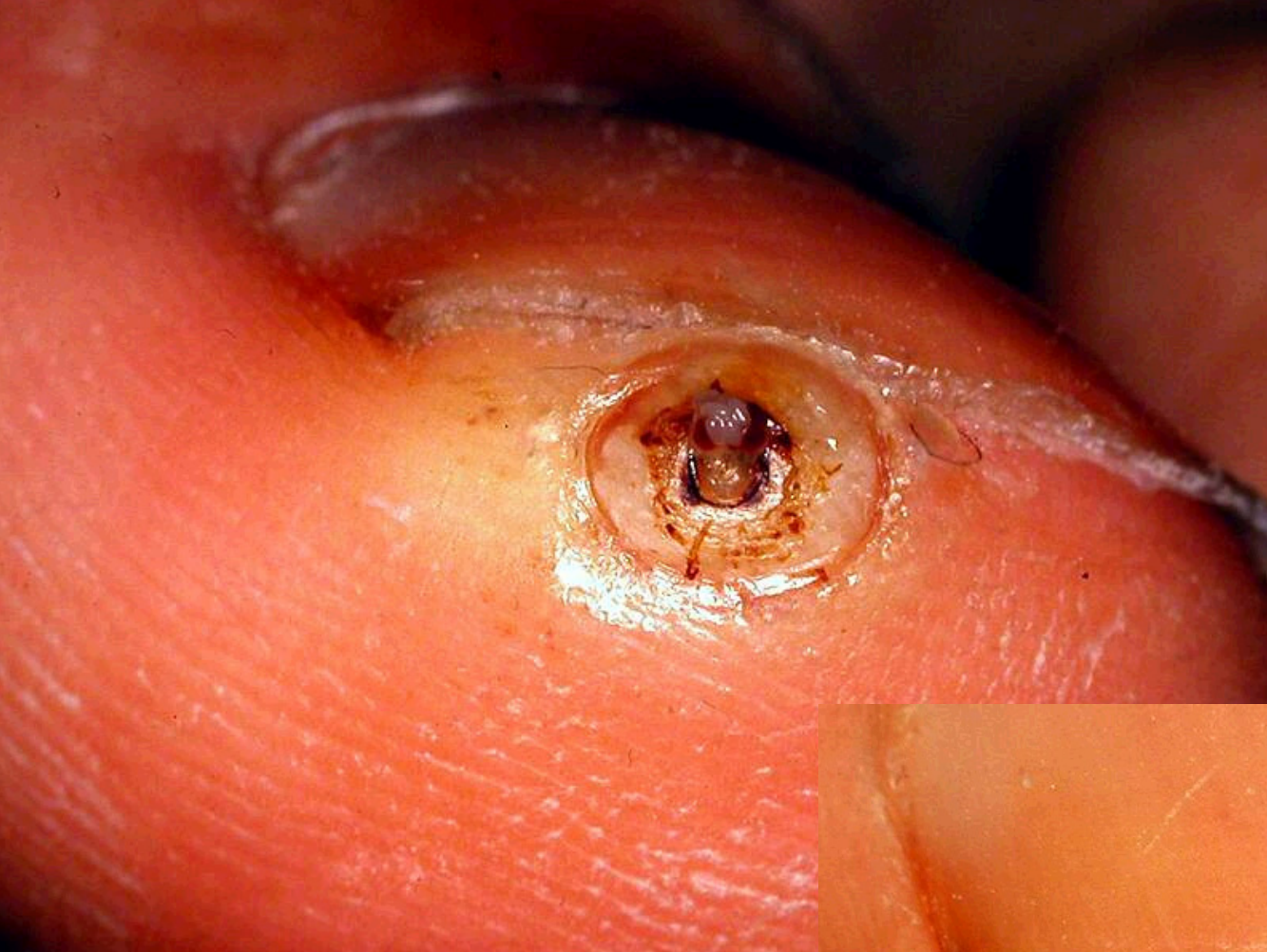





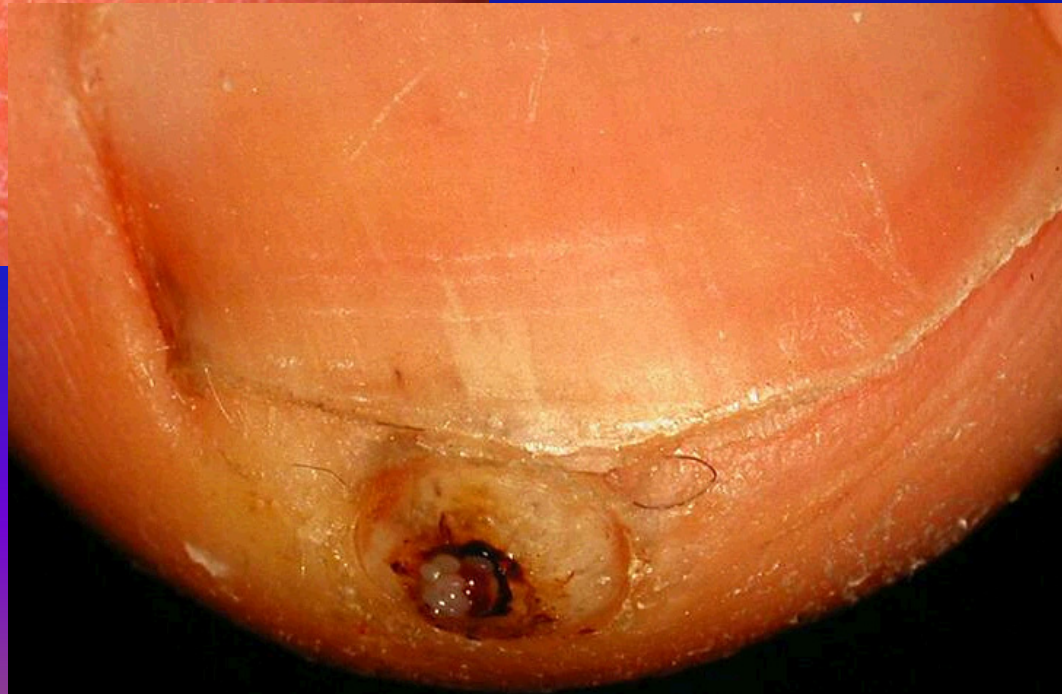


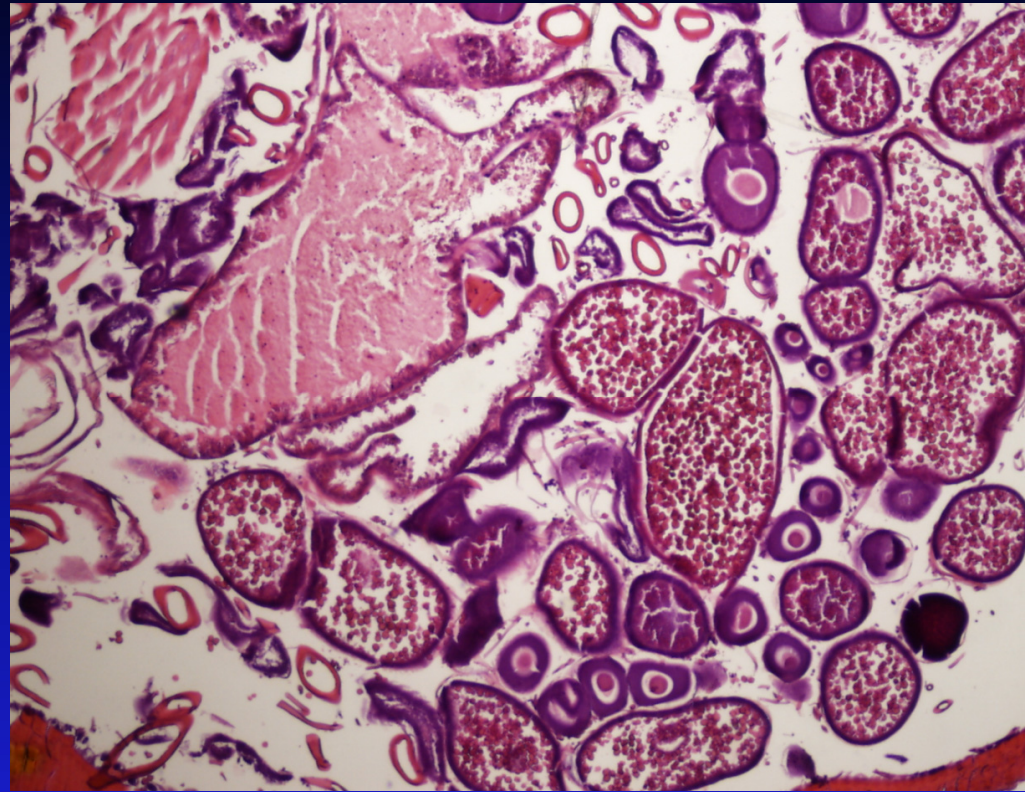
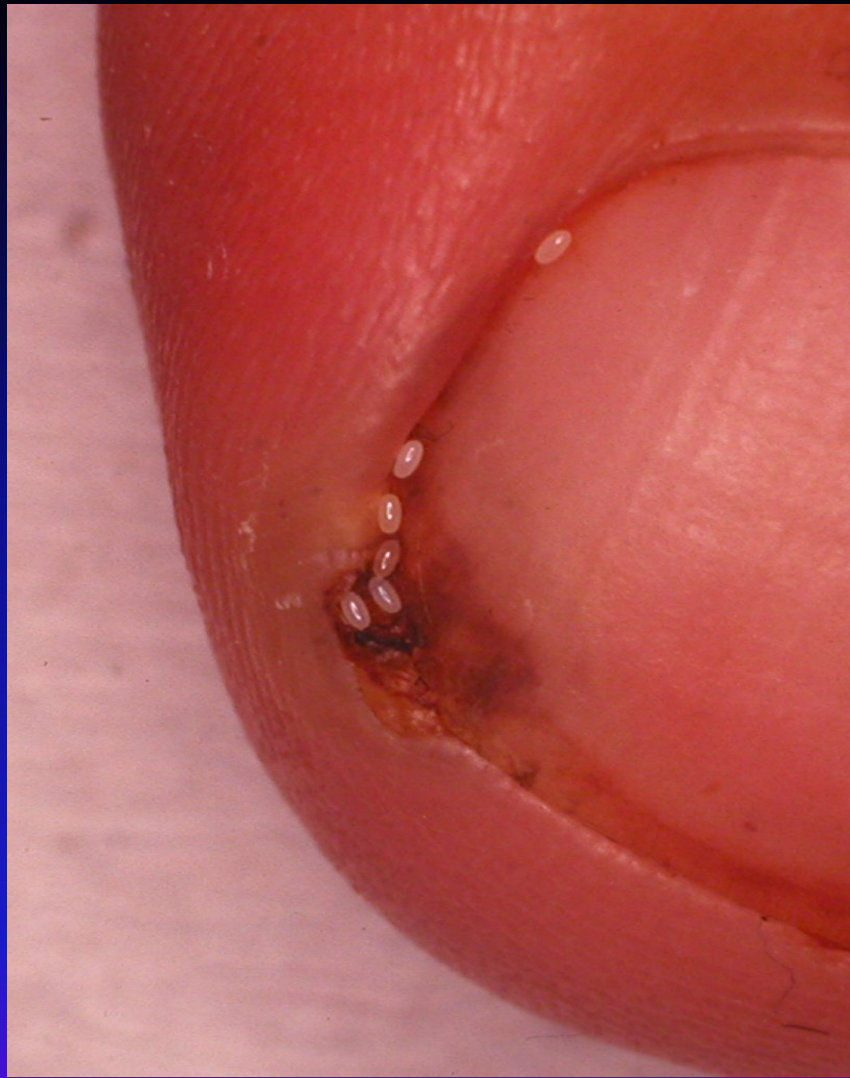***Schistosoma haematobium***



- Back from holidays..
- Left big toenail
- 31-year-old male



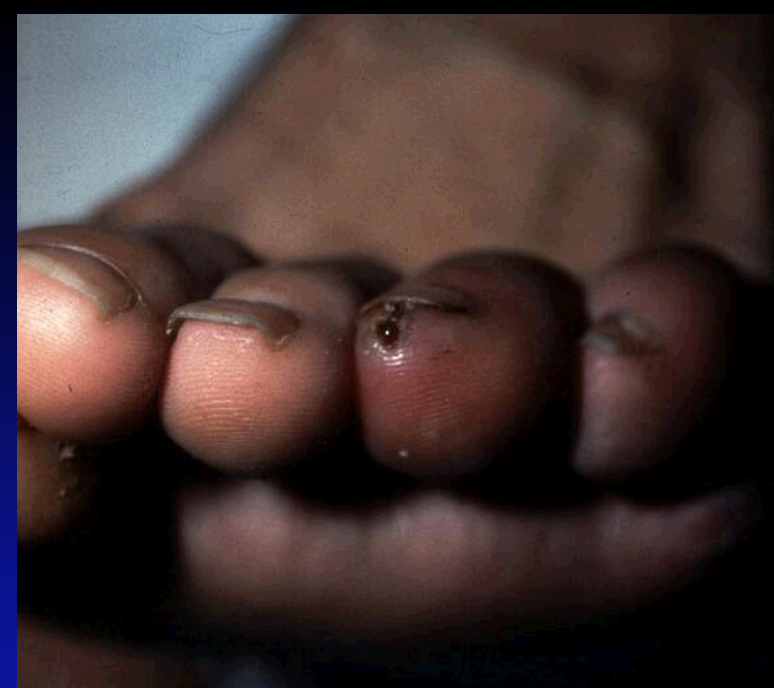



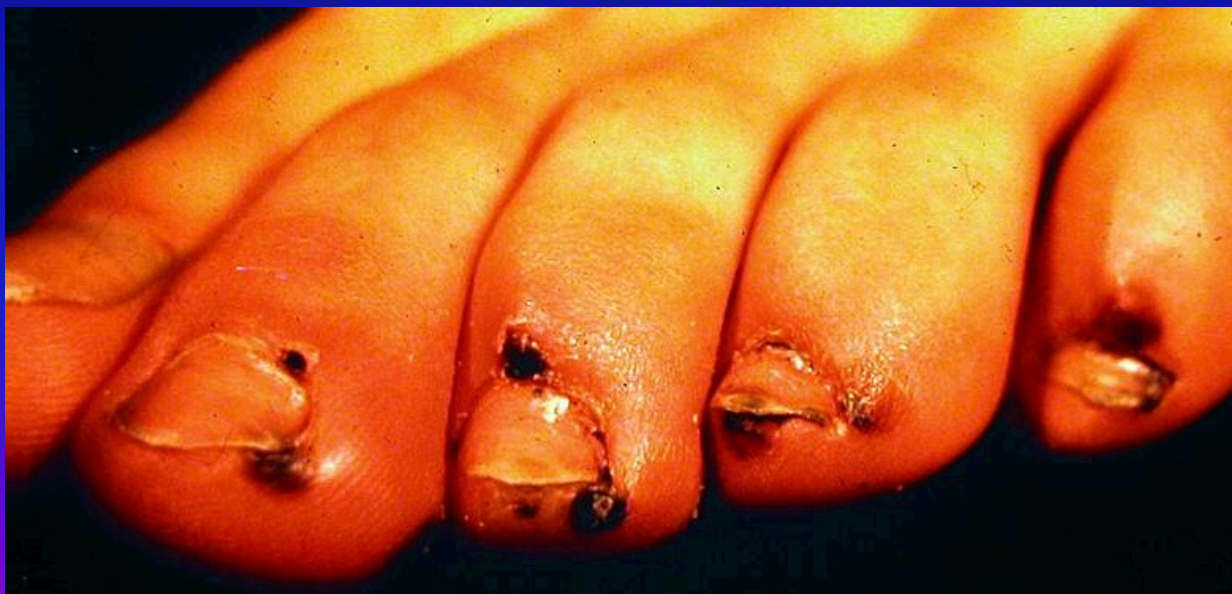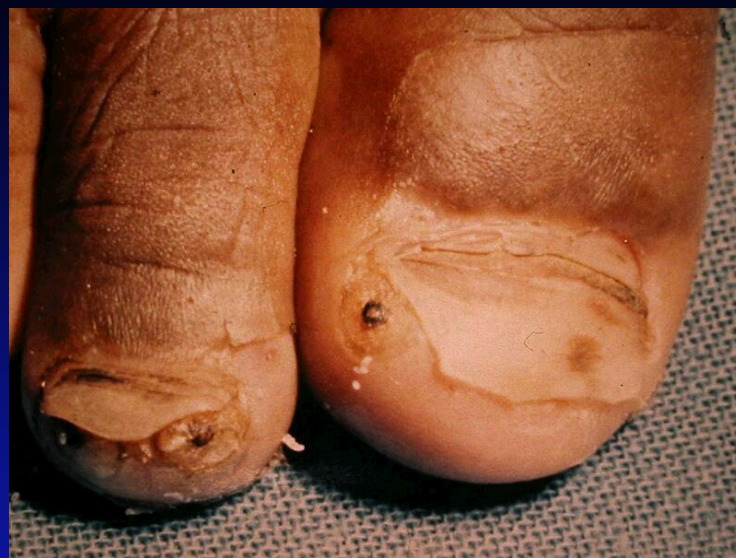↑ Coll. B. Richert

**Tungiasis (*Tunga penetrans*)**



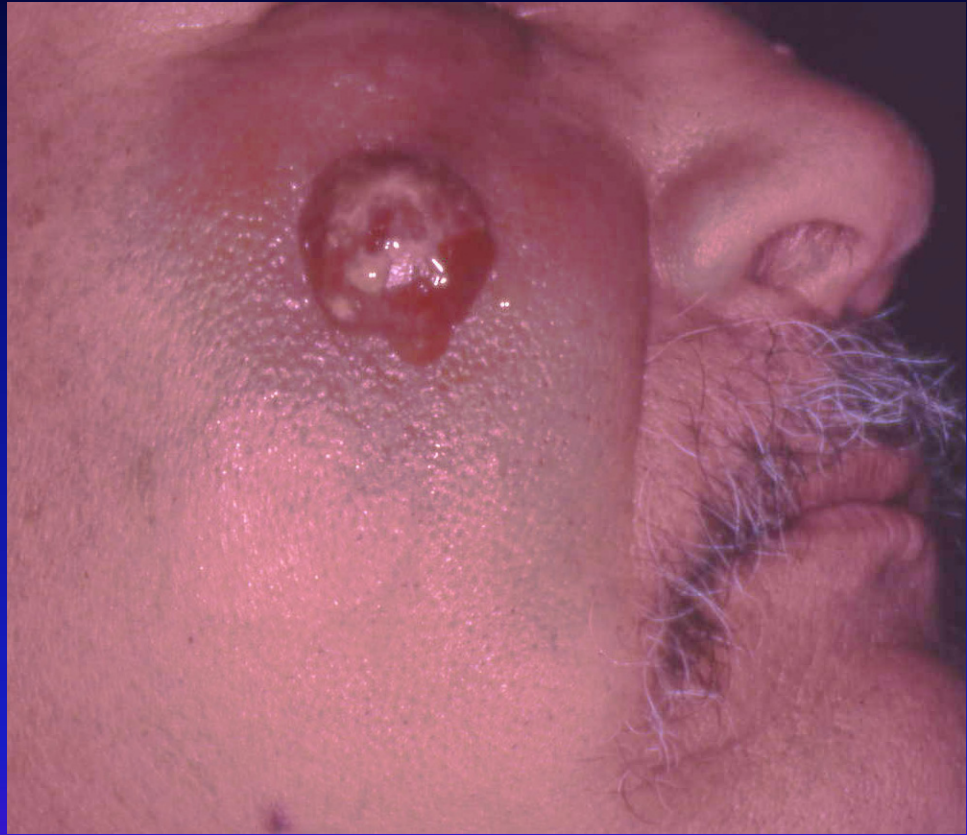


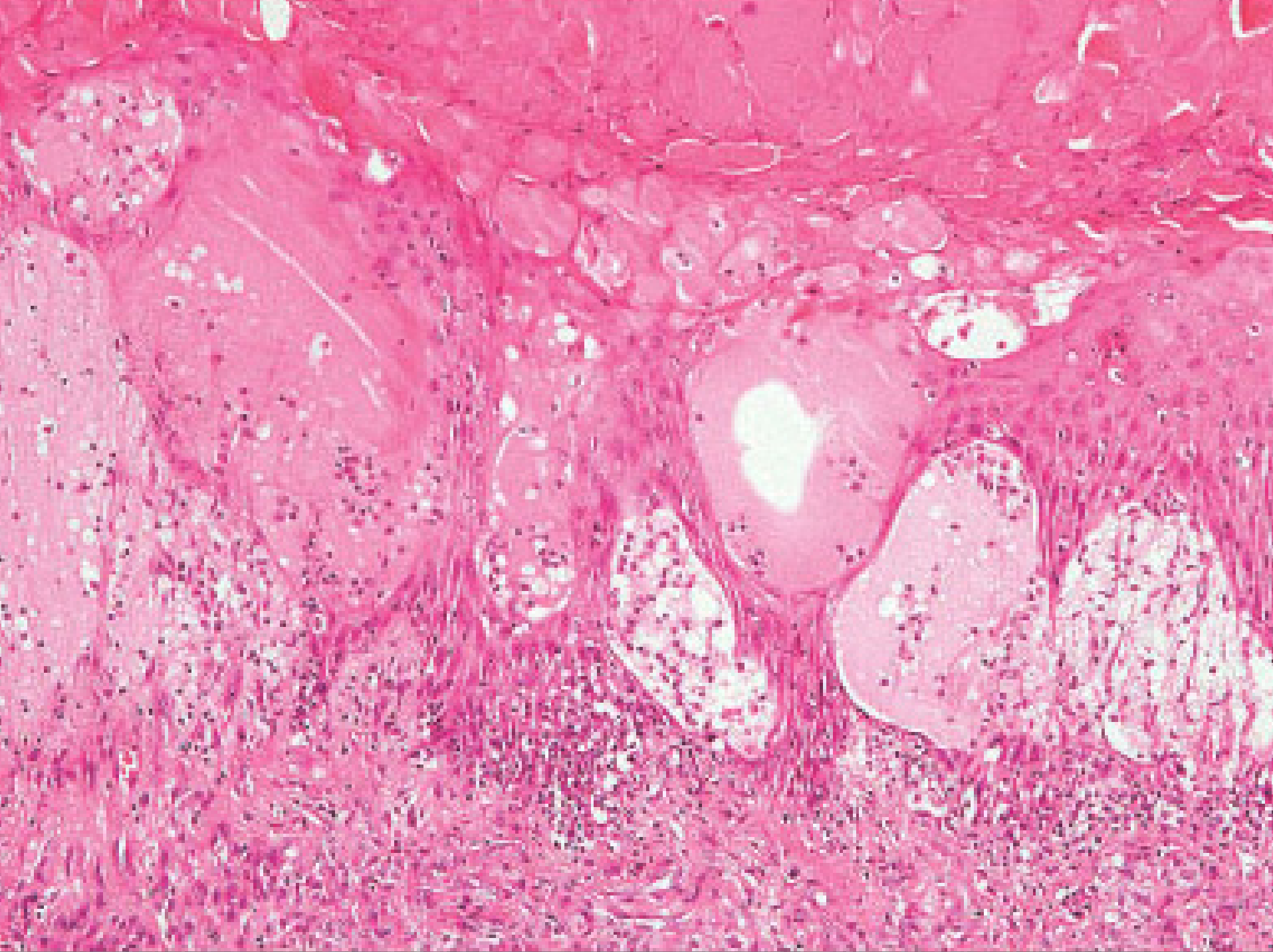
↑ Coll. D. de Berker, UK



↑ Coll. Prof Dupré, France

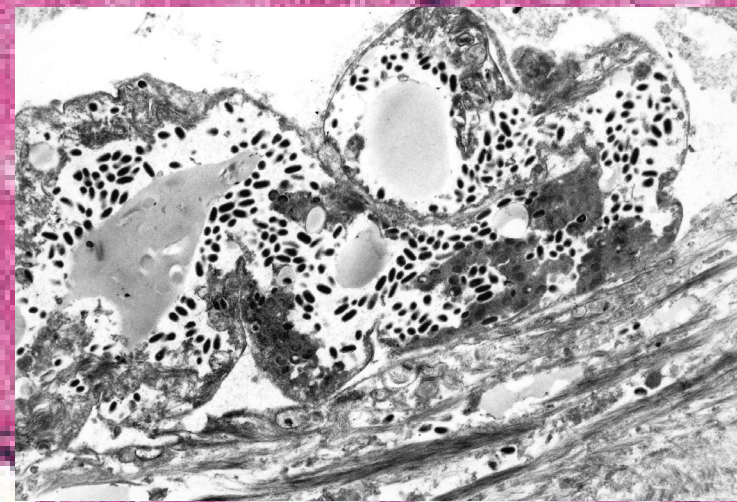
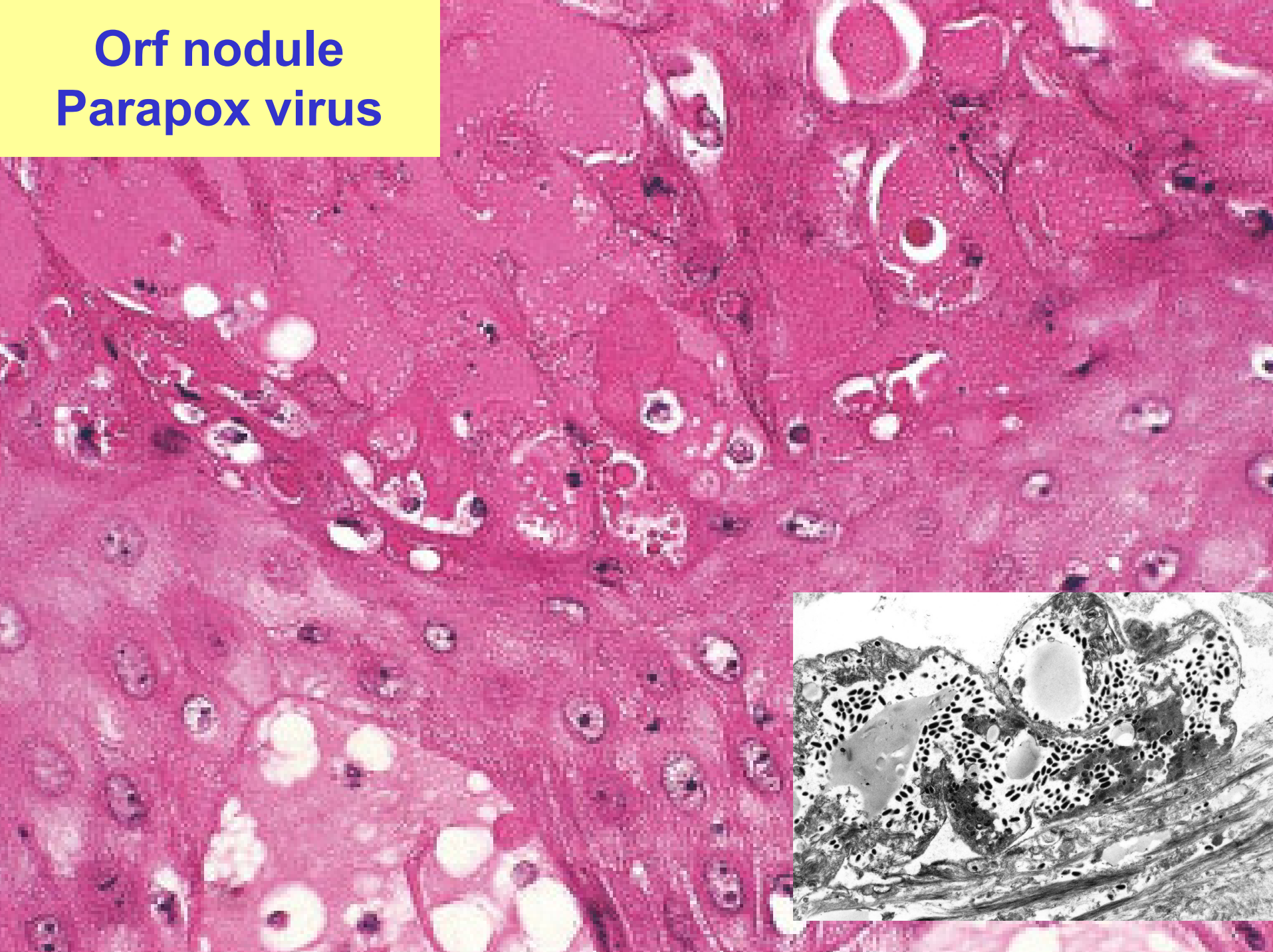
- 50-year-old man
- Nodular, oozing nodule on the right cheek evolving for 2 weeks

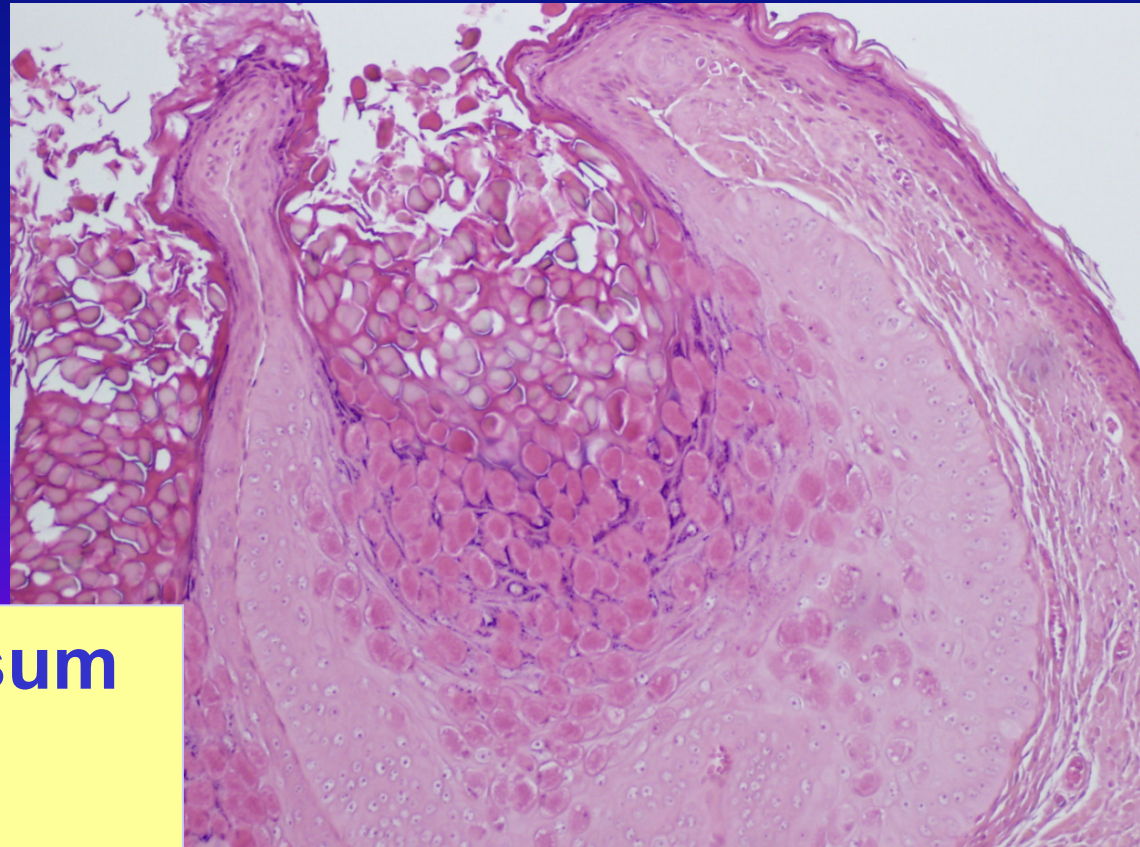
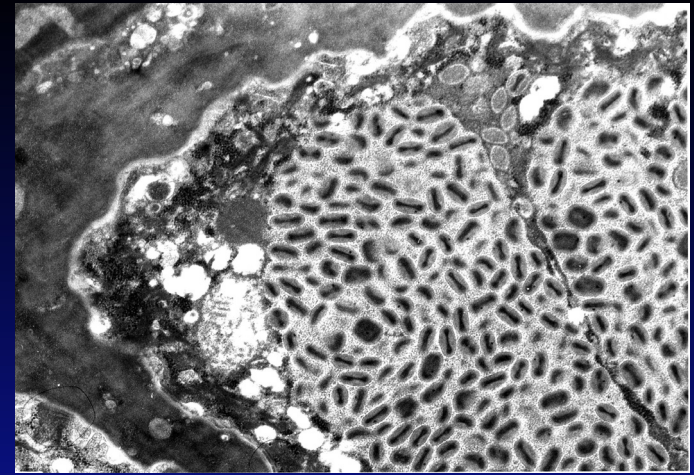
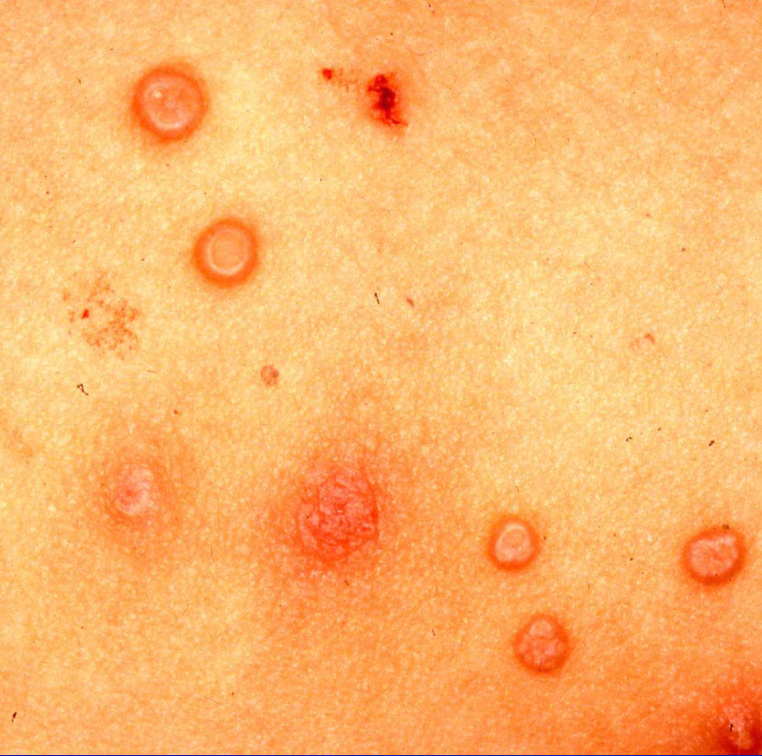





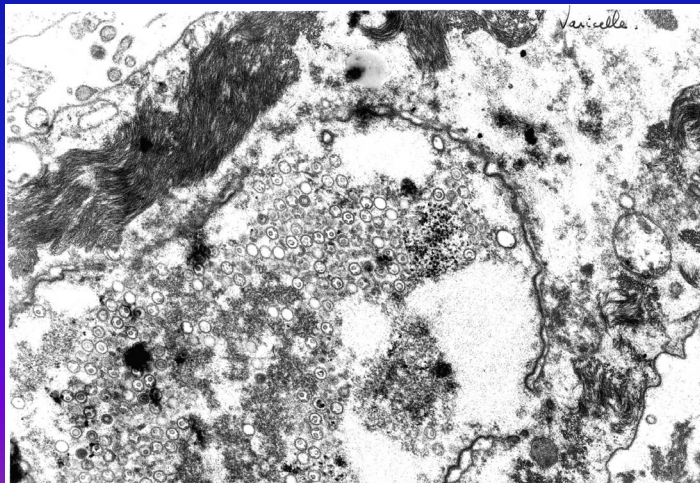
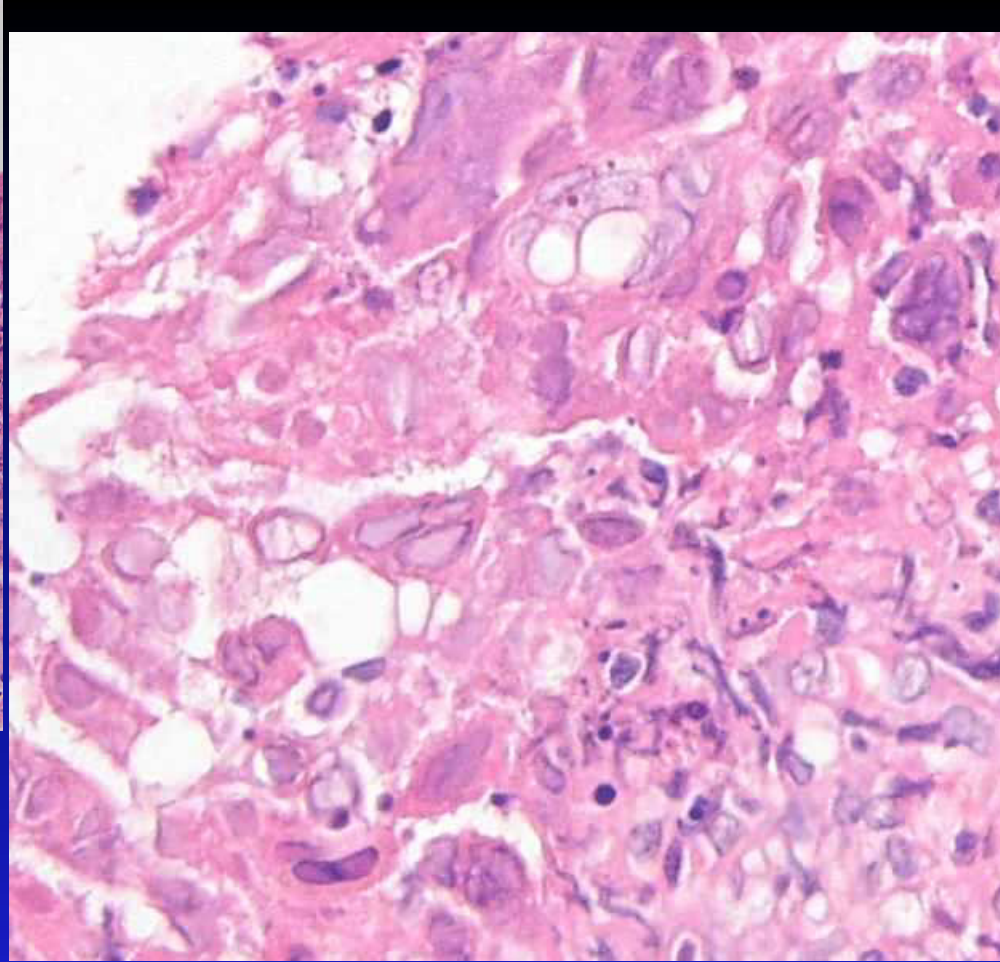
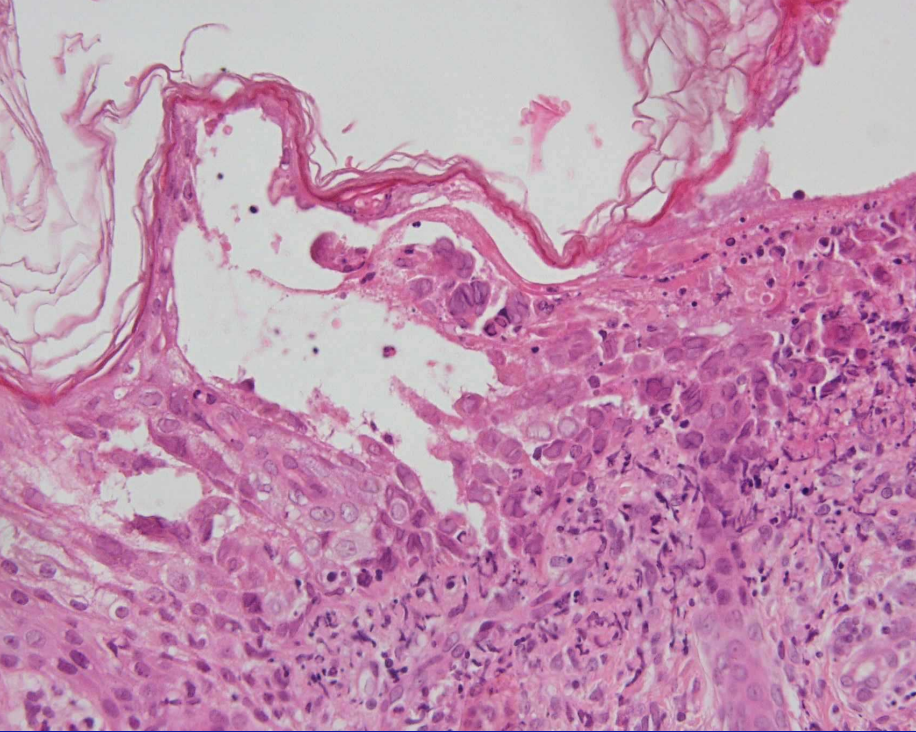
**Orf nodule**  
**Parapox virus**





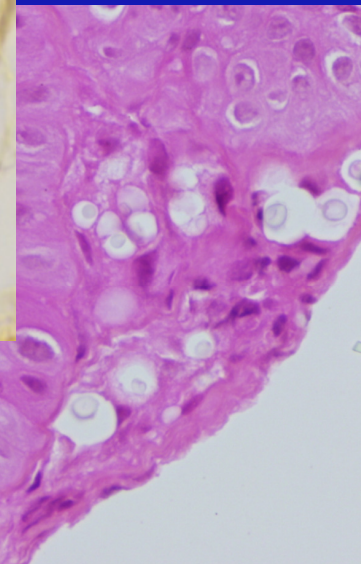
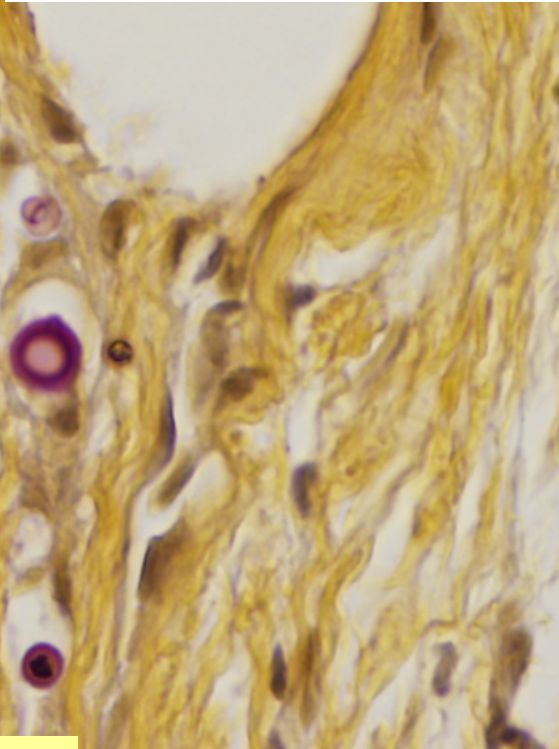
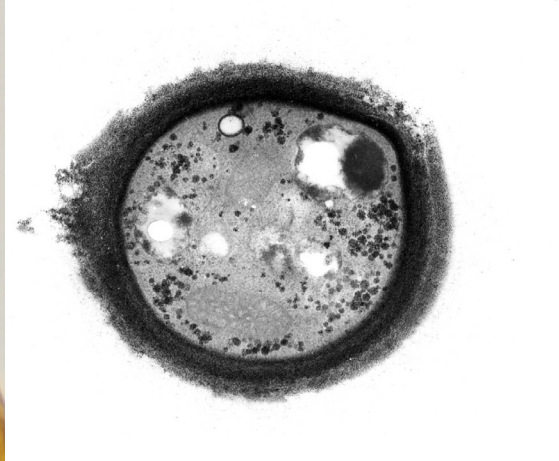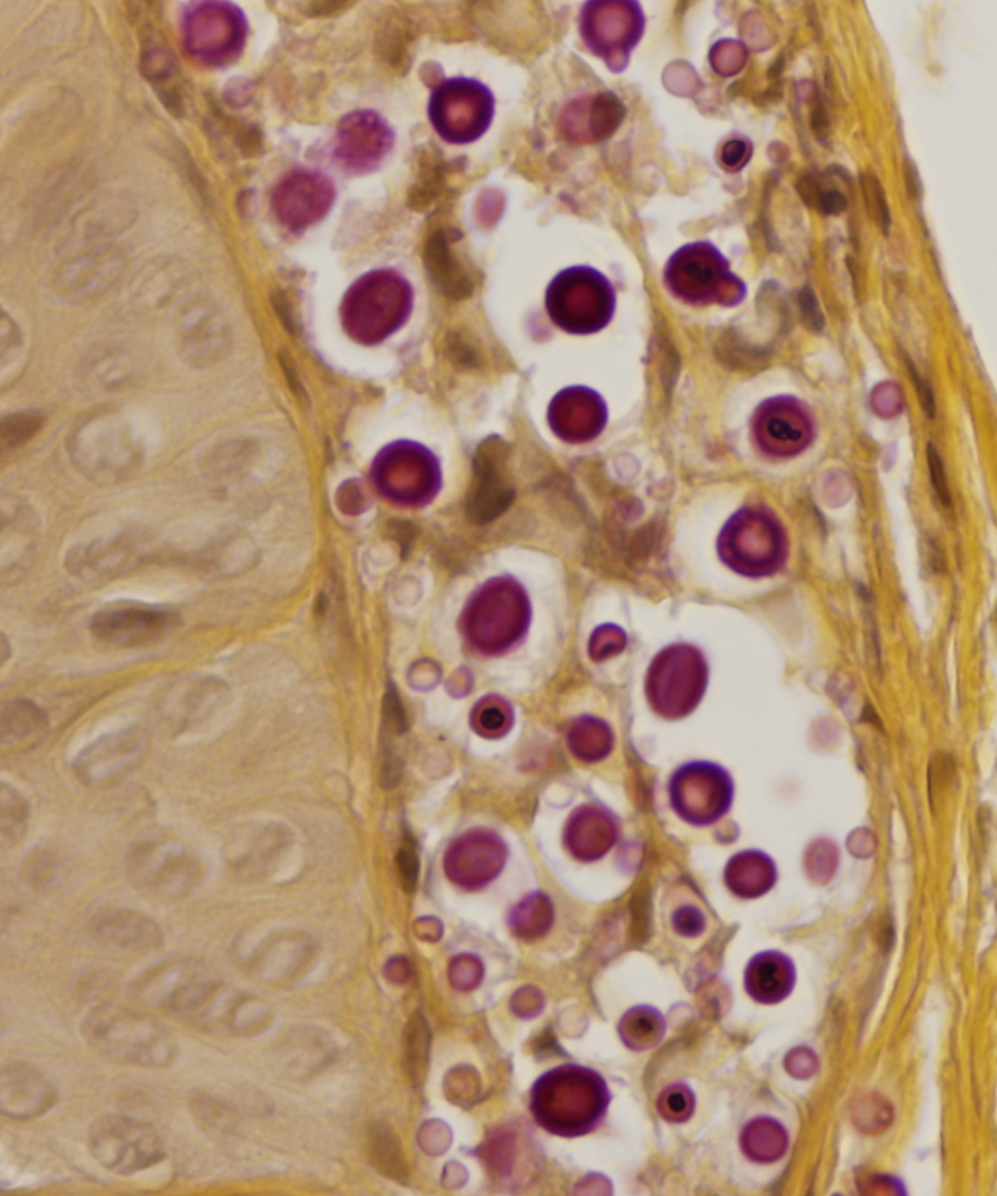
**Molluscum contagiosum**  
**Molluscipox virus**



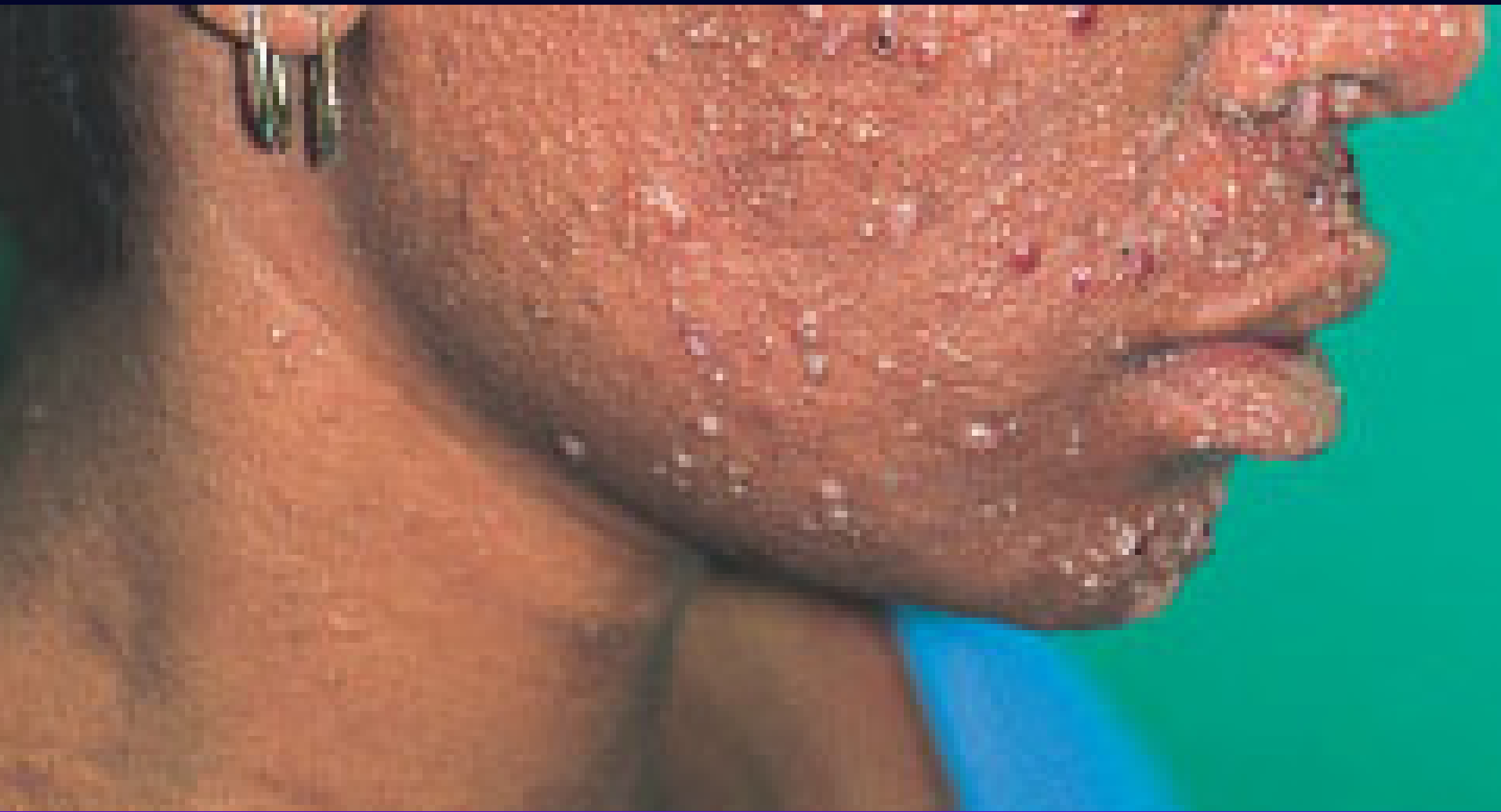

HZV



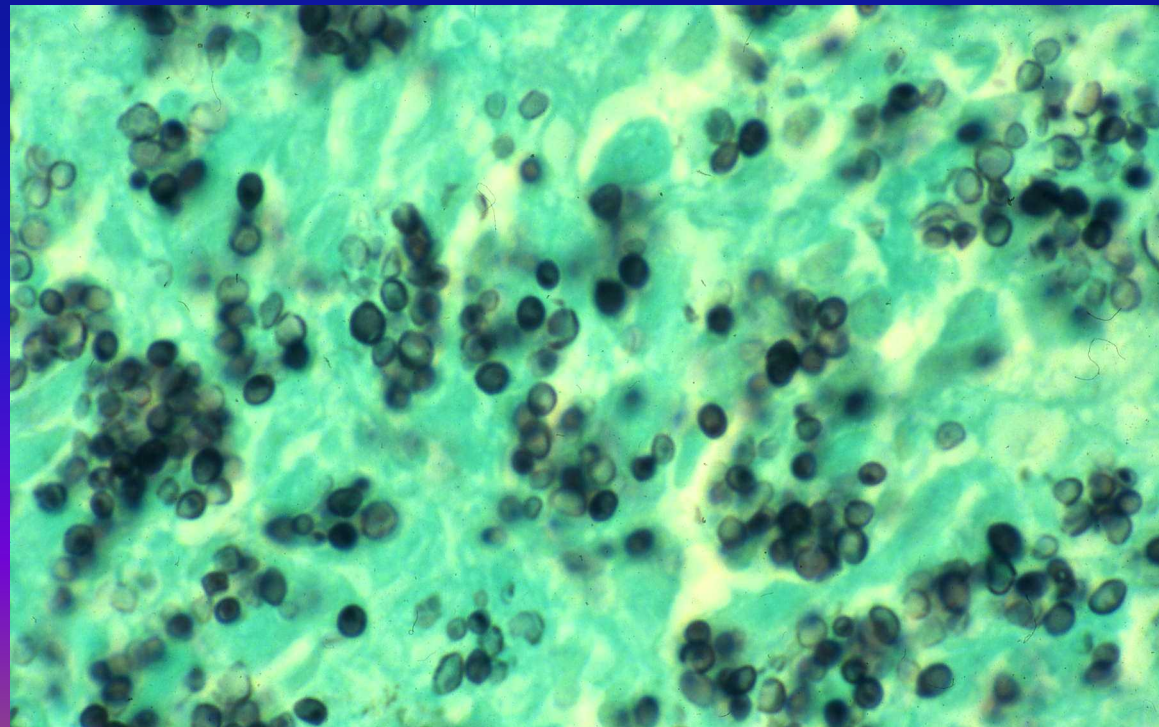
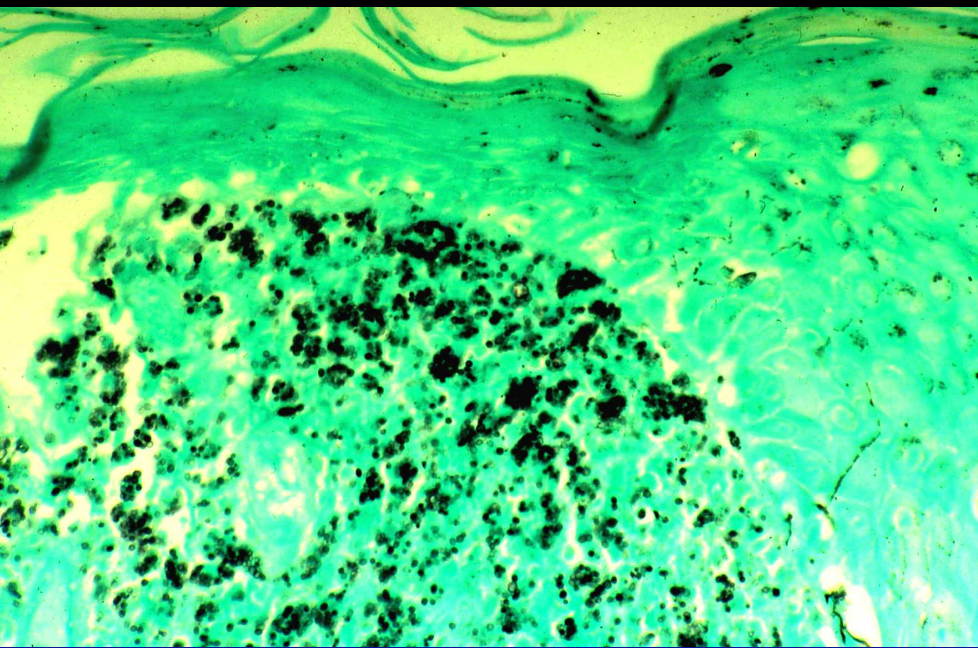


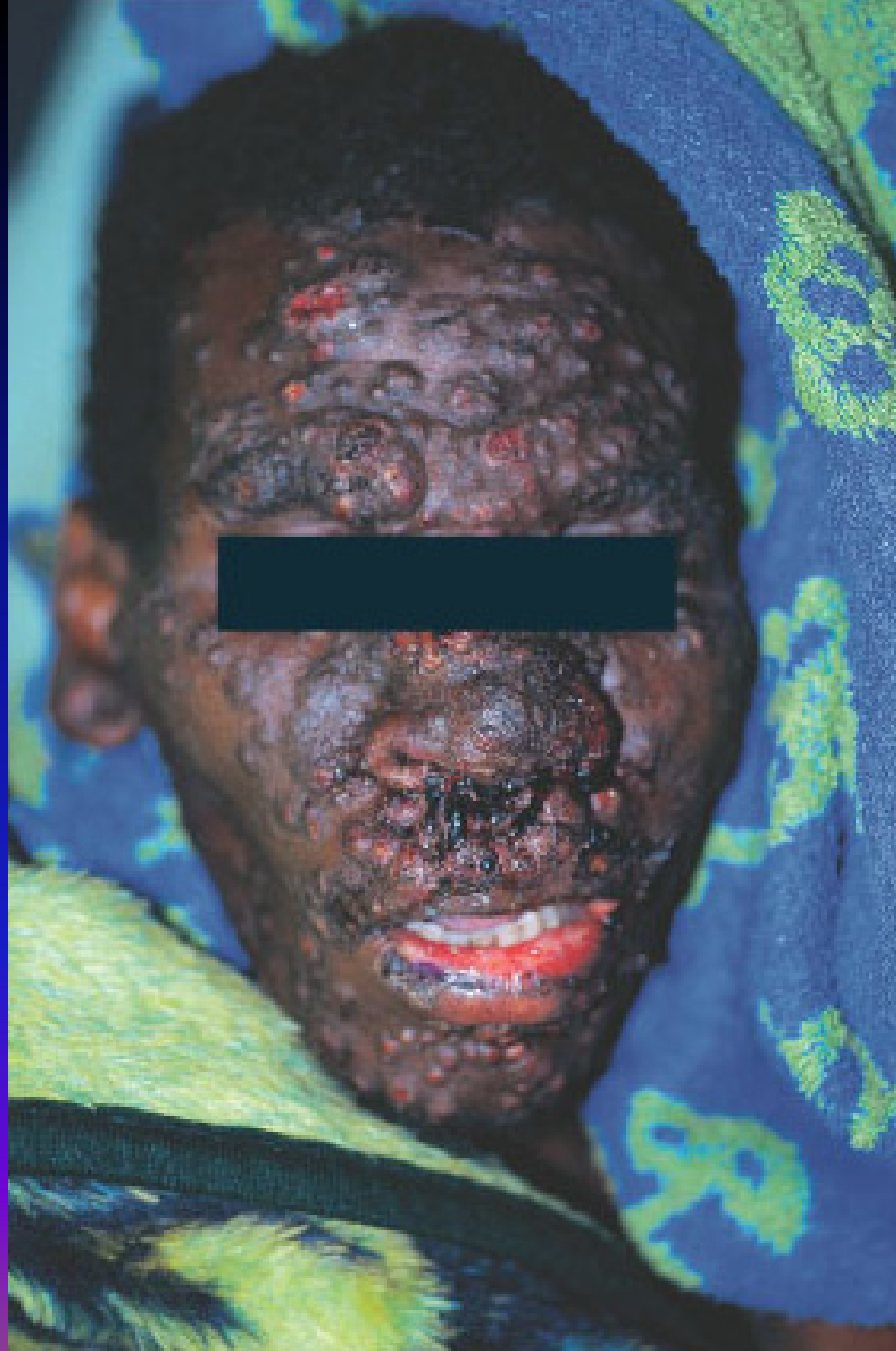*Cryptococcus neoformans*



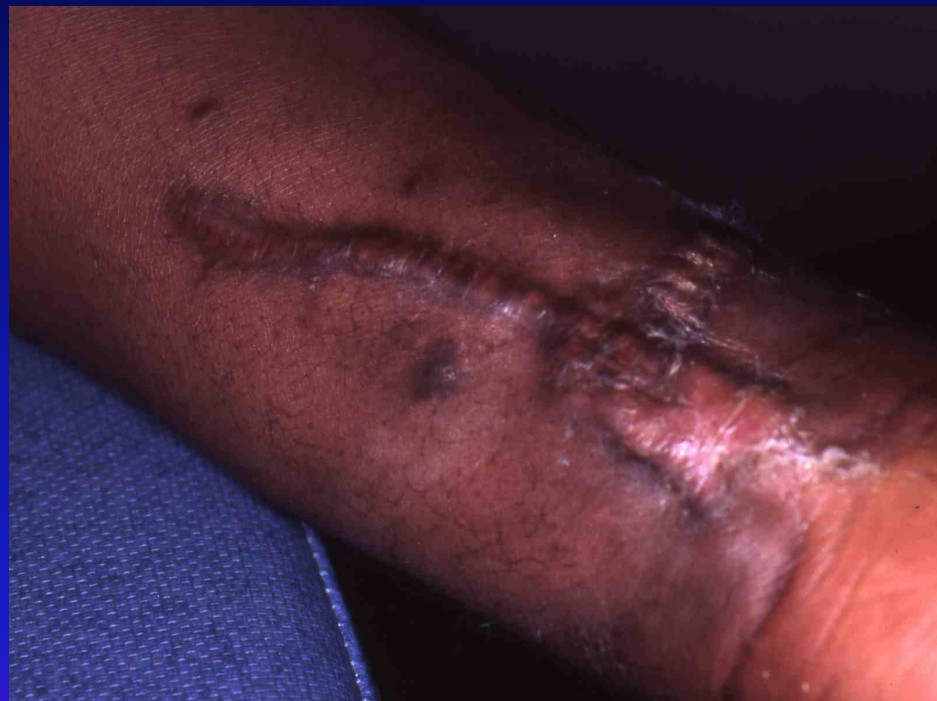

# *Histoplasma*

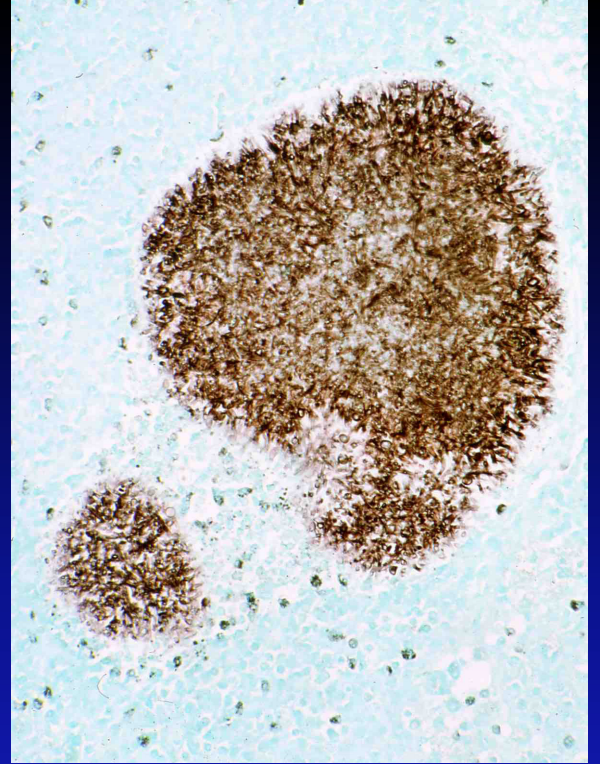
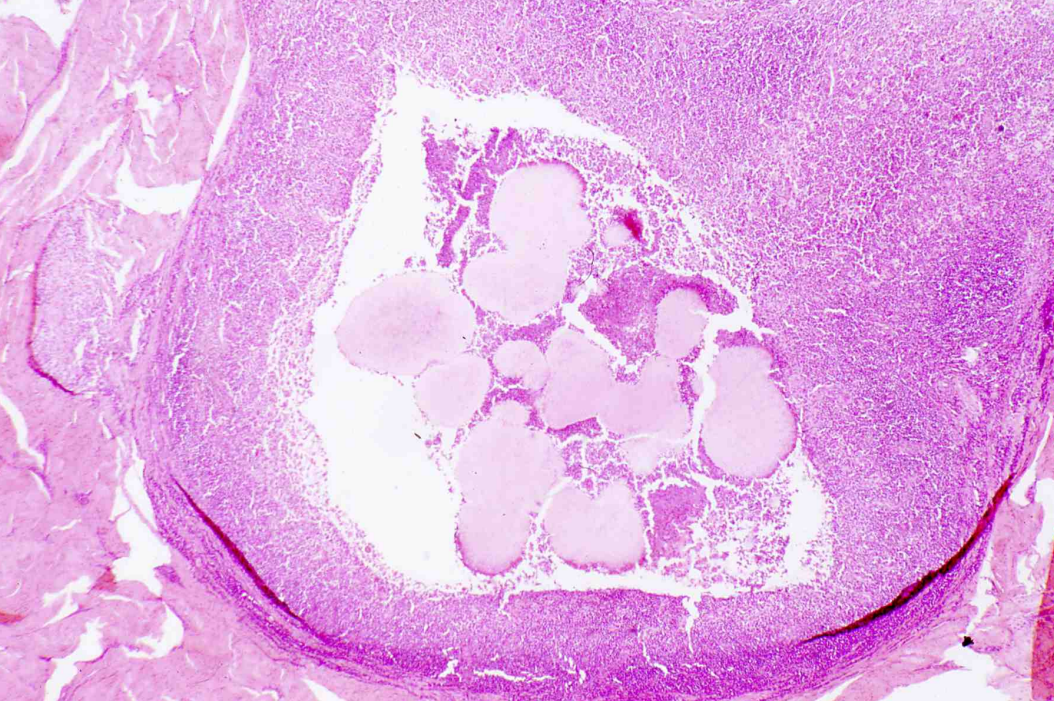




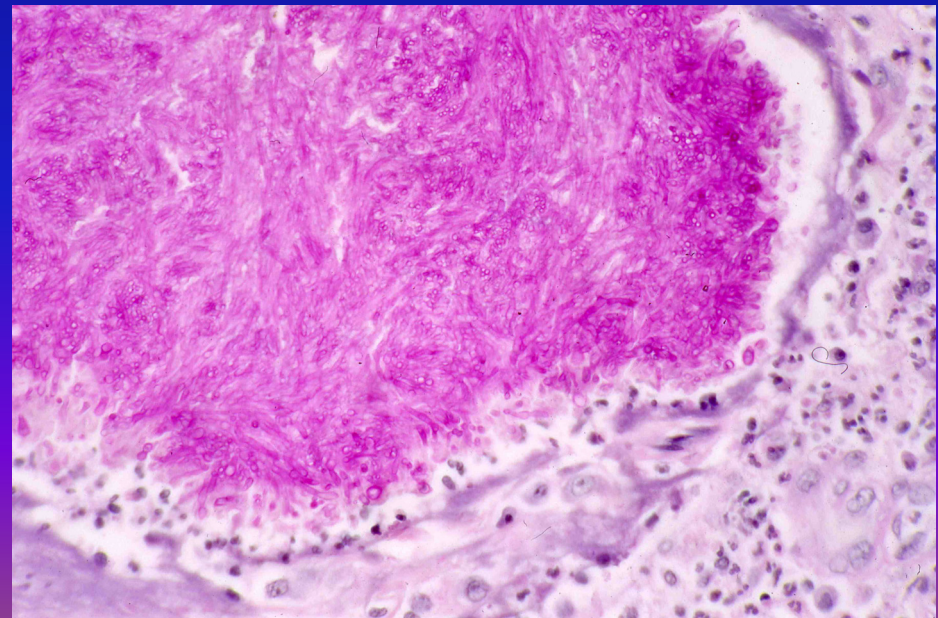
- 43-year-old Black African male
- Hypertrophic scar with 2 subcutaneous nodules and wrist swelling
- Clinical diagnosis
  - Keloid ?
  - Sarcoidosis ?



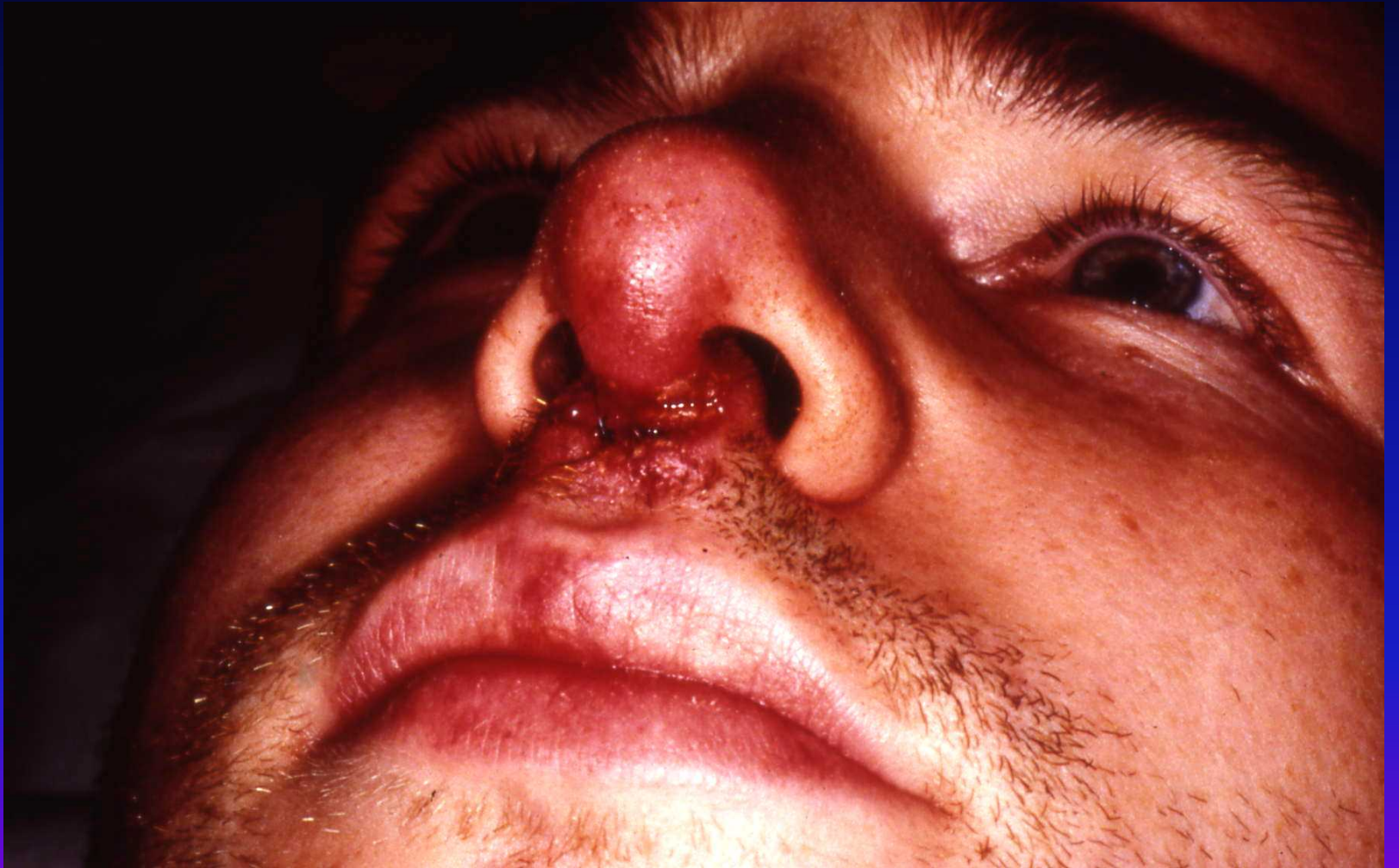

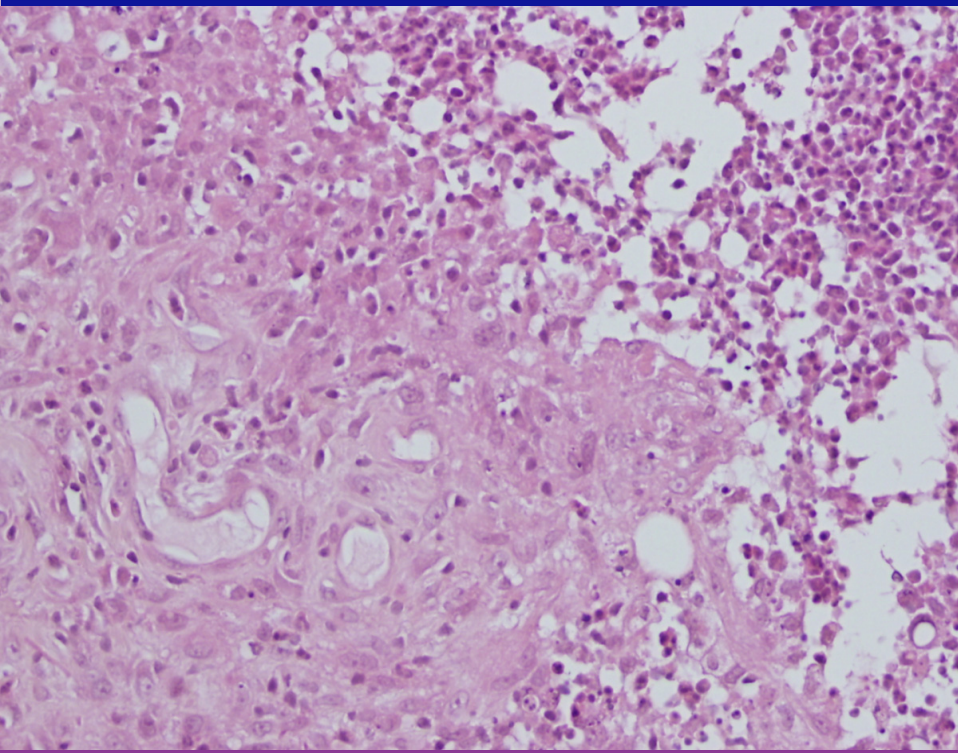
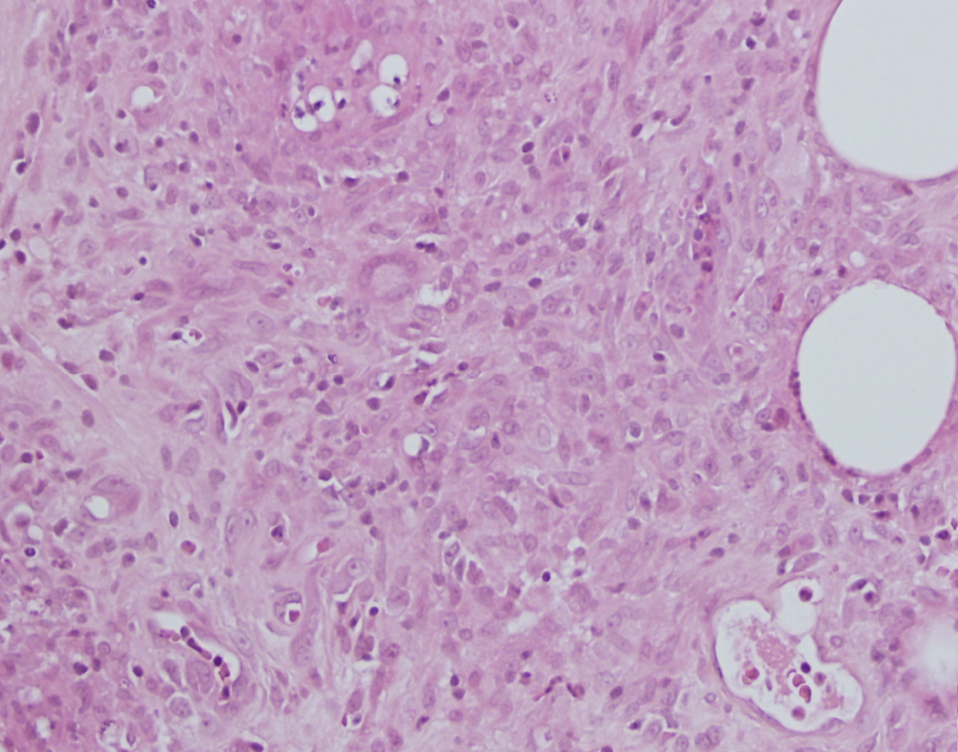


***Fusarium solani***



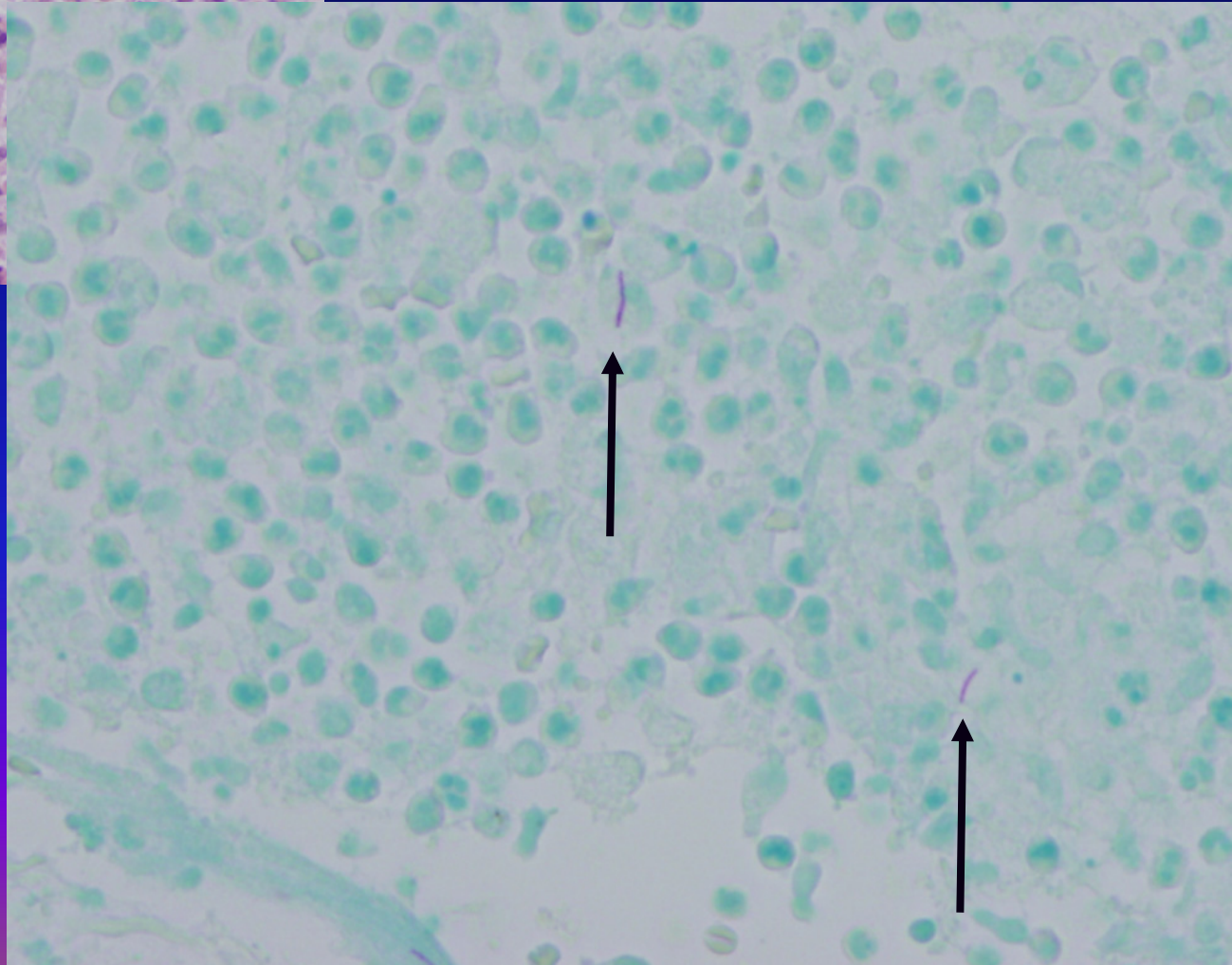
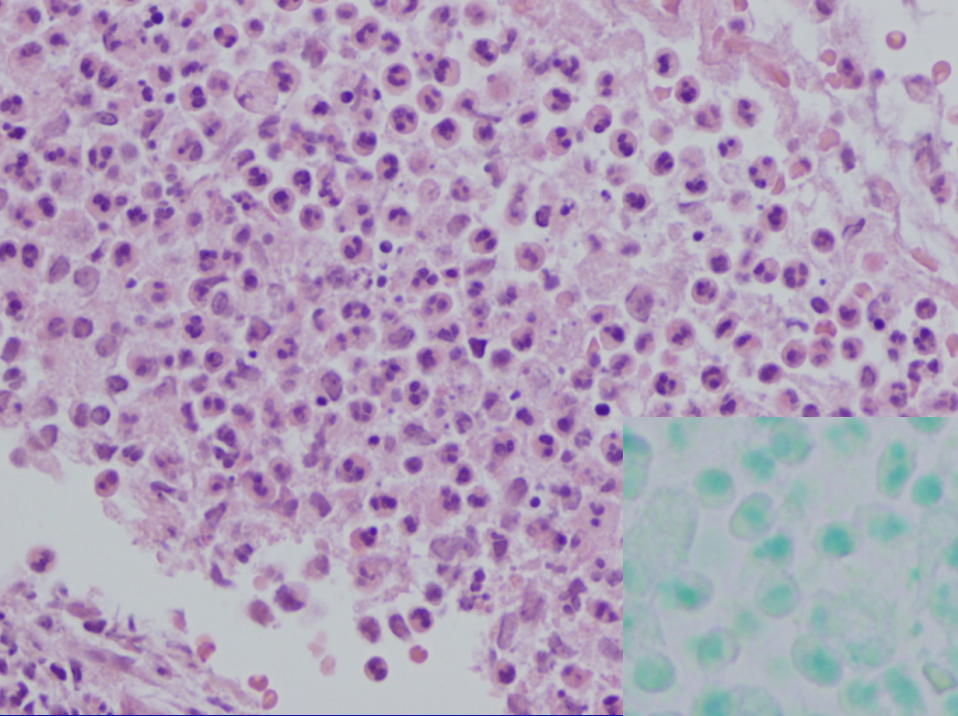




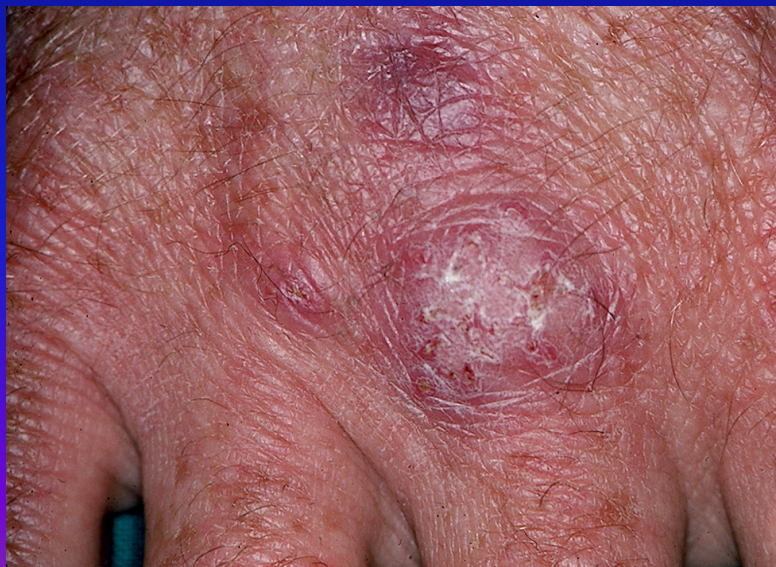
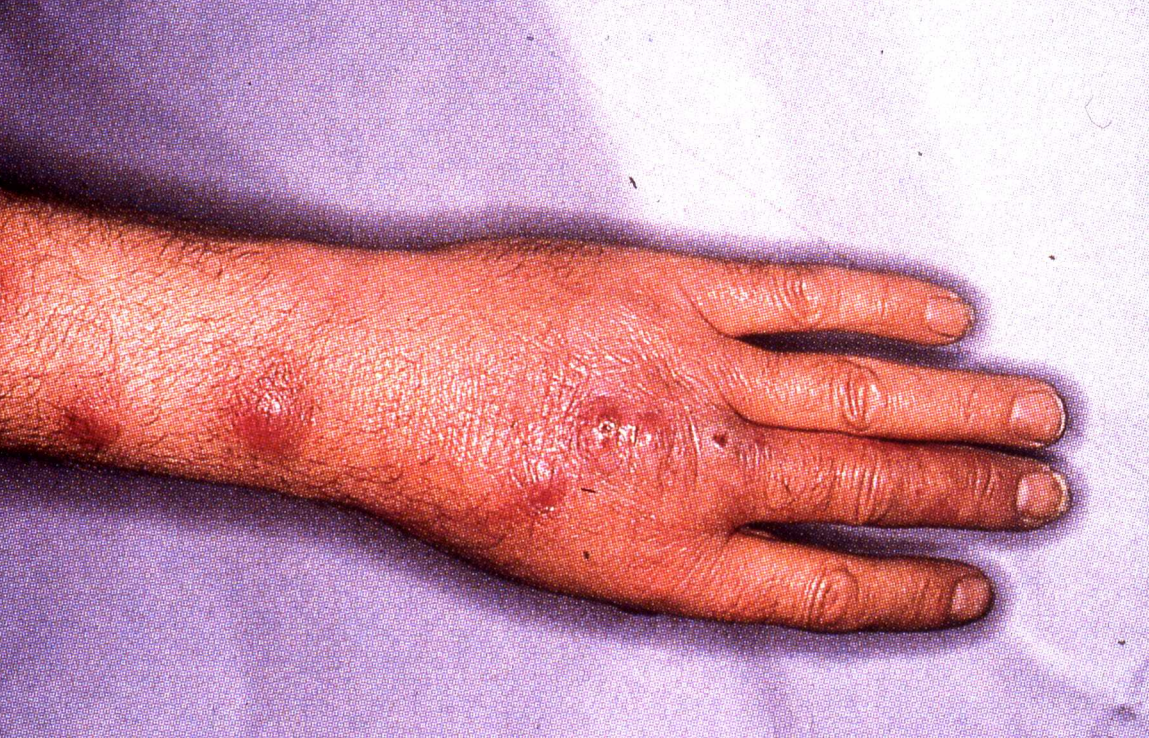


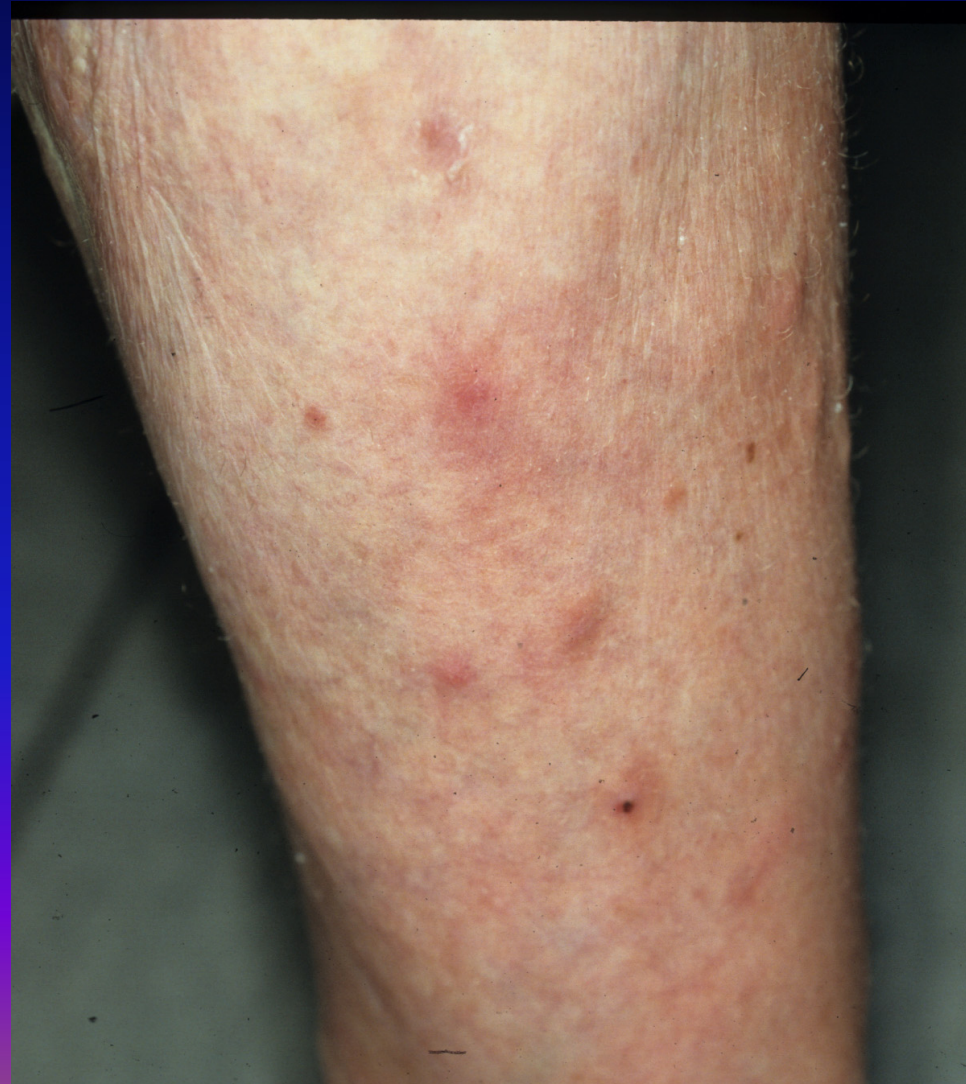
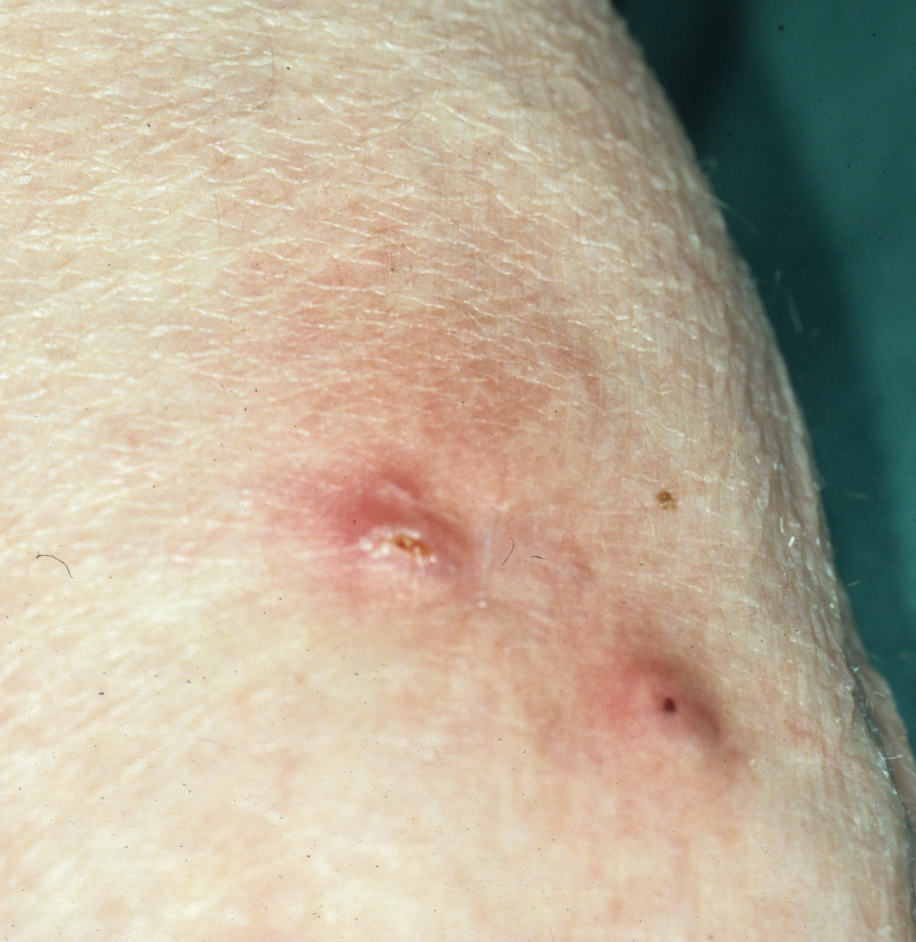*Mycobacterium marinum*





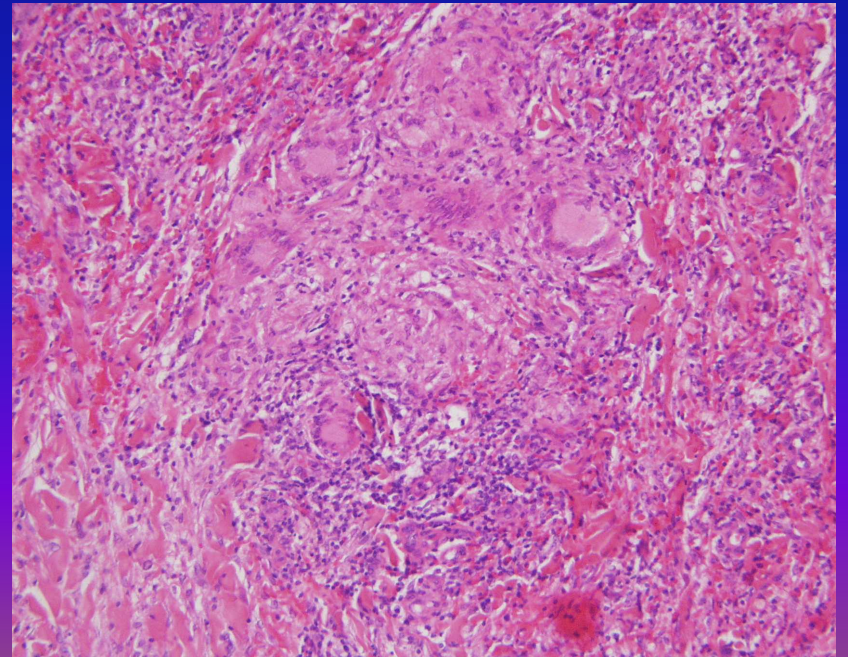
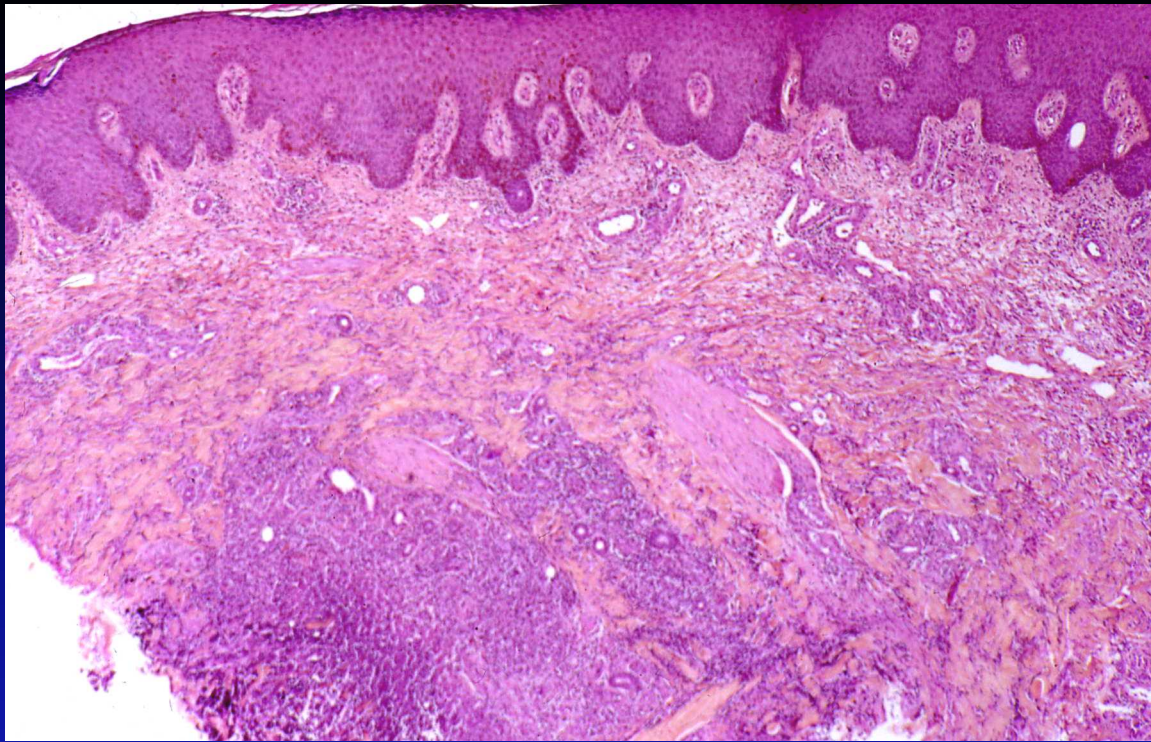






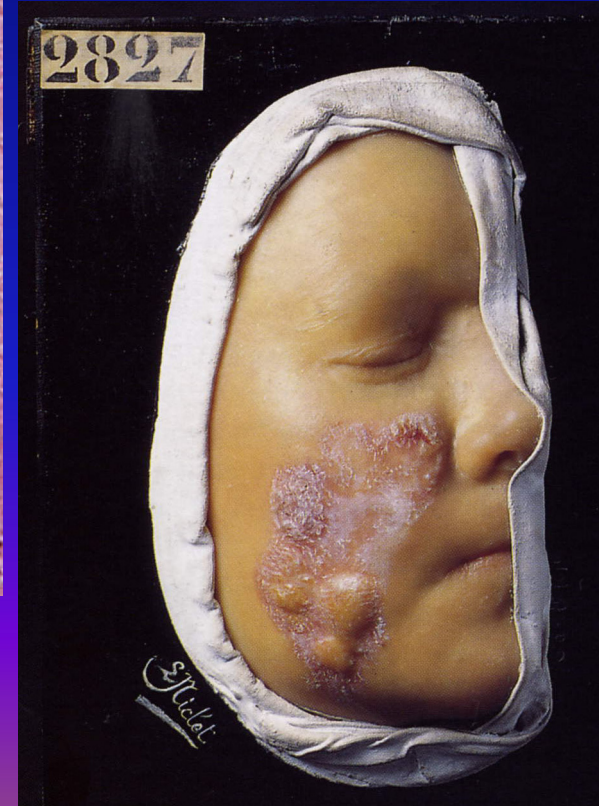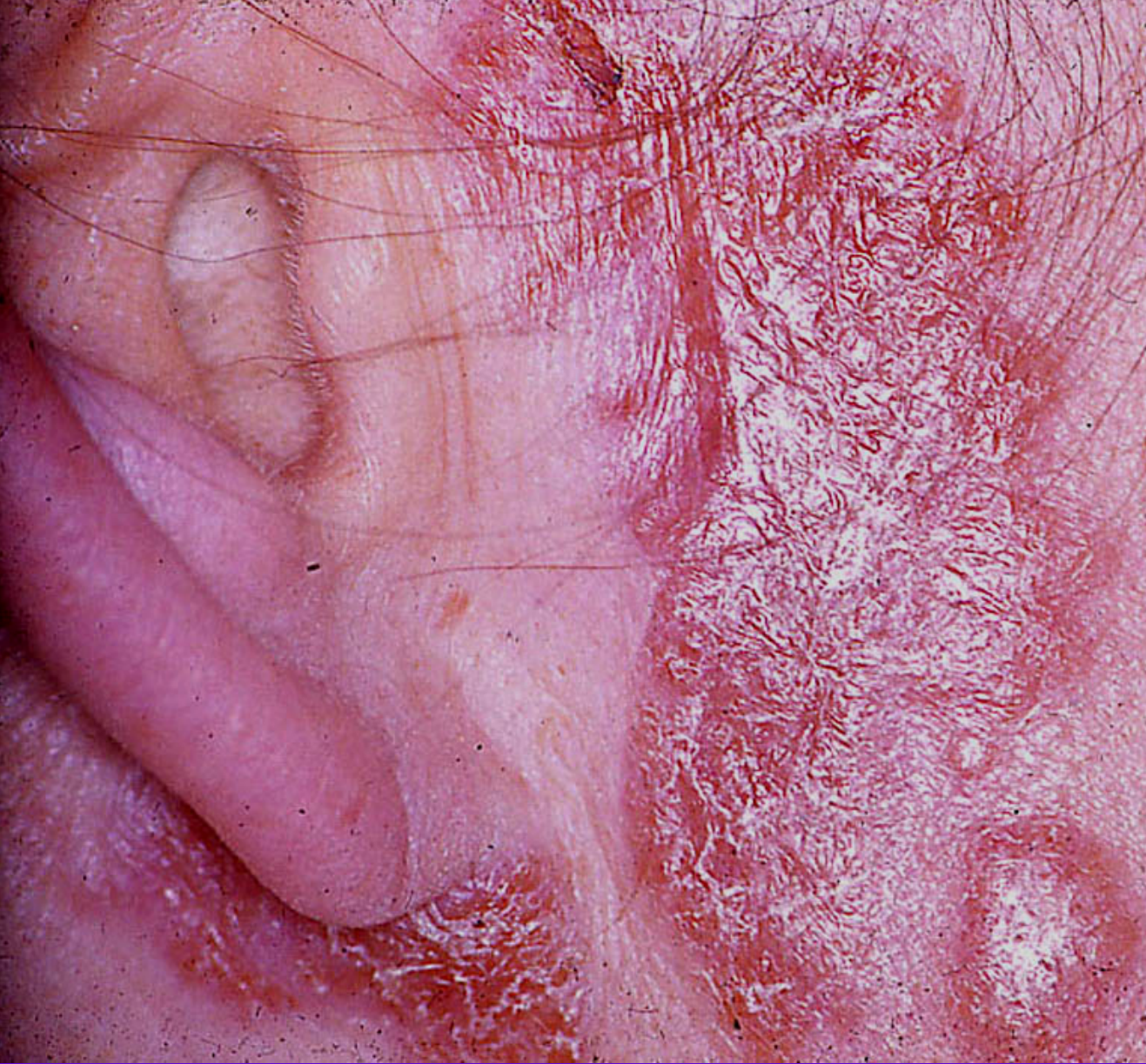↑ Coll. M. de la Brassinne





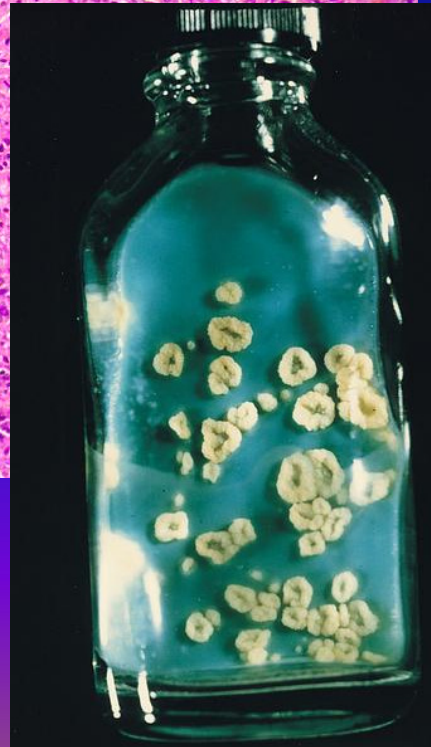
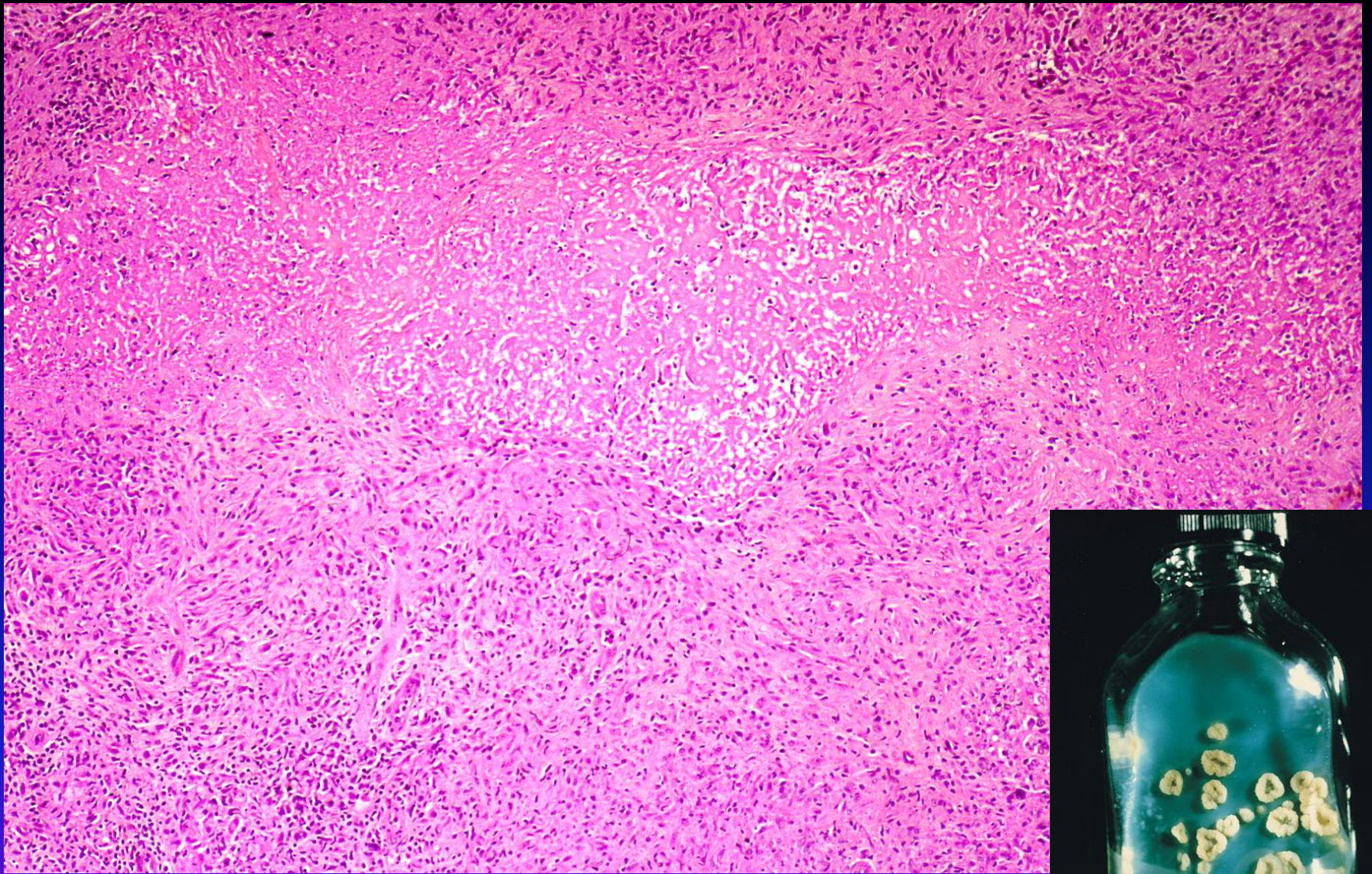
***Mycobacterium chelonae***





↑ Coll. B. Cribier, France

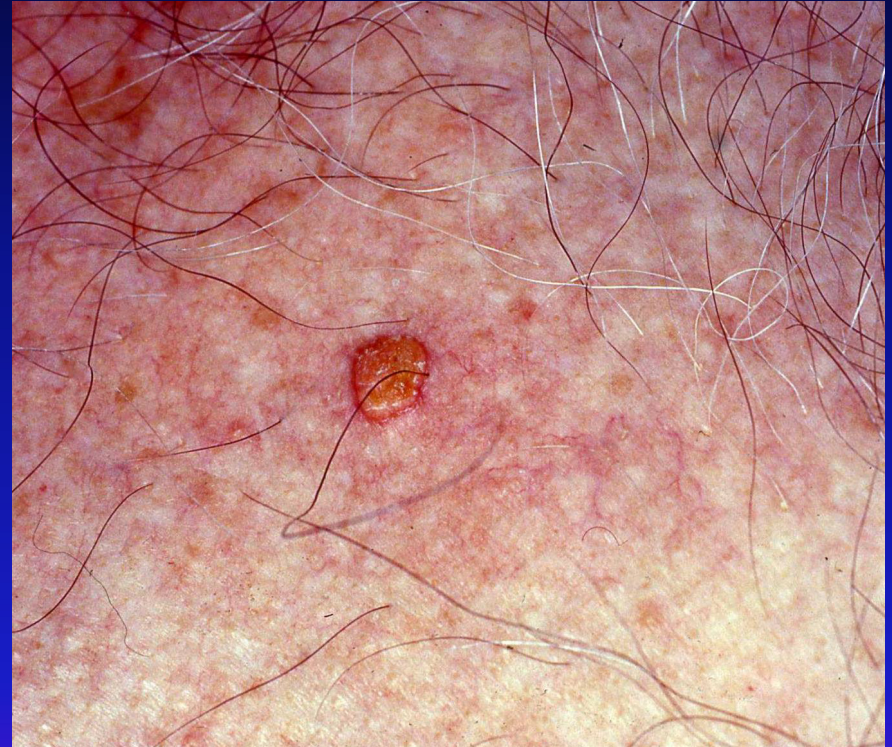



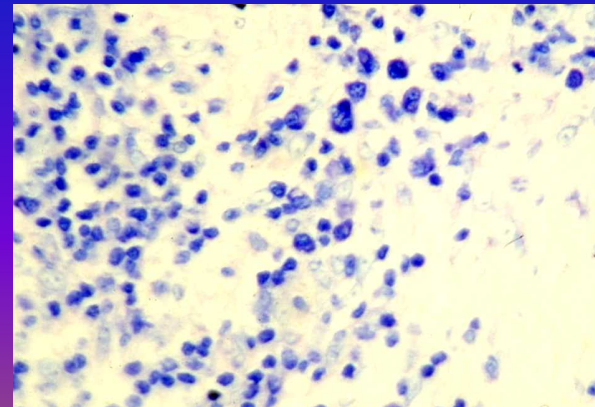
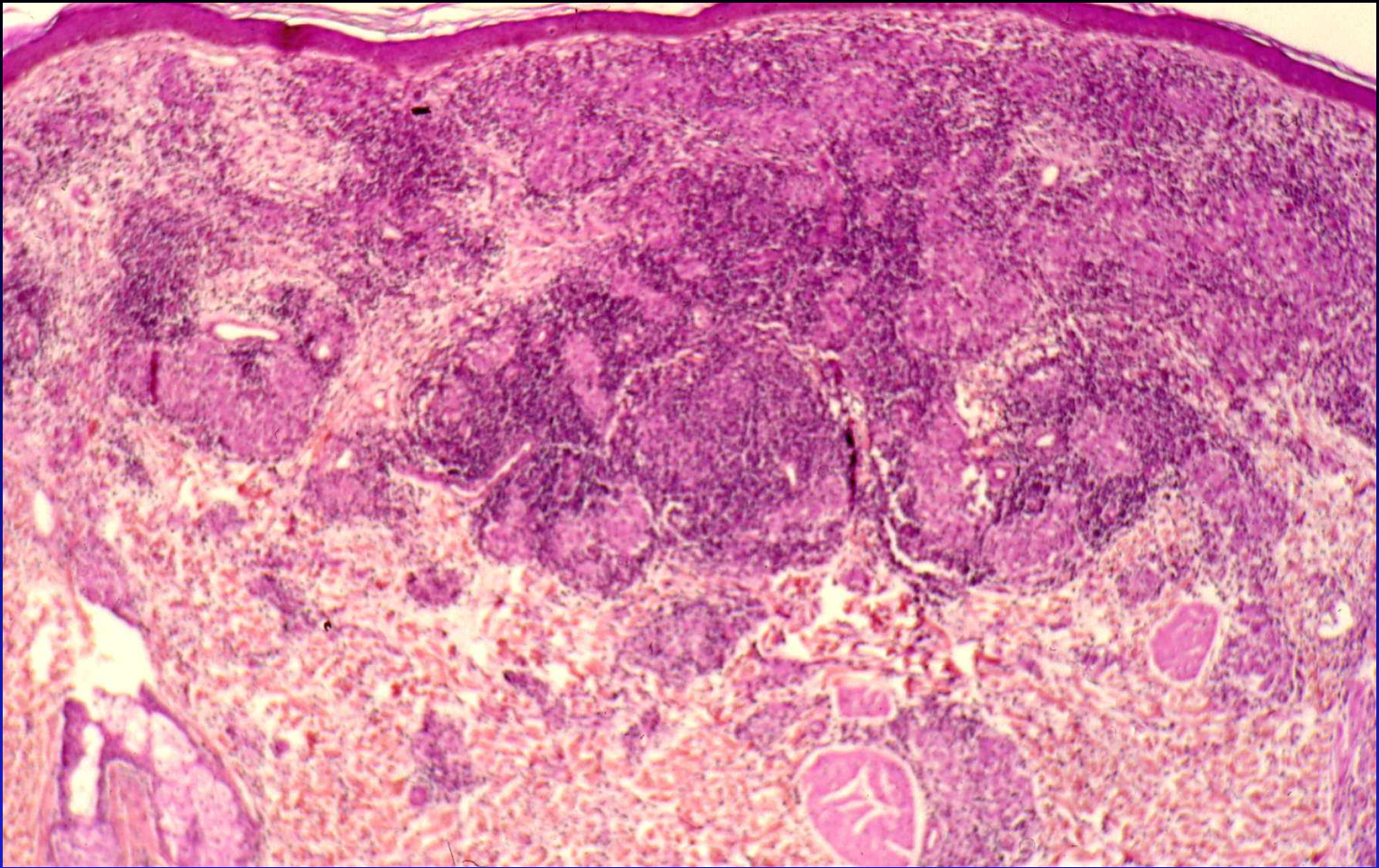
***Mycobacterium tuberculosis***



- 66-year-old patient
- Retired professor of medicine
- Back from holidays in the Nice area
- Some erythematous and yellowish nodules located on the trunk

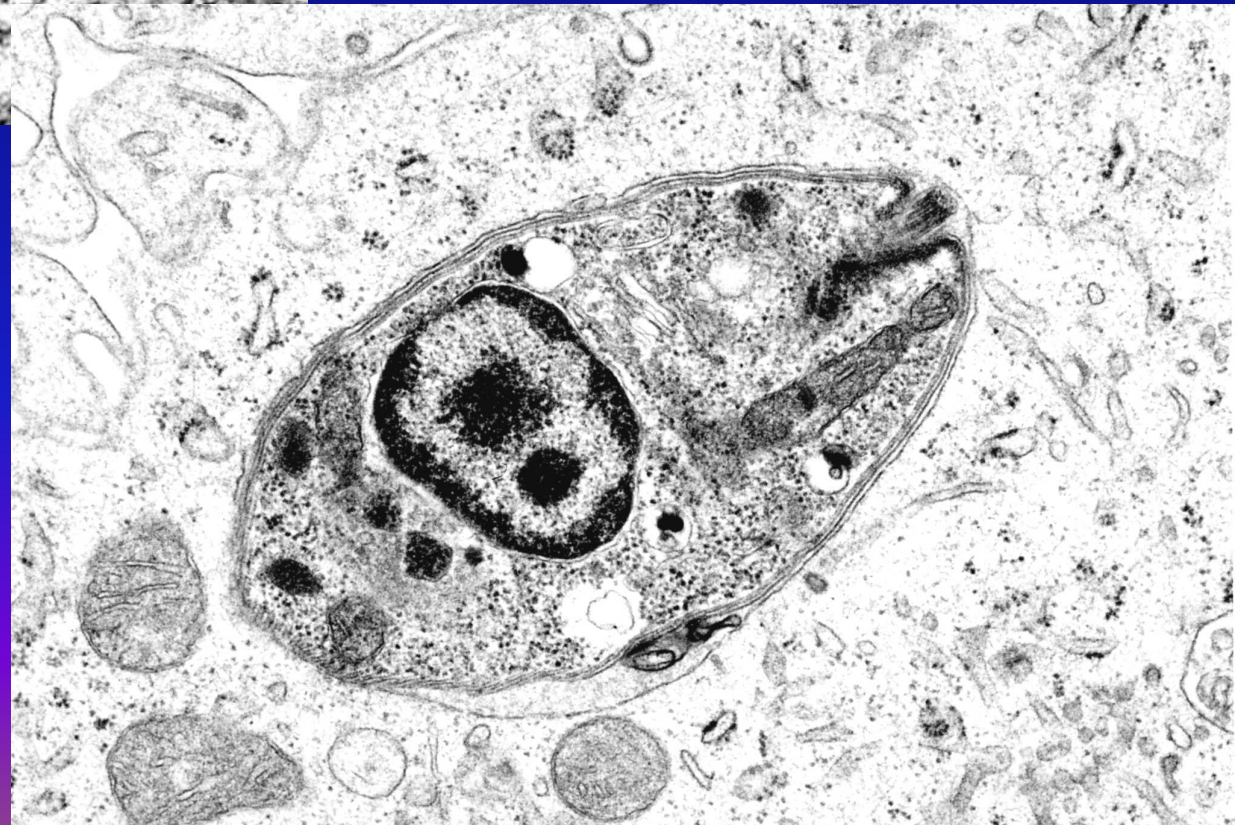
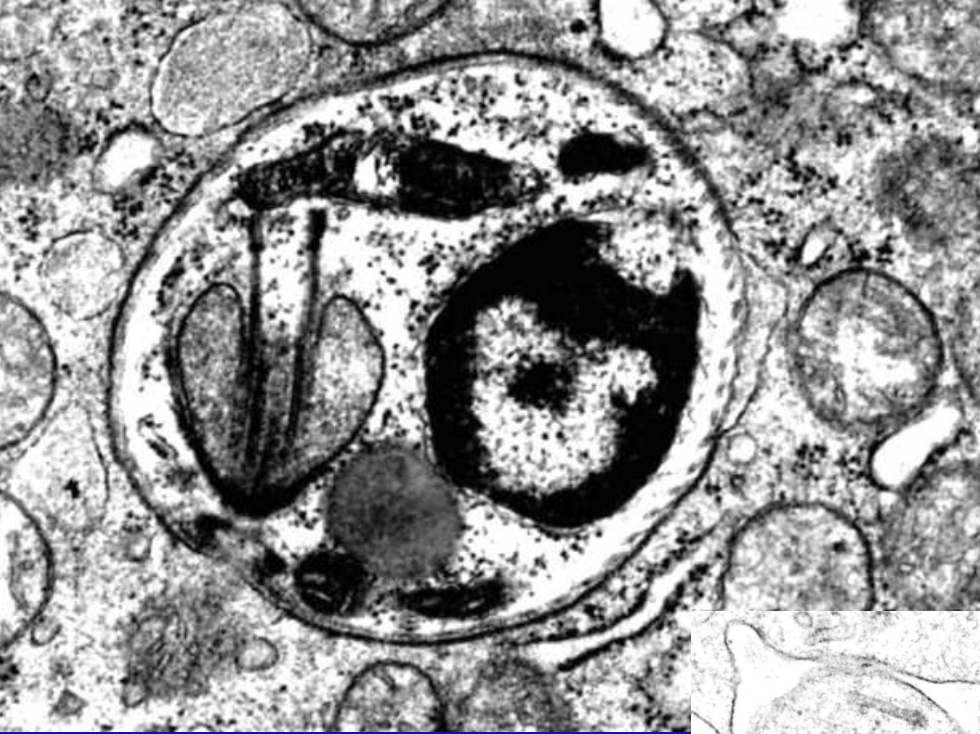



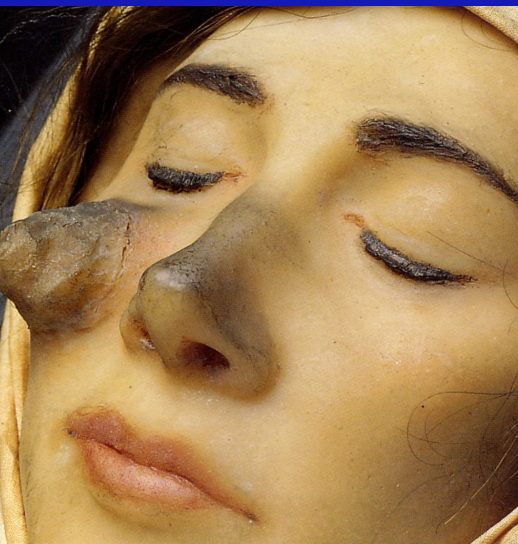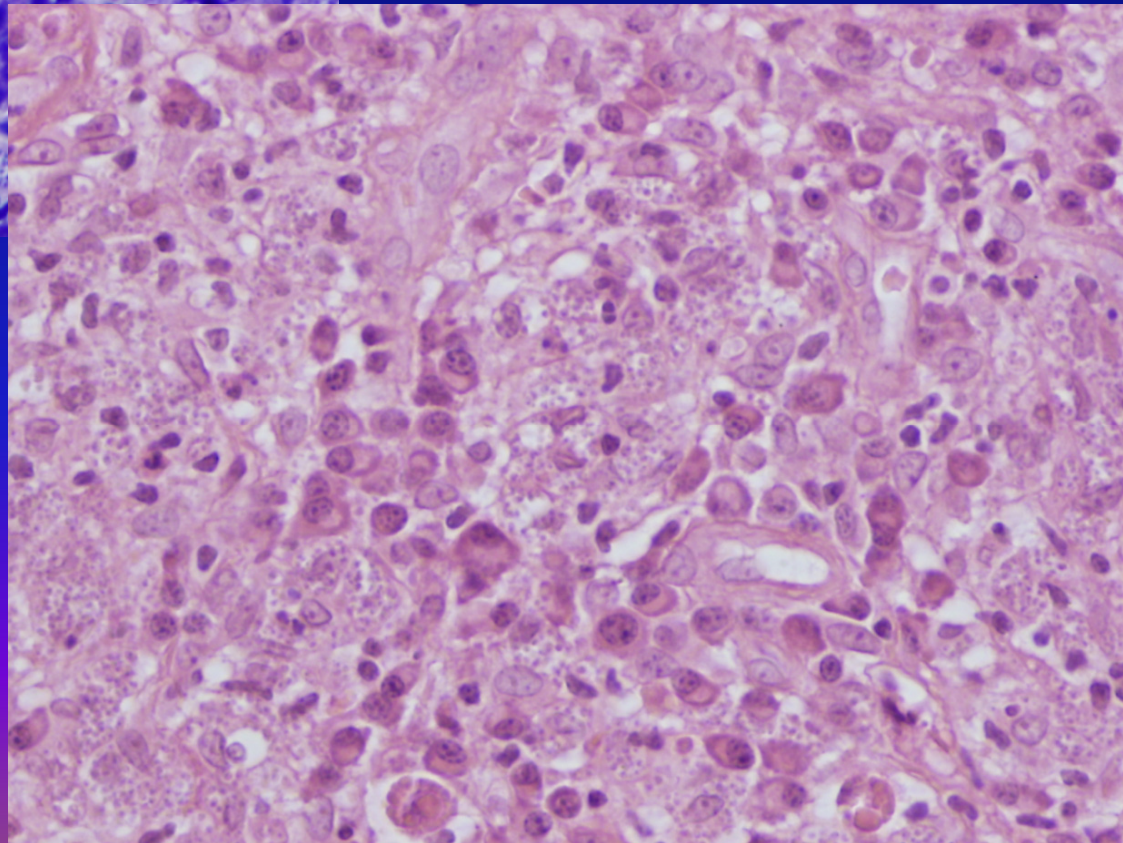
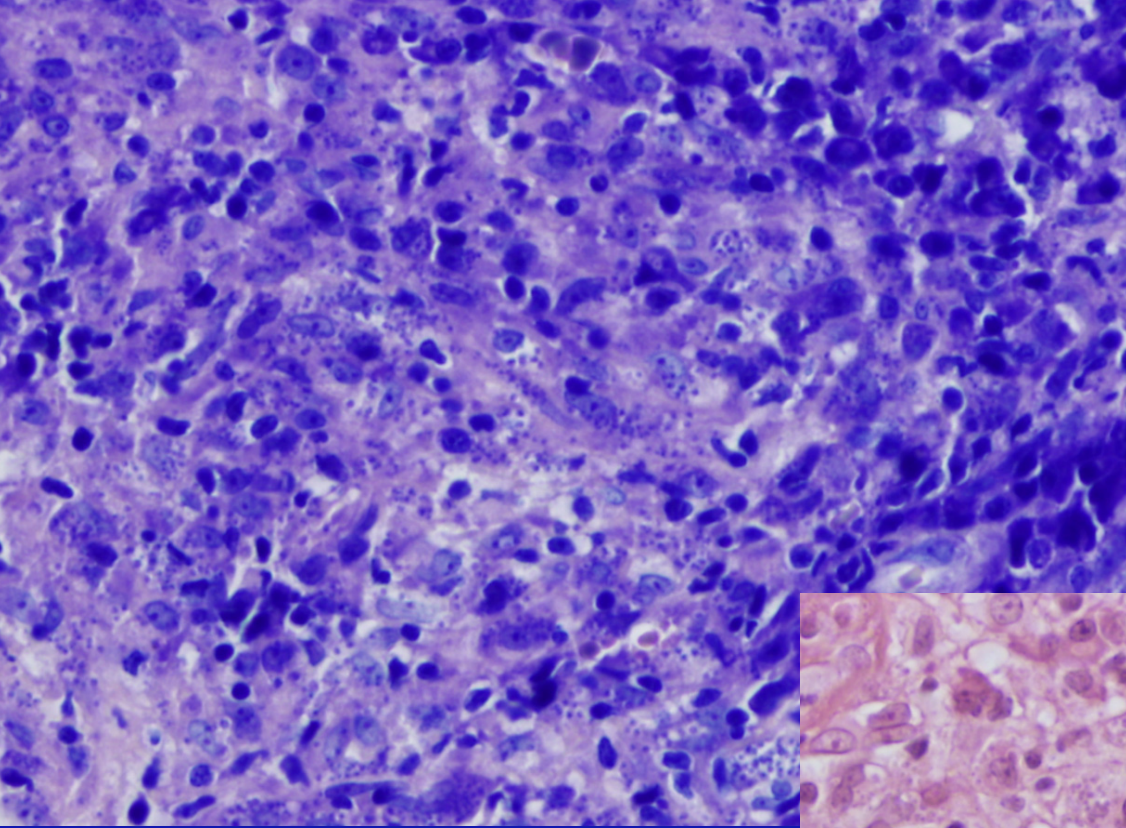




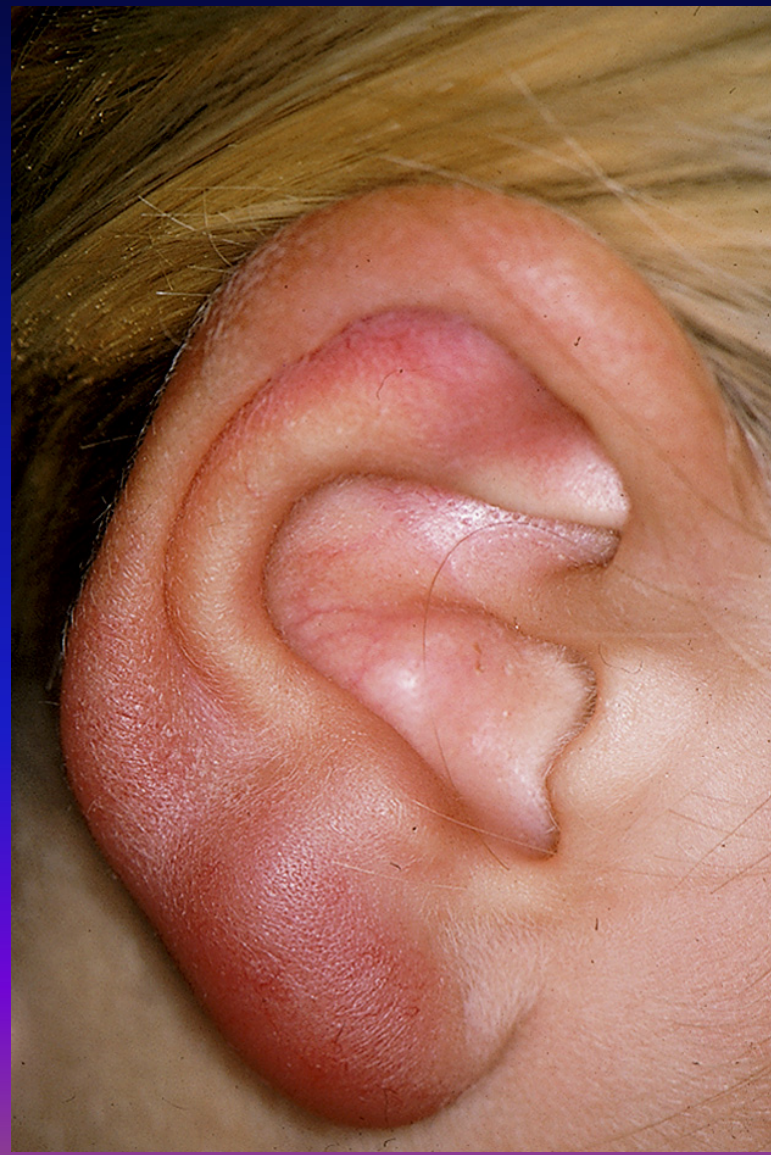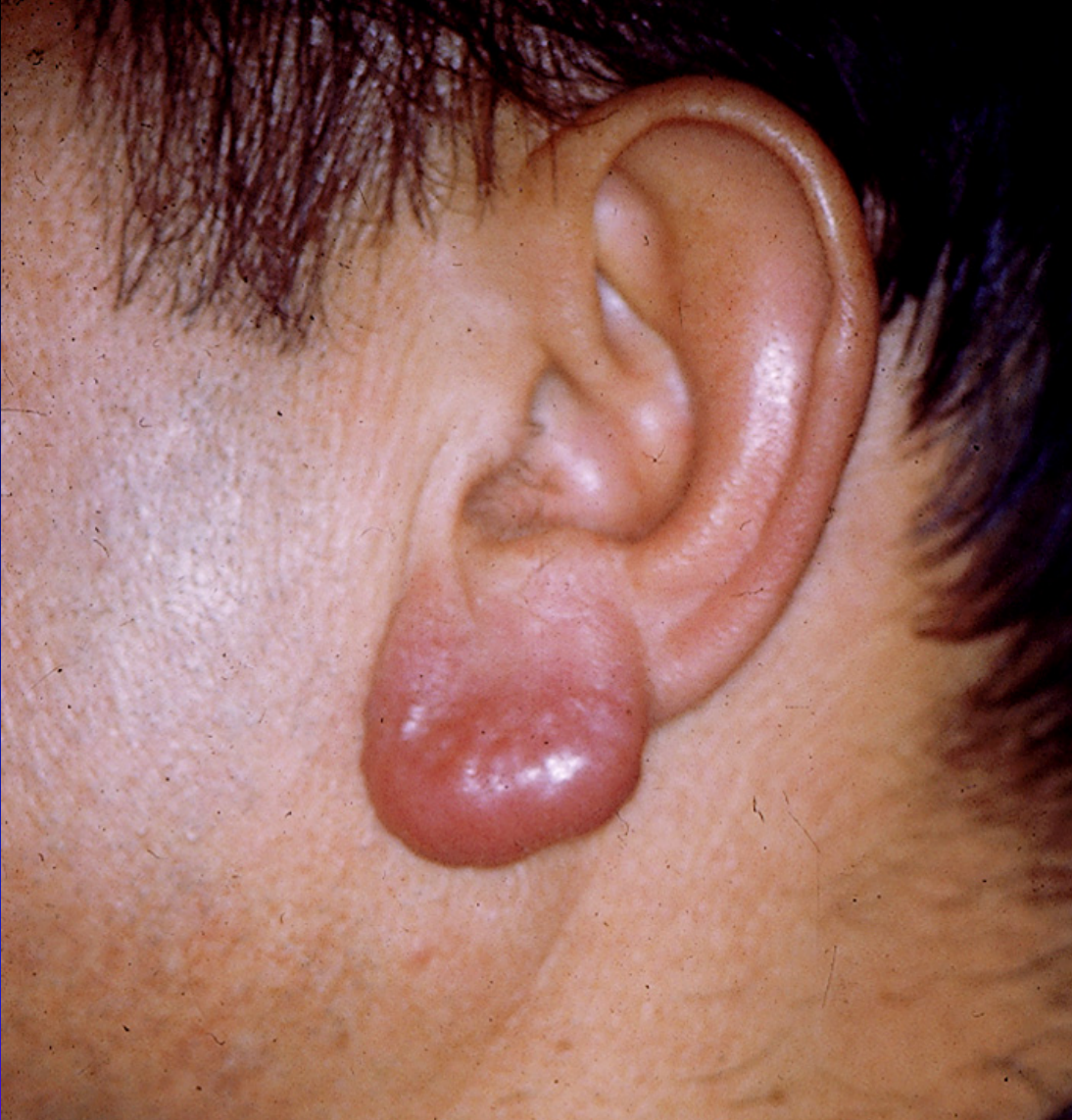# Leishmania





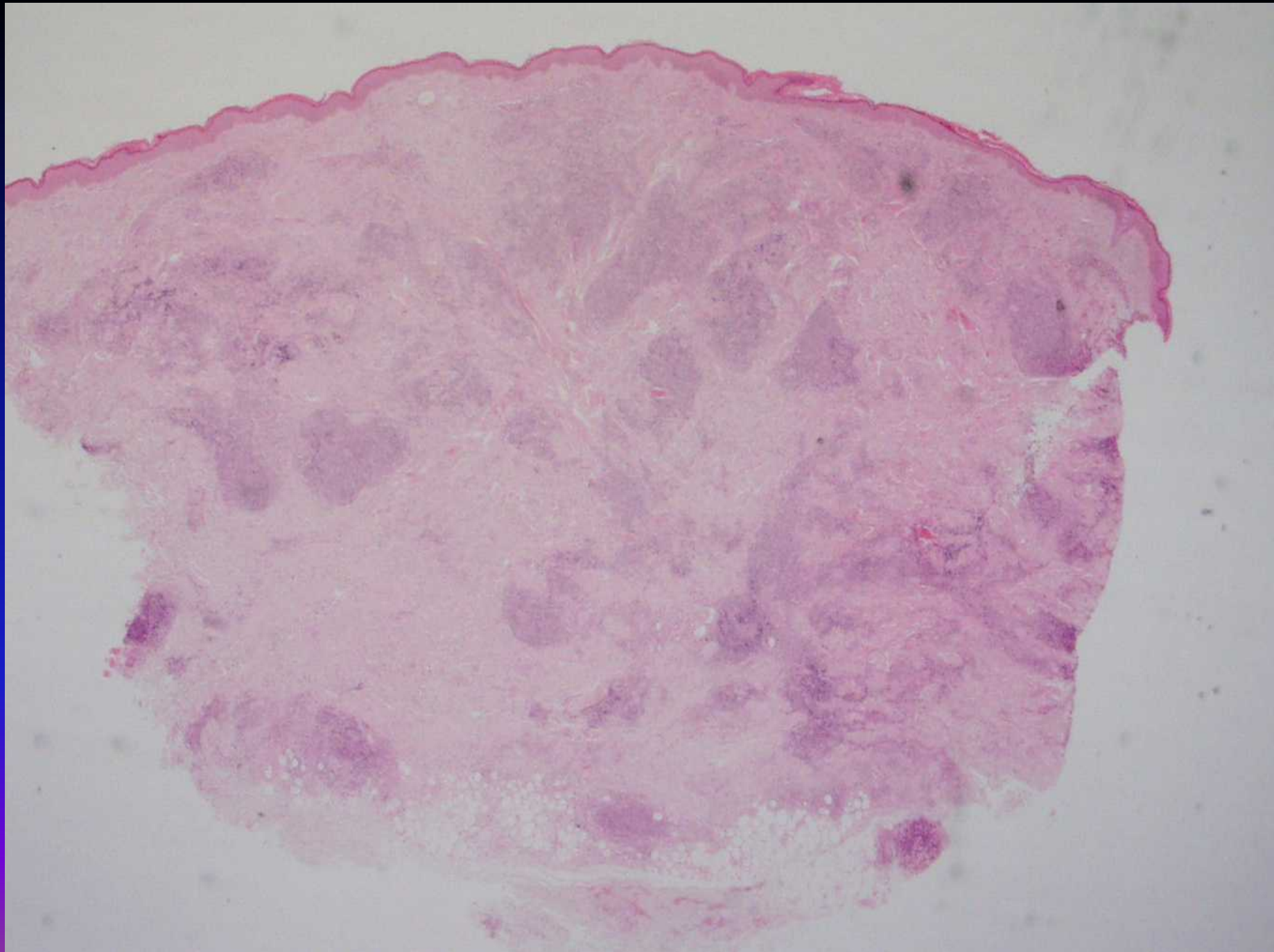




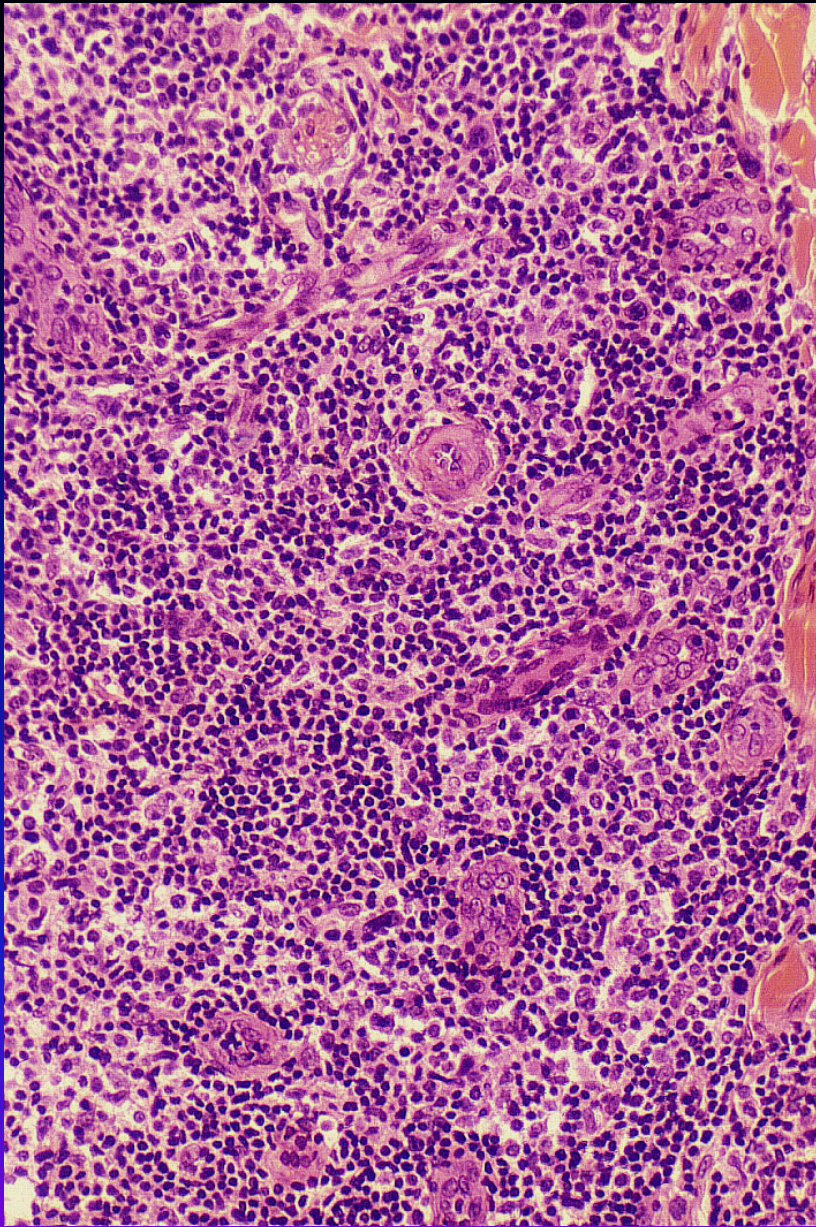


↑ Coll. B. Cribier, France



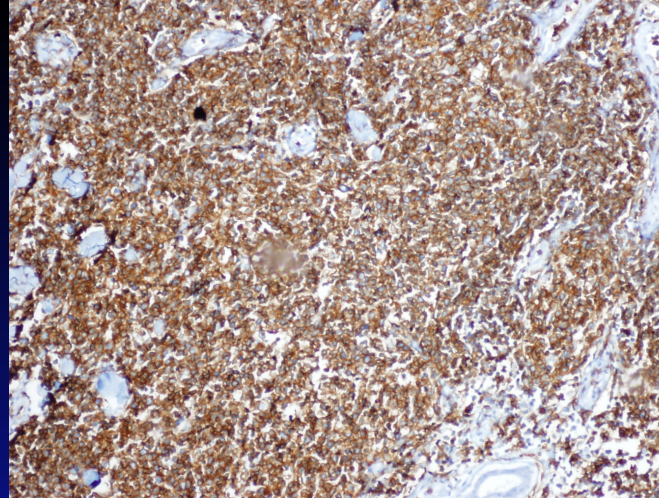
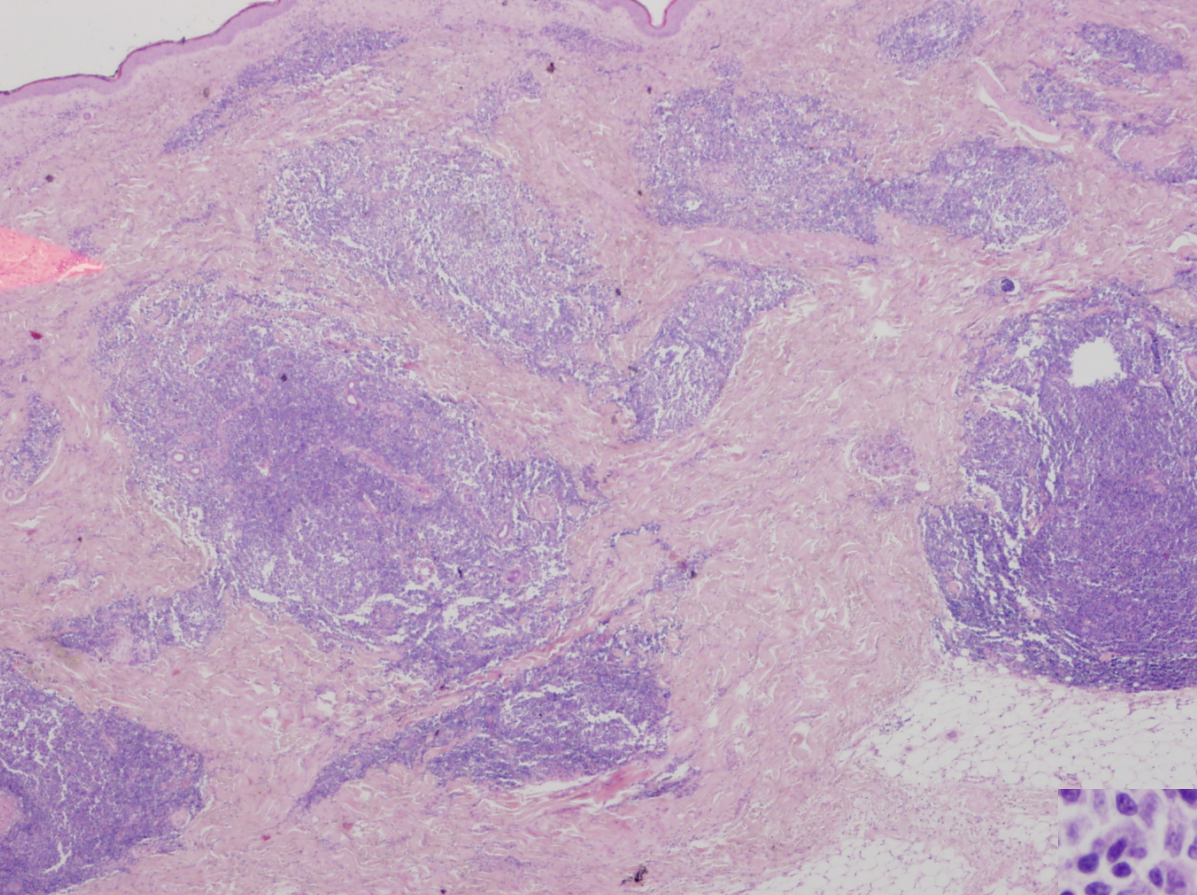




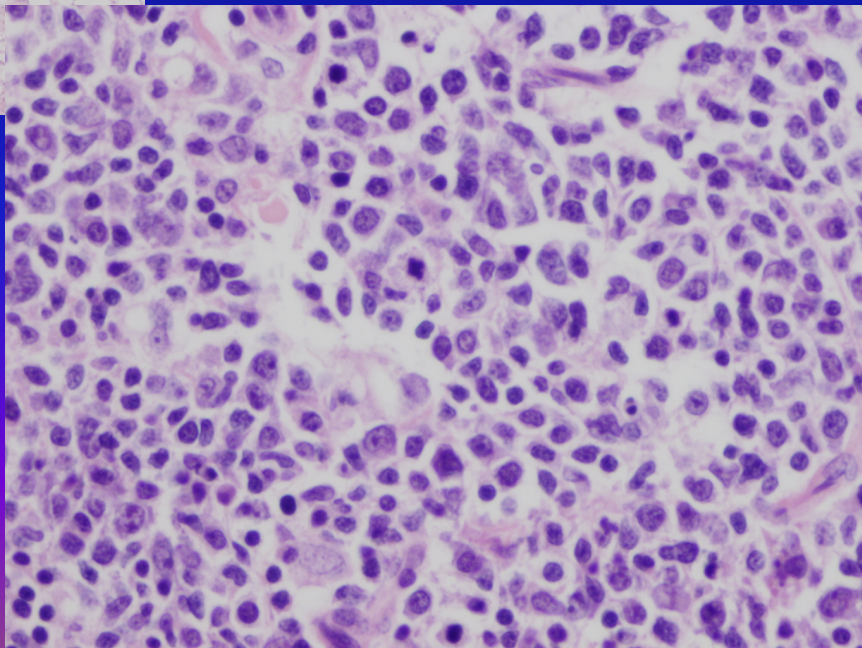


**Lyme disease  
Pseudo lymphoma**



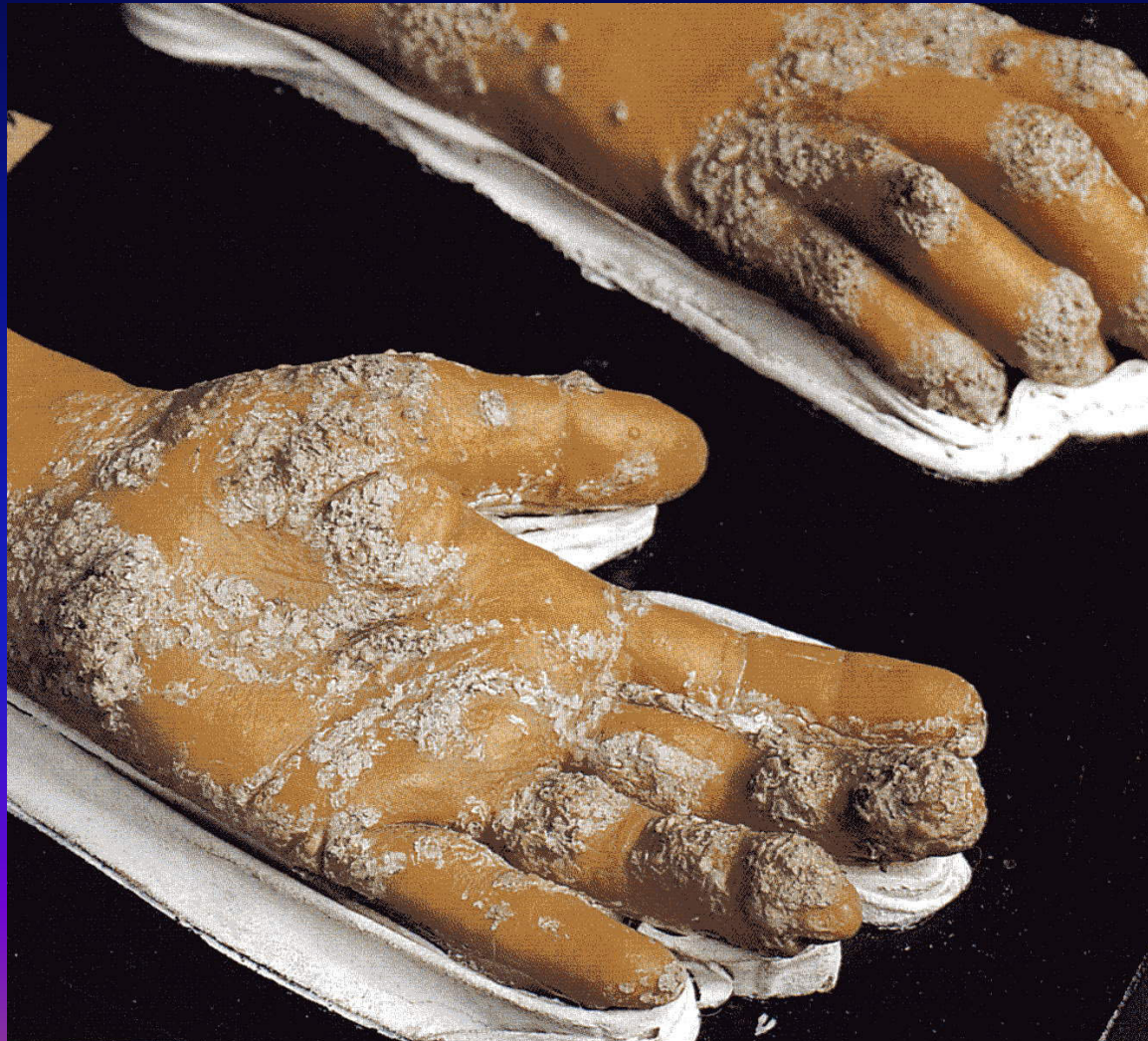

**Marginal zone lymphoma  
(PCR + Borrelia)**

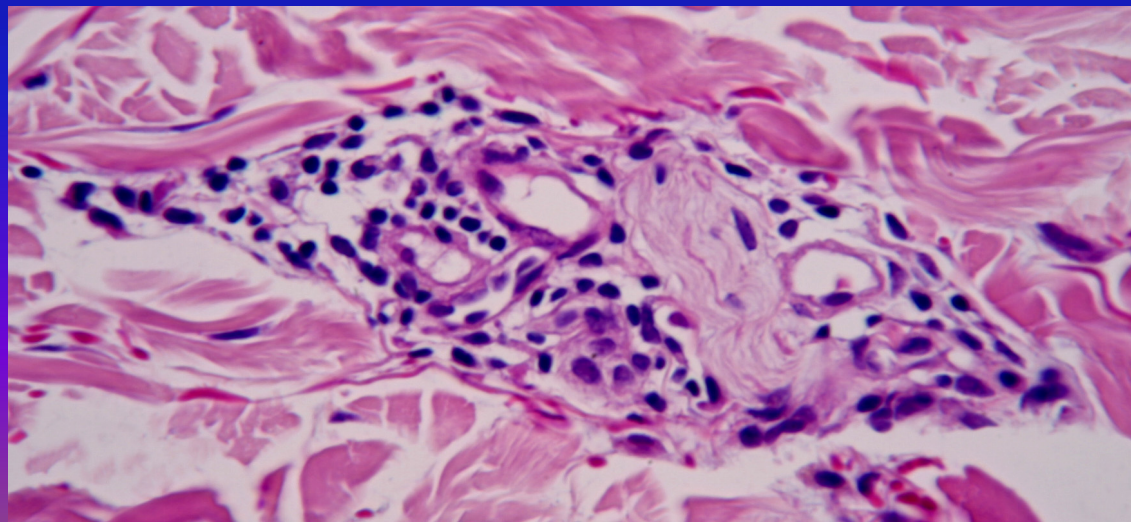
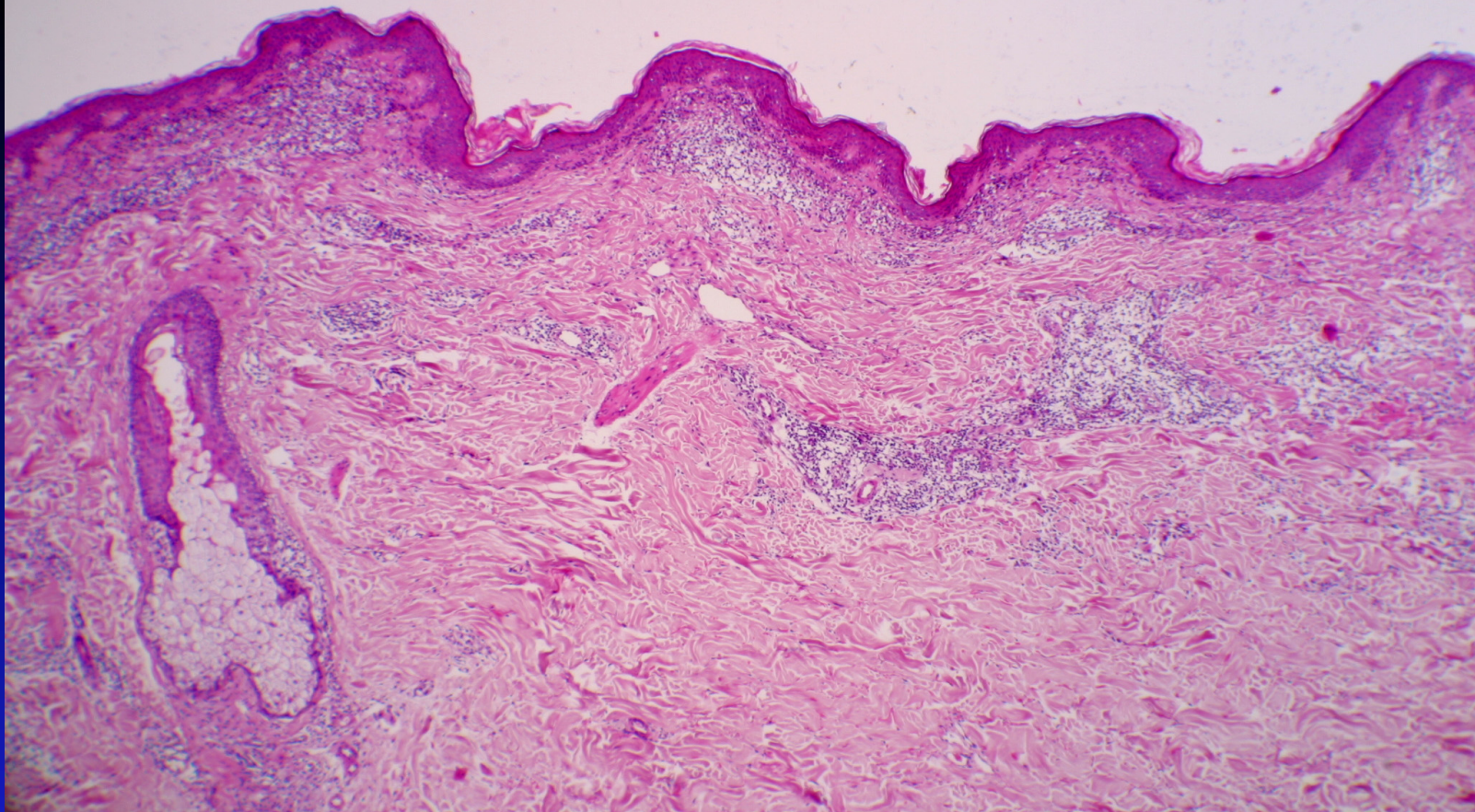




# Erythematous-squamous and atrophic Lesions

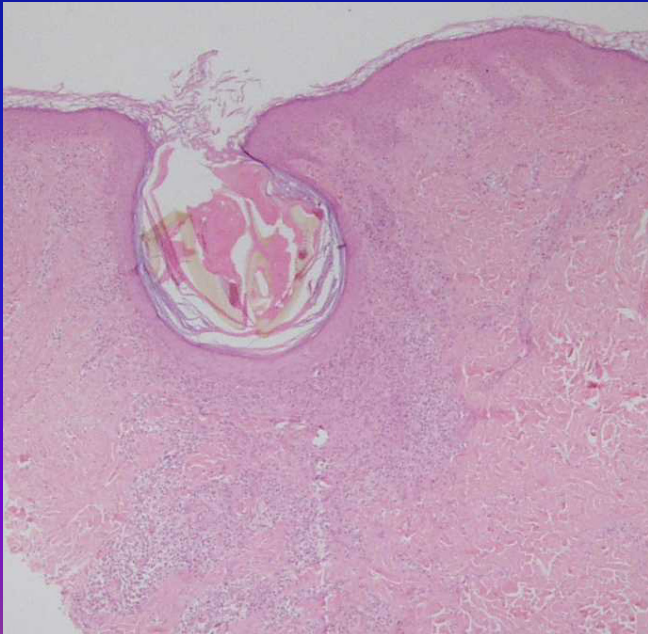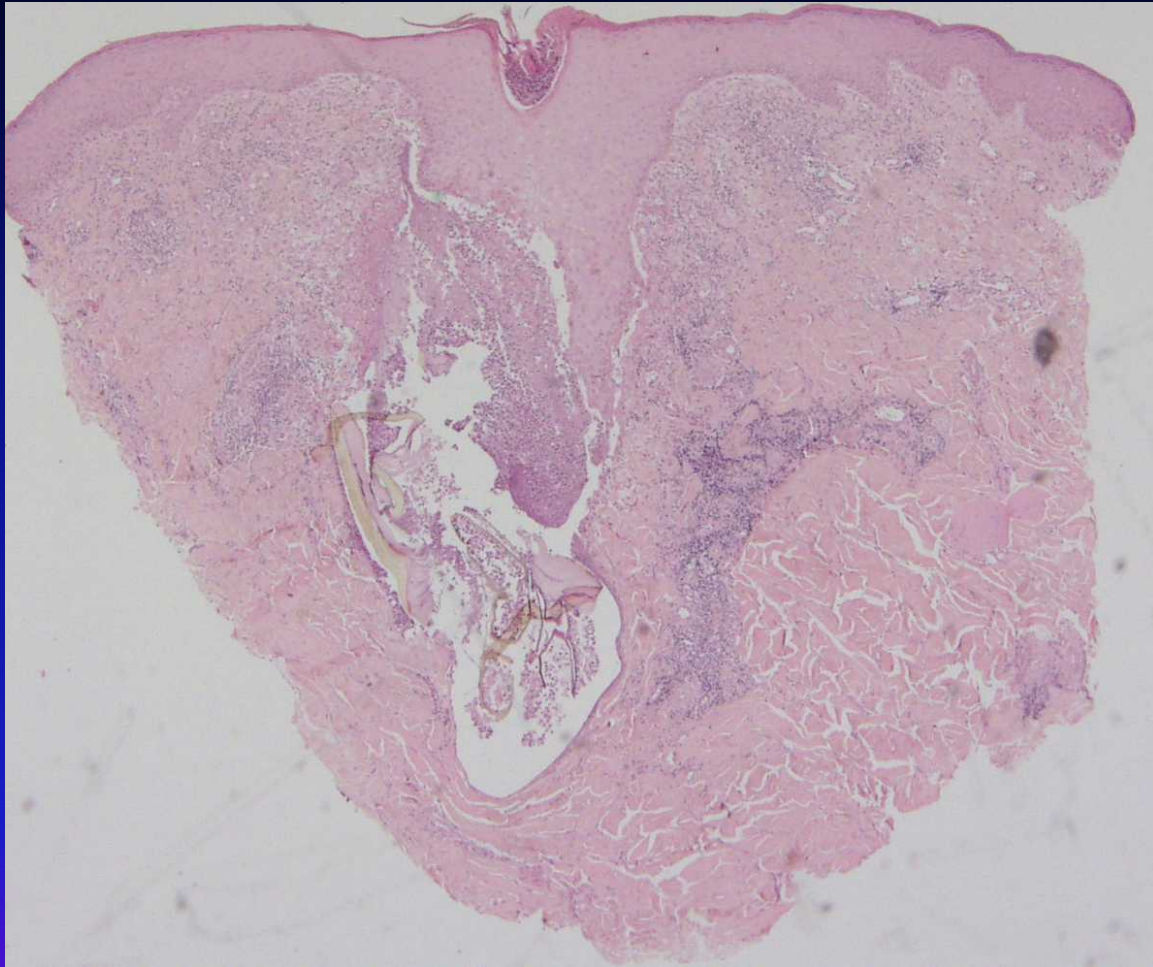

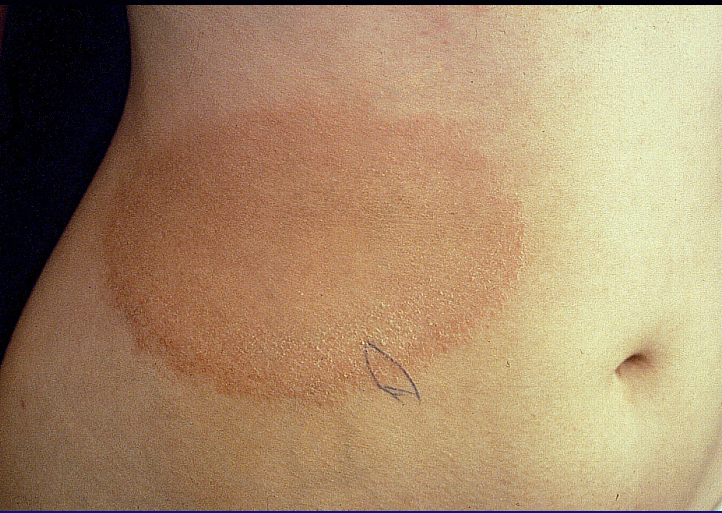




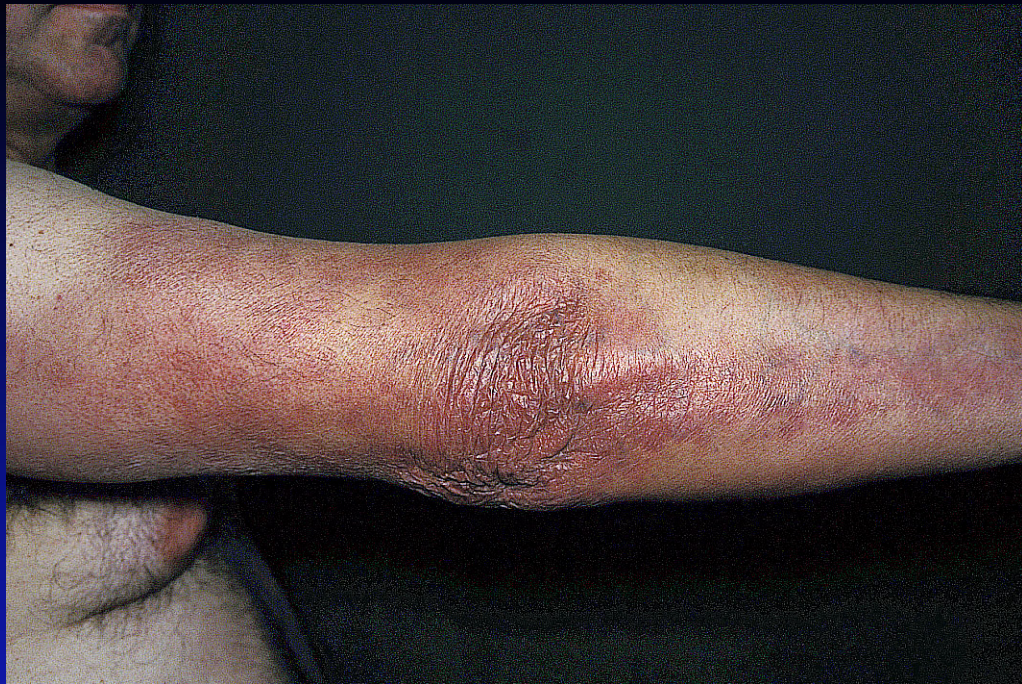**Lyme disease  
Erythema chronicum  
migrans**

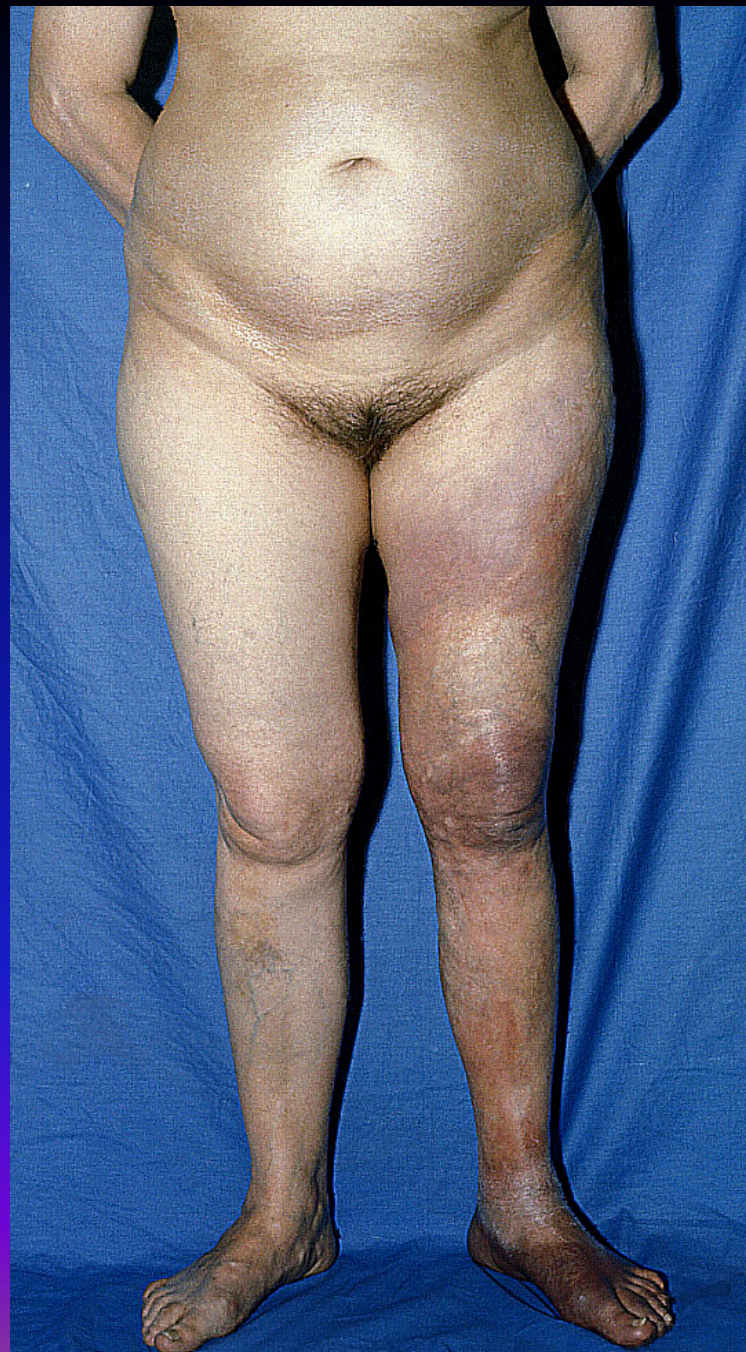



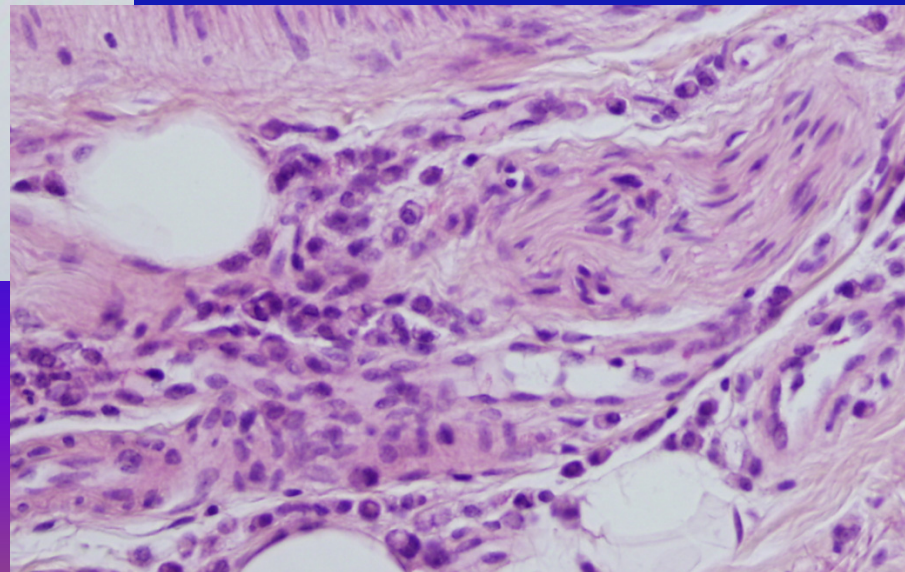
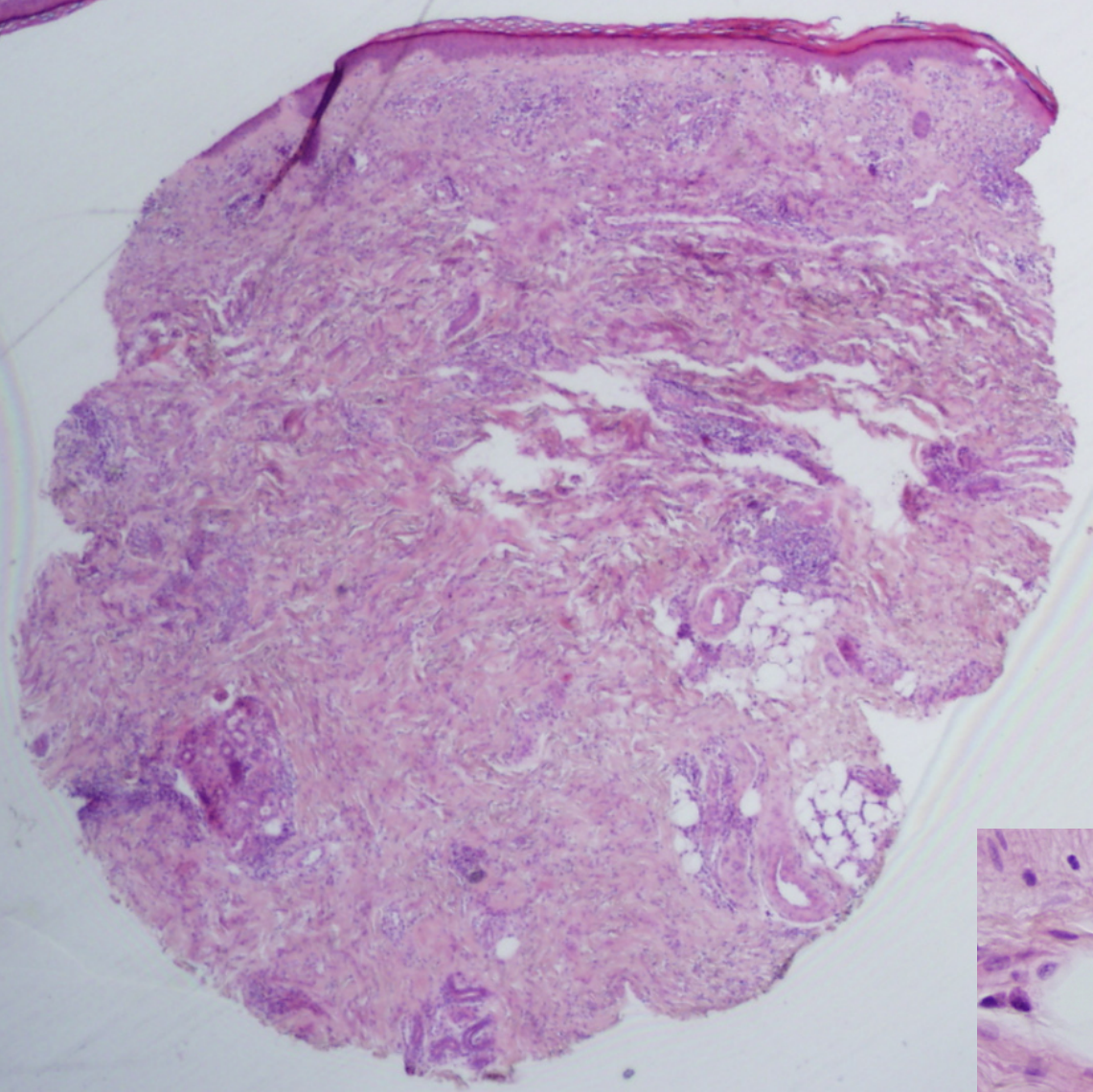




Coll. B. Cribier, France



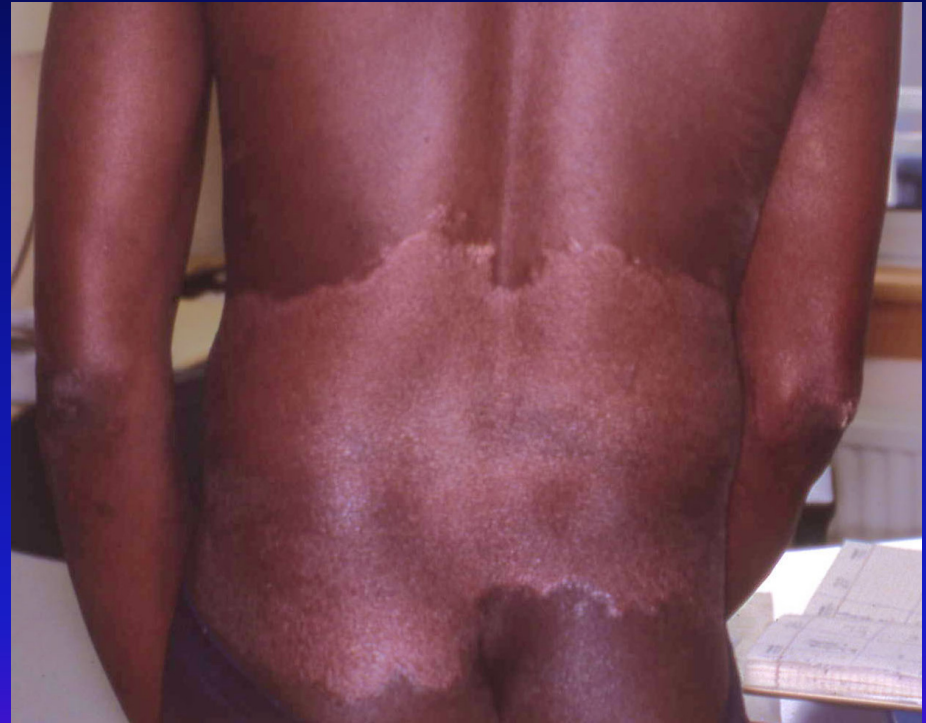



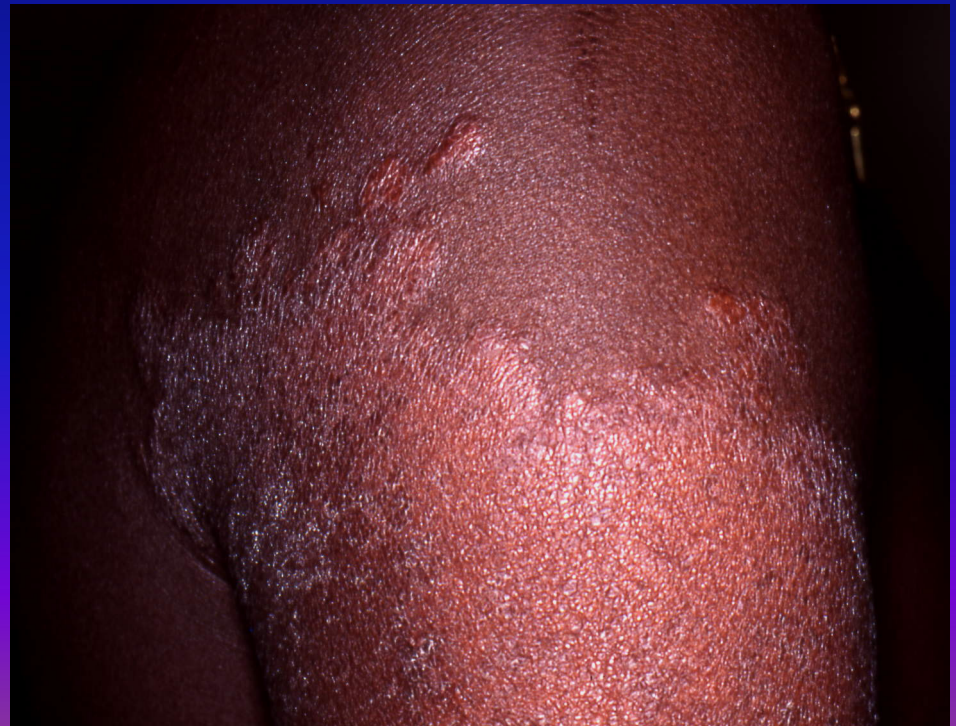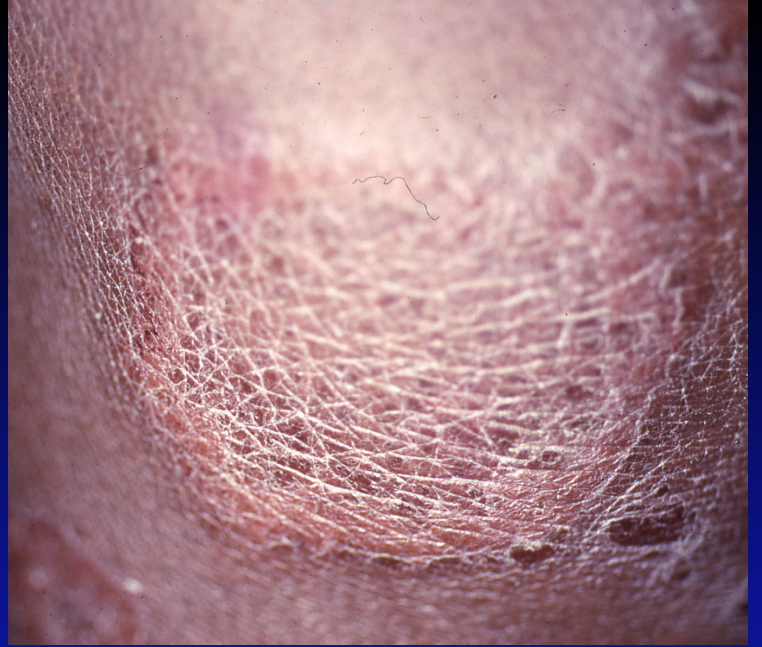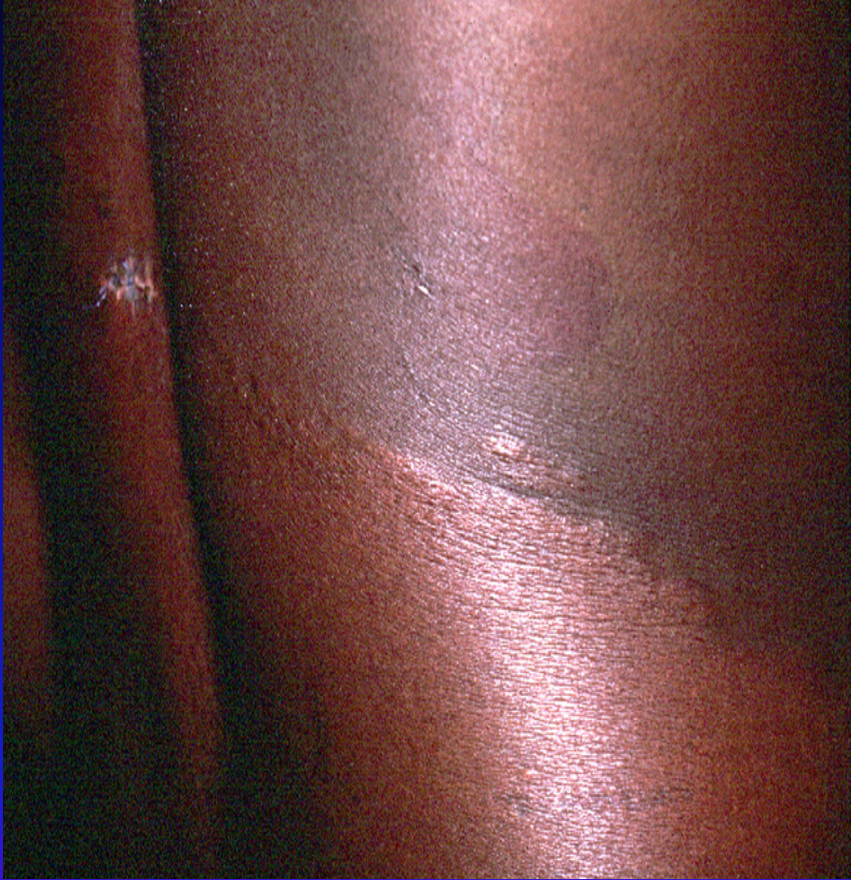**Lyme disease  
Acrodermatitis chronica  
atrophicans**



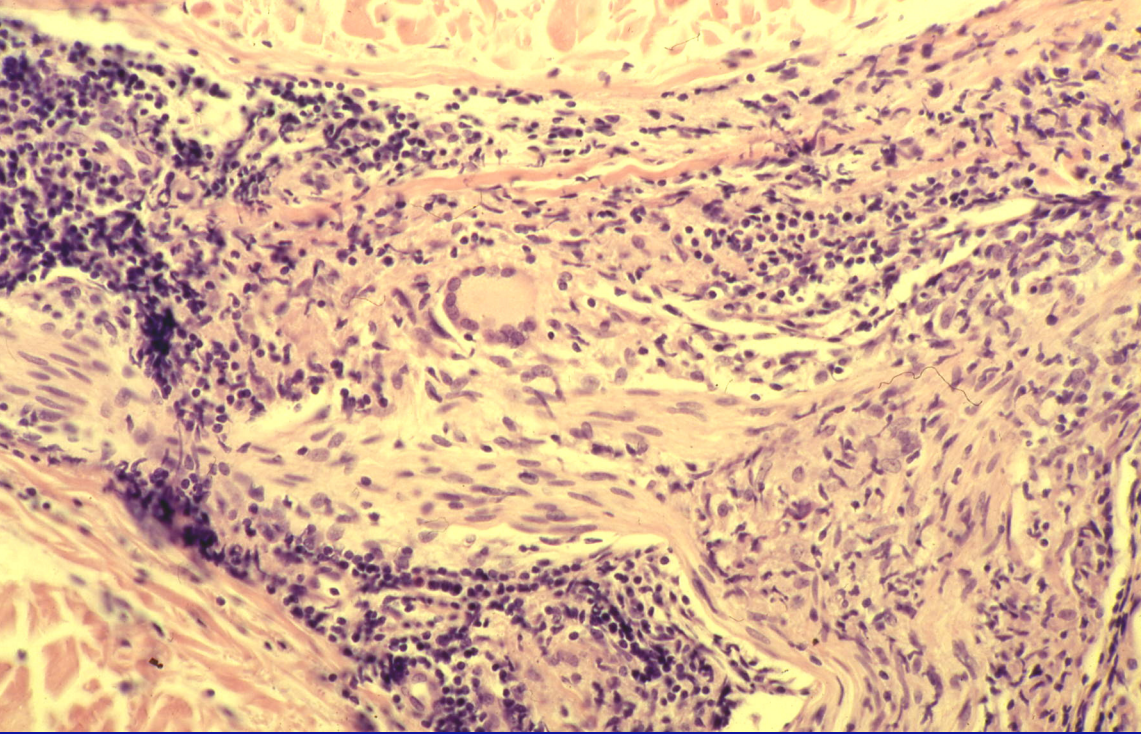
- 28-year-old man from Mali
- Hypopigmented, anesthetic macules
- Infiltrated edges



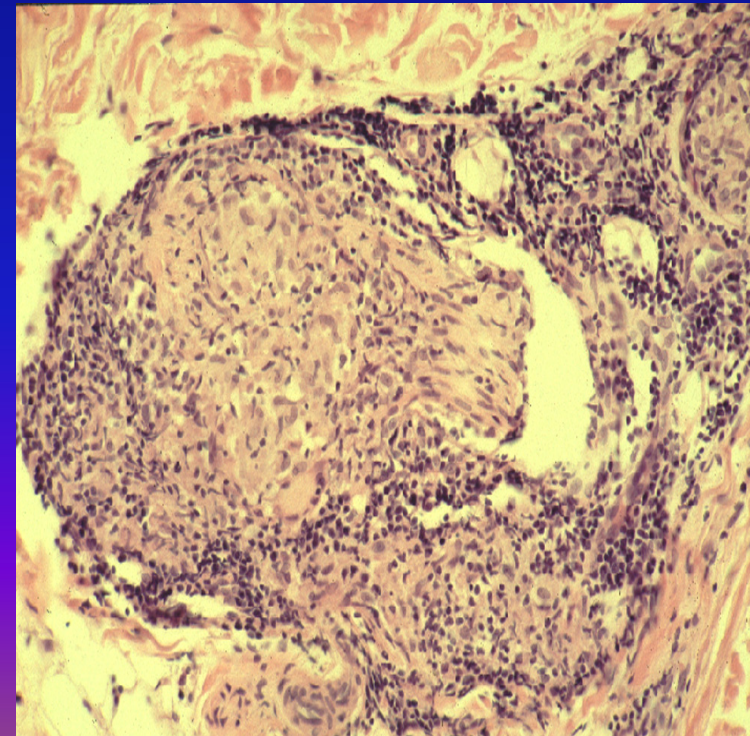






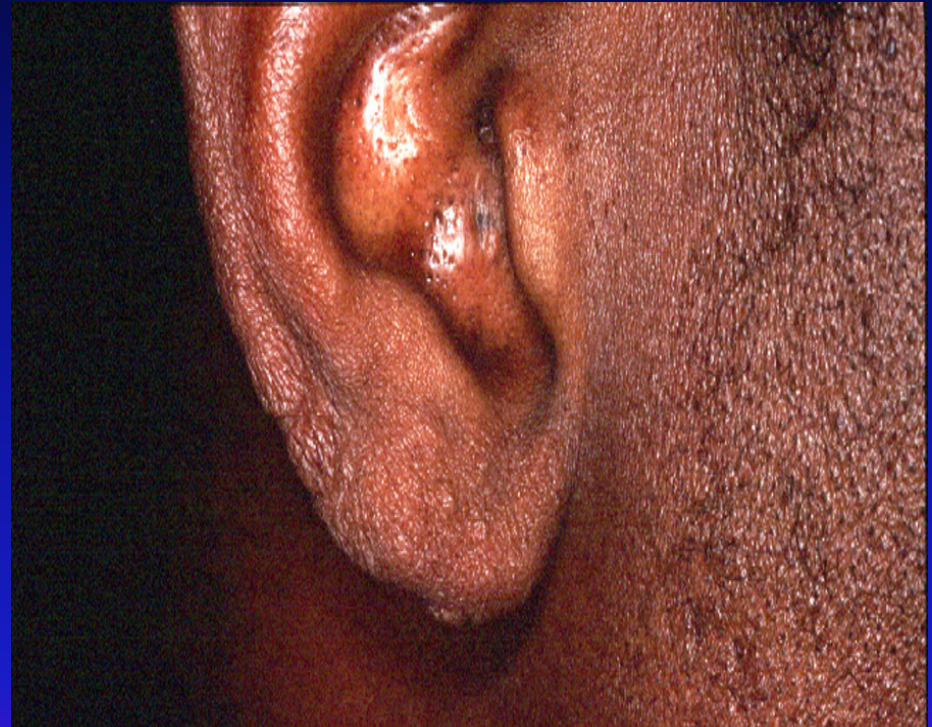

***Mycobacterium leprae***  
**Tuberculoid leprosy**

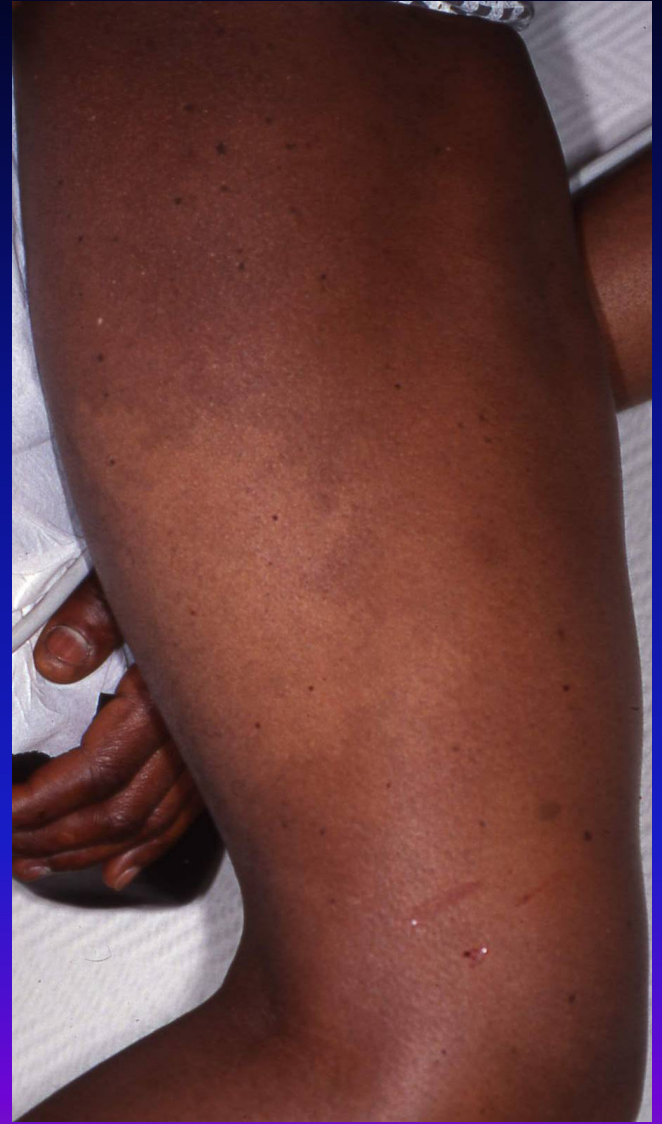
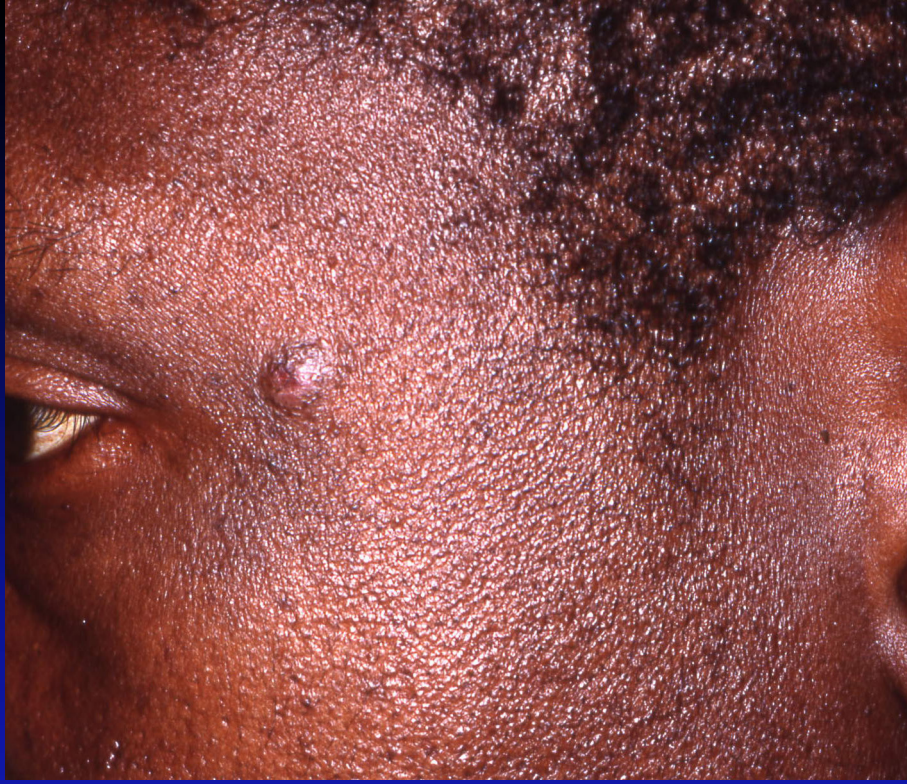


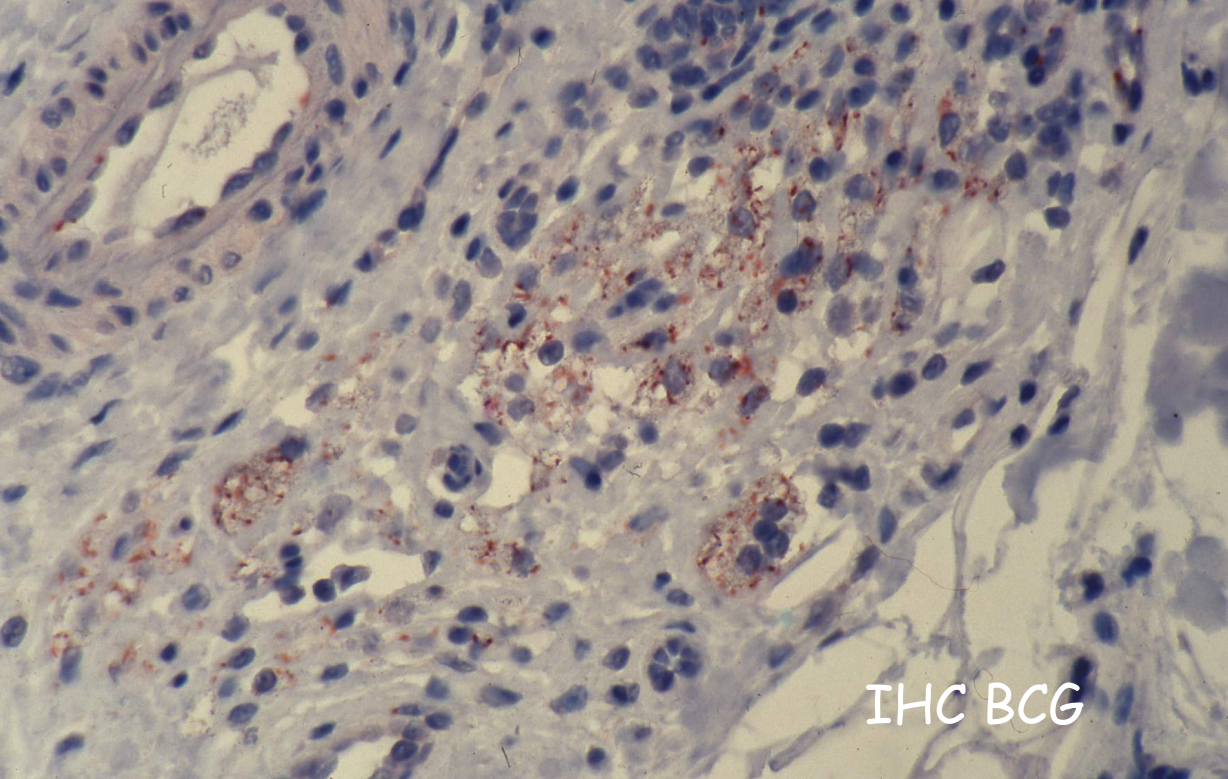
- 38 year-old male from Guinea
- Hypoesthetic papules and nodules on ear lobes



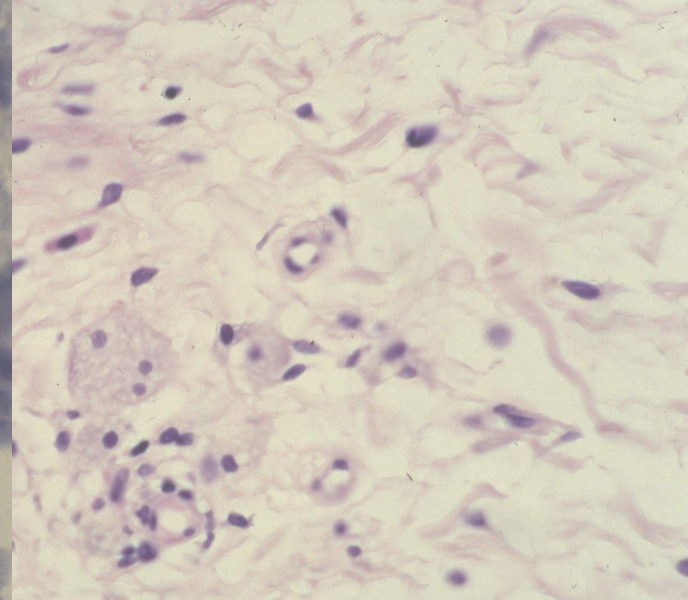






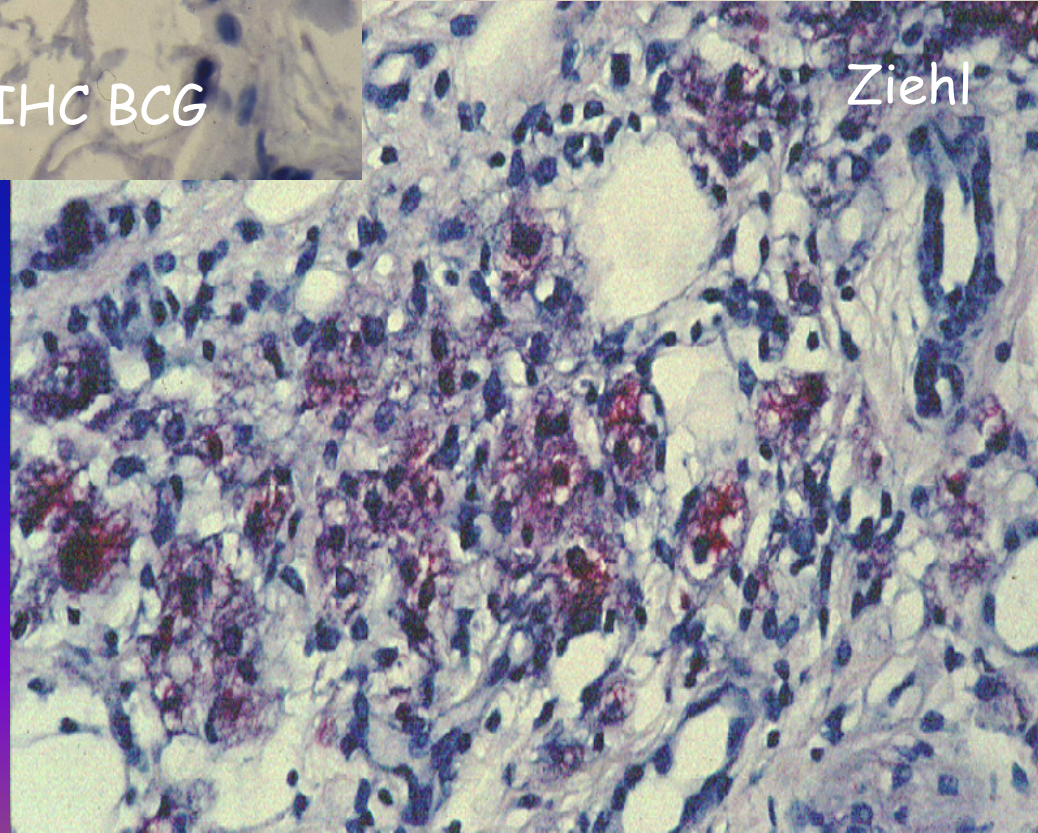


IHC BCG

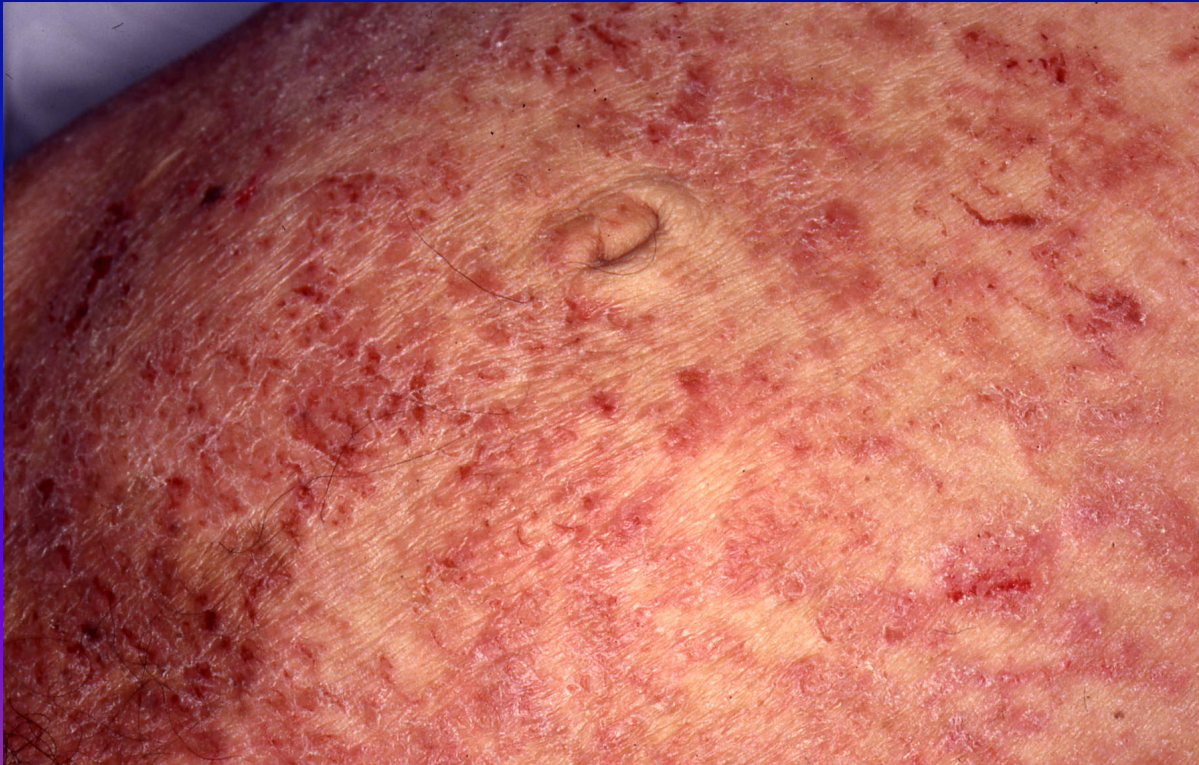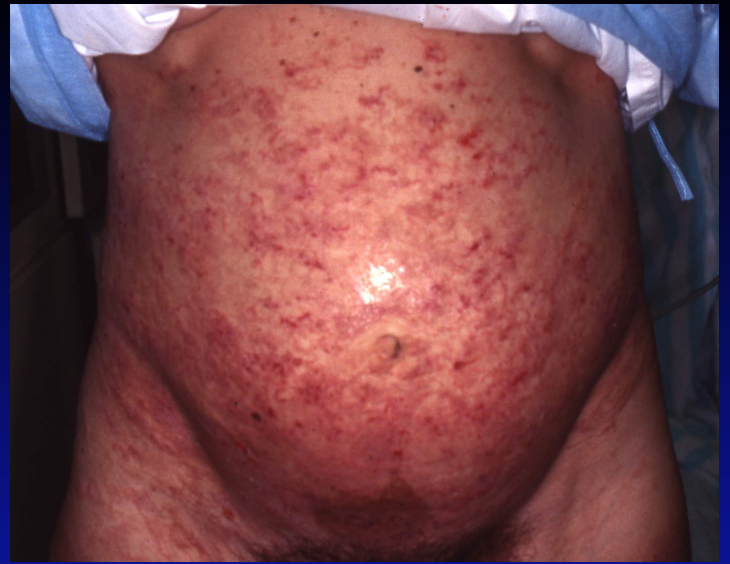

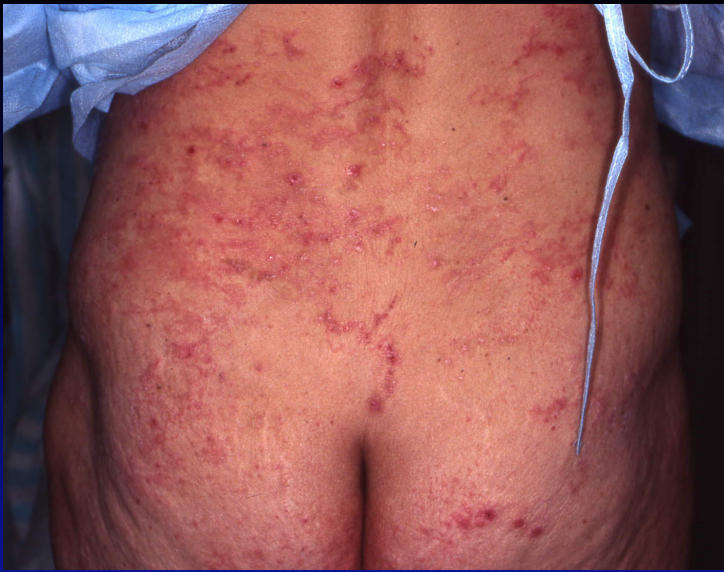
Ziehl

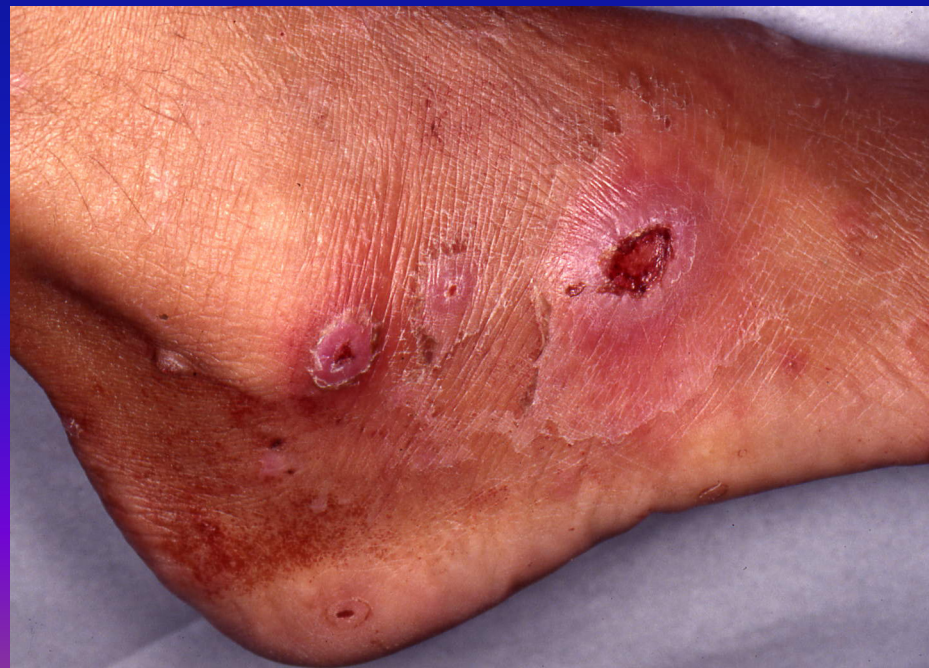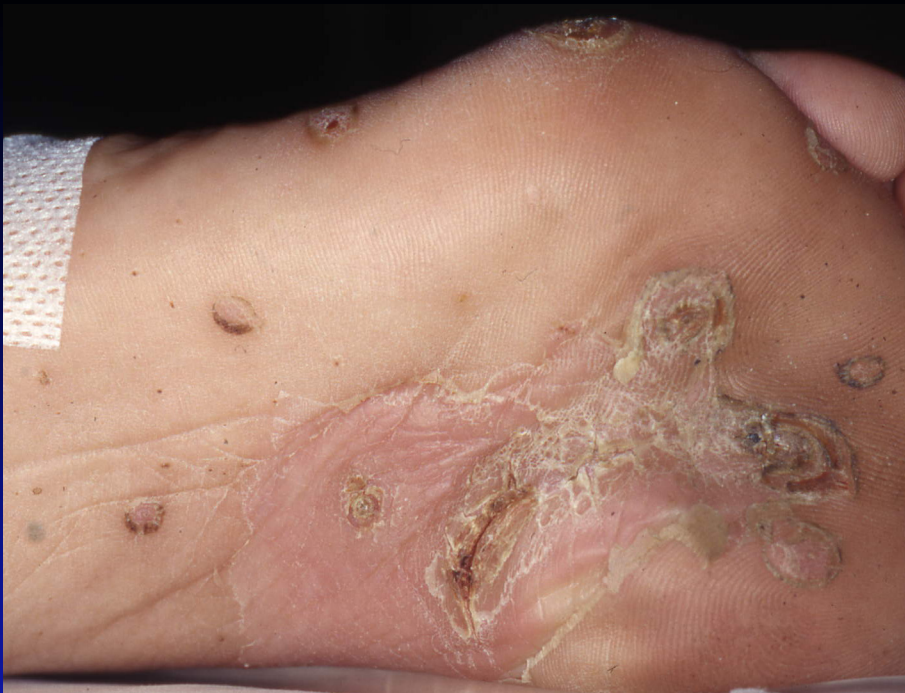***Mycobacterium leprae***  
**Lepromatous leprosy**



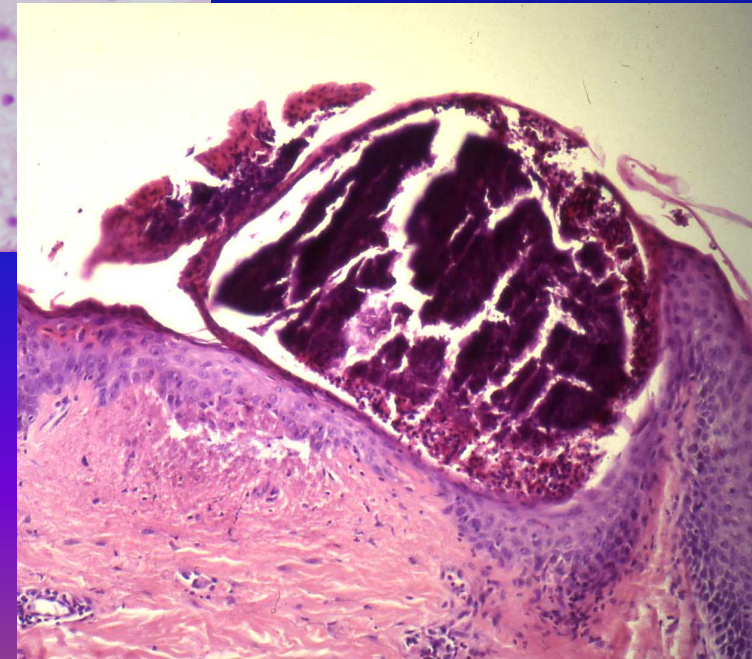
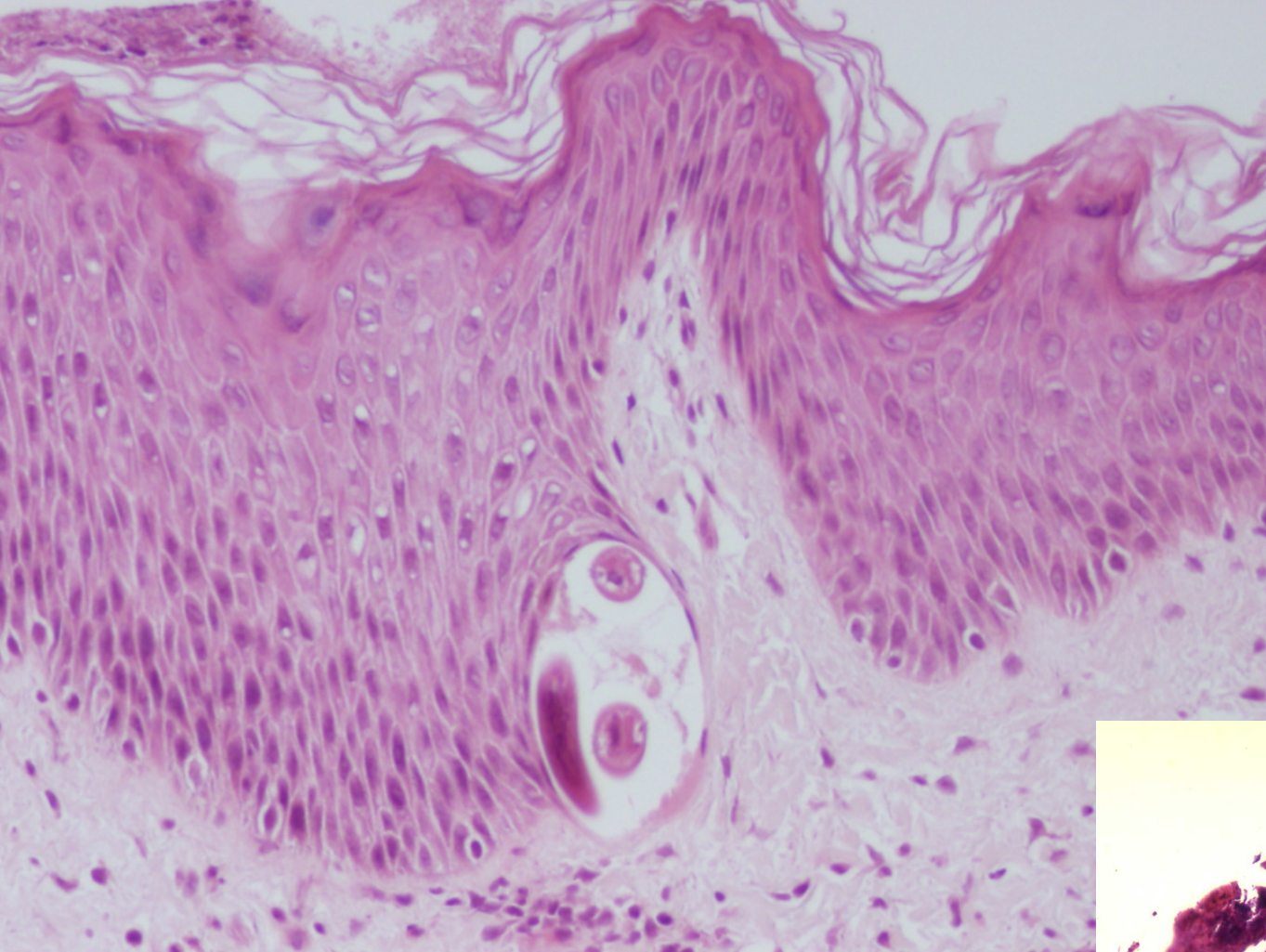






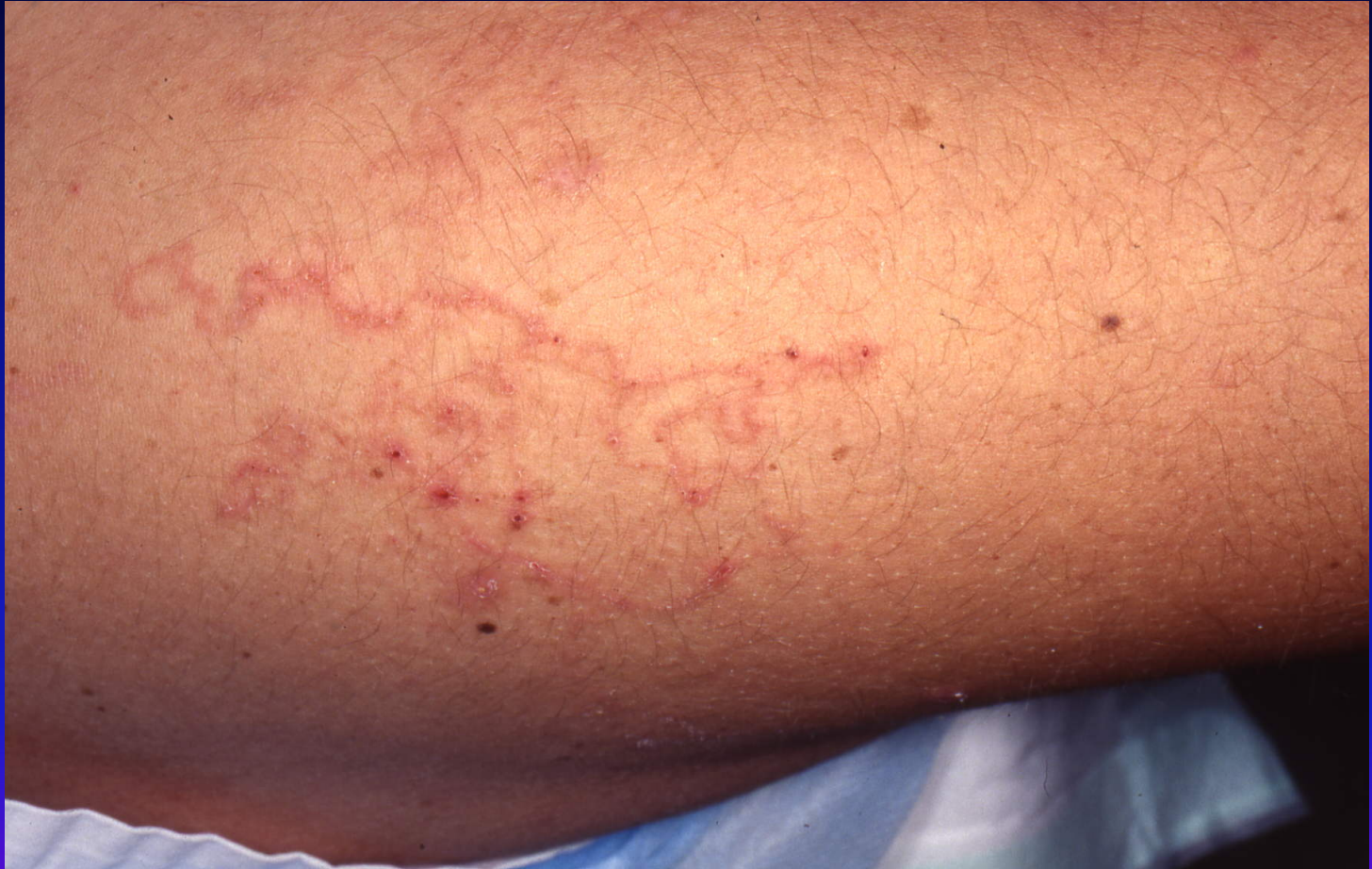





**Ankylostoma (Larva migrans)**



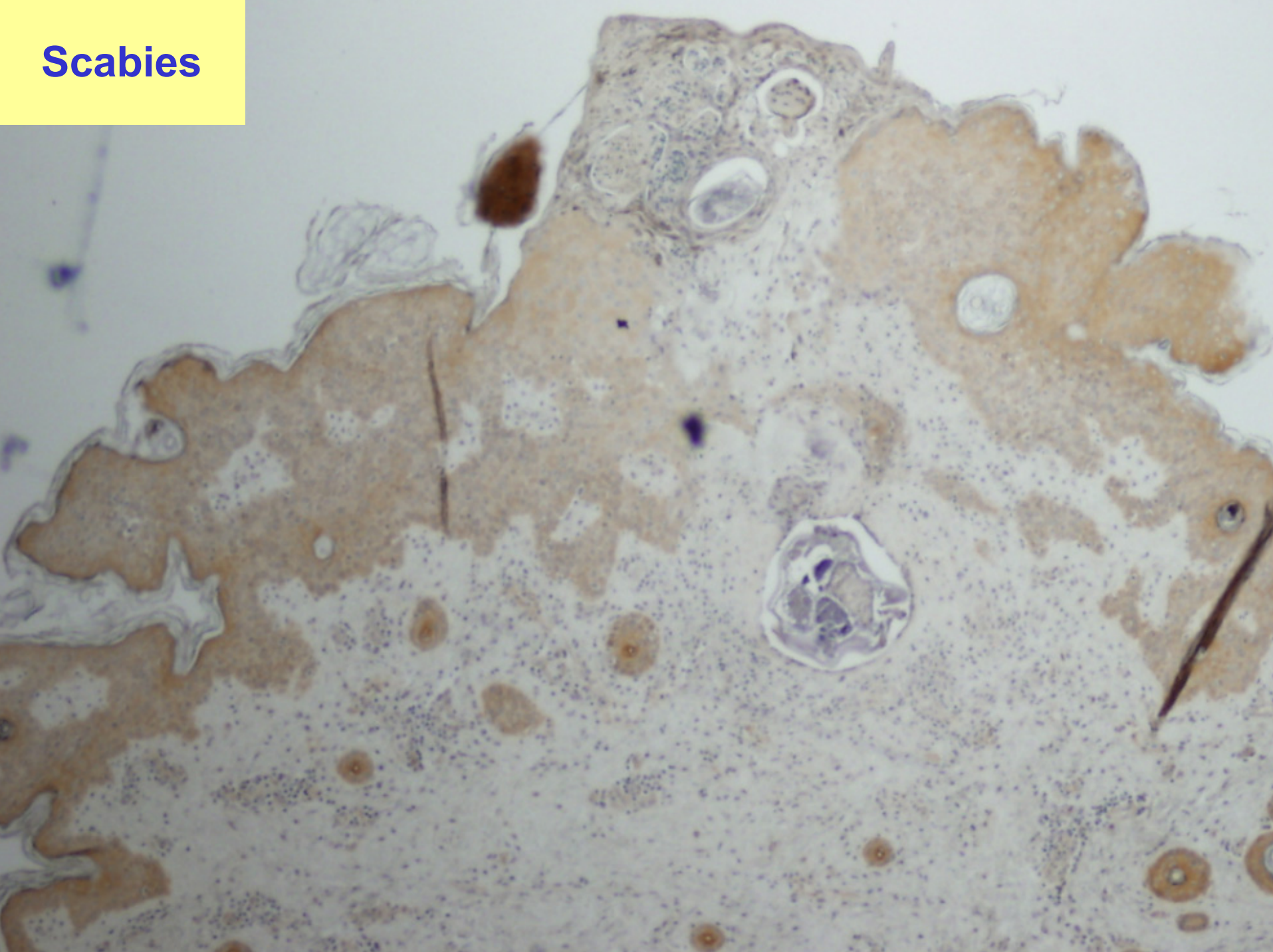




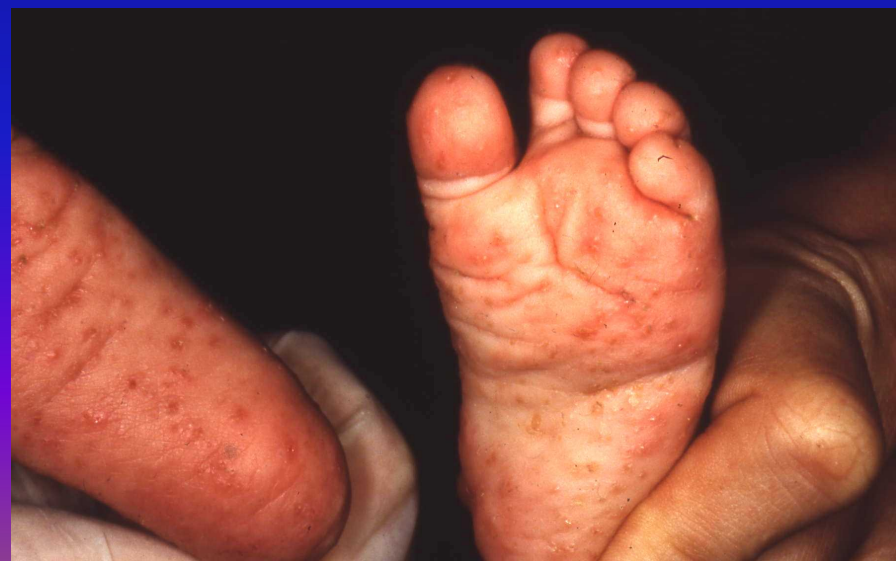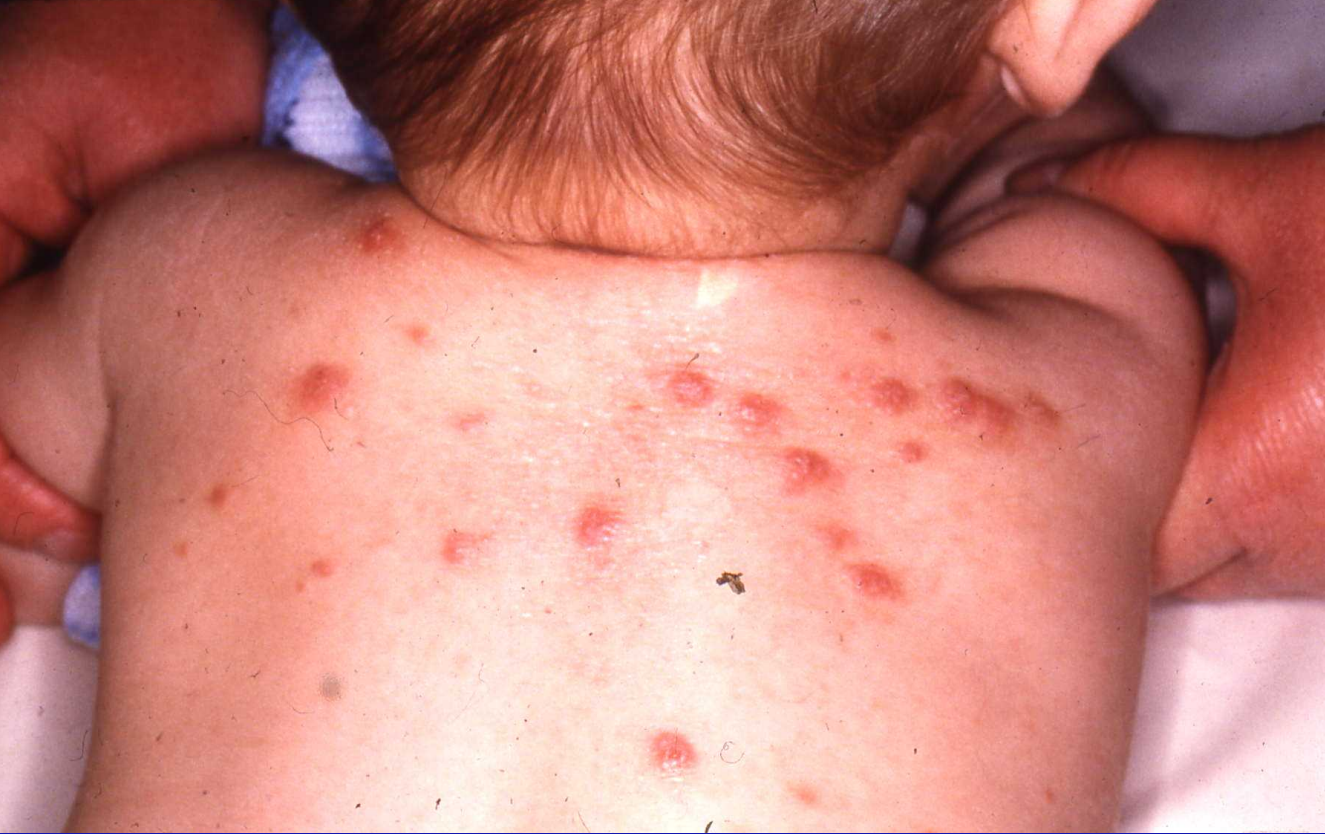
- 2-year-old girl
- Papules in the axillary folds and in the genital area
- Clinical diagnosis : Langerhans cell histiocytosis?



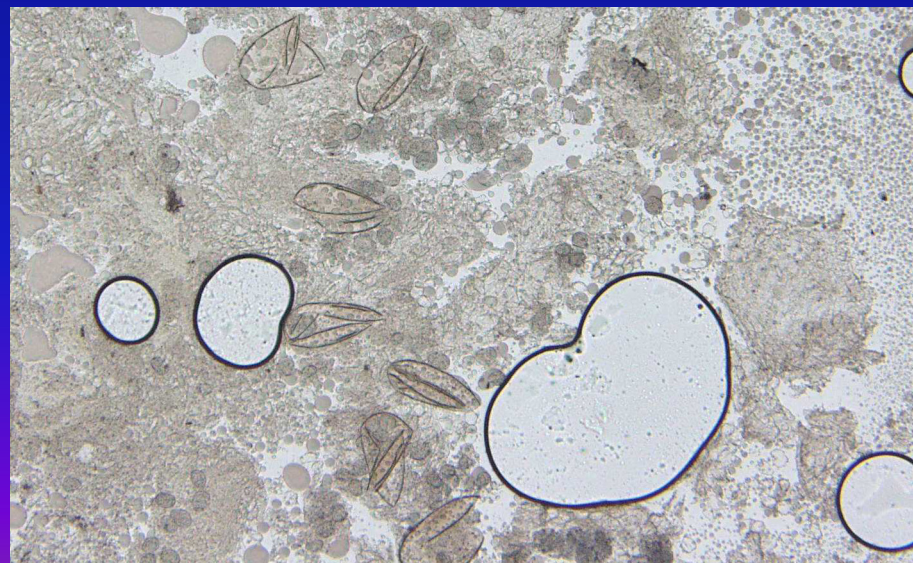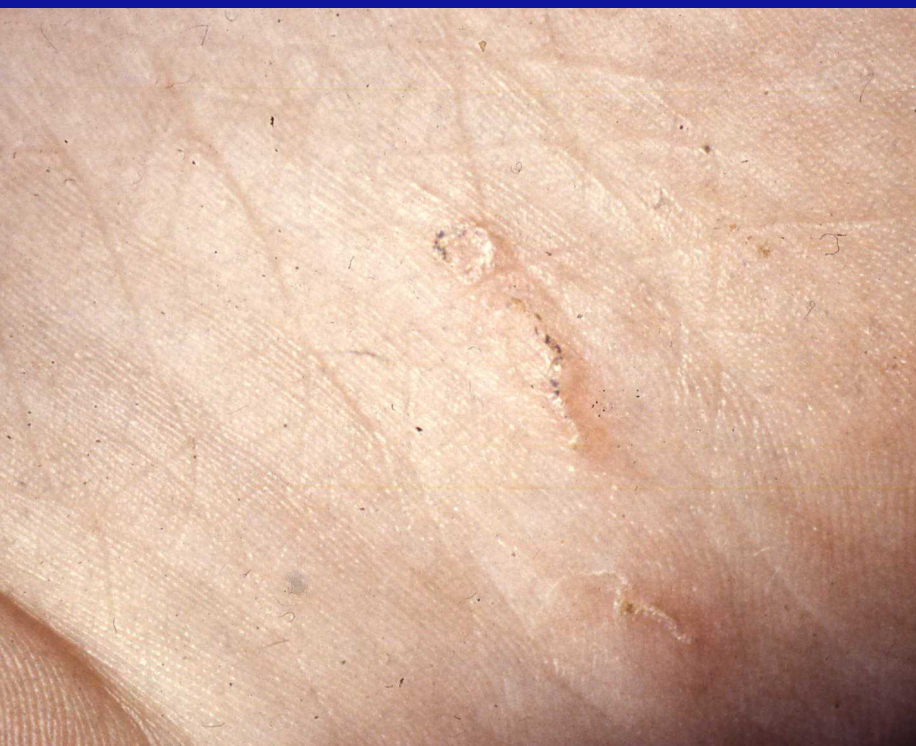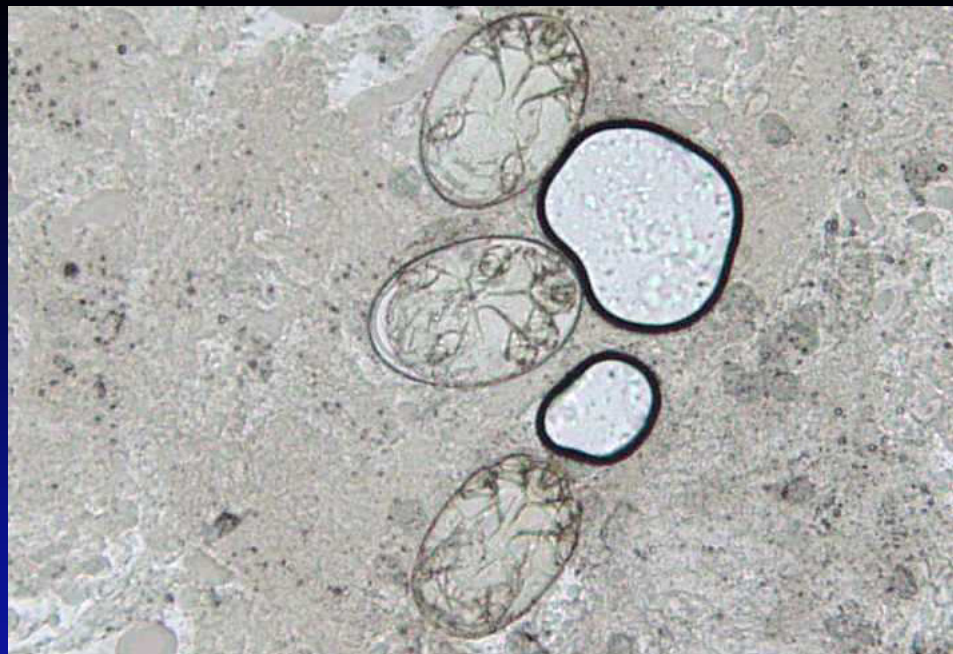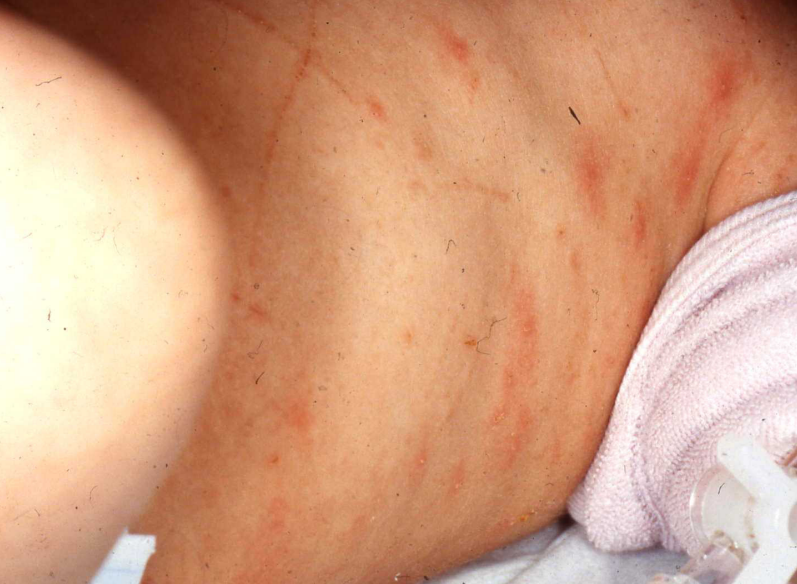# Scabies



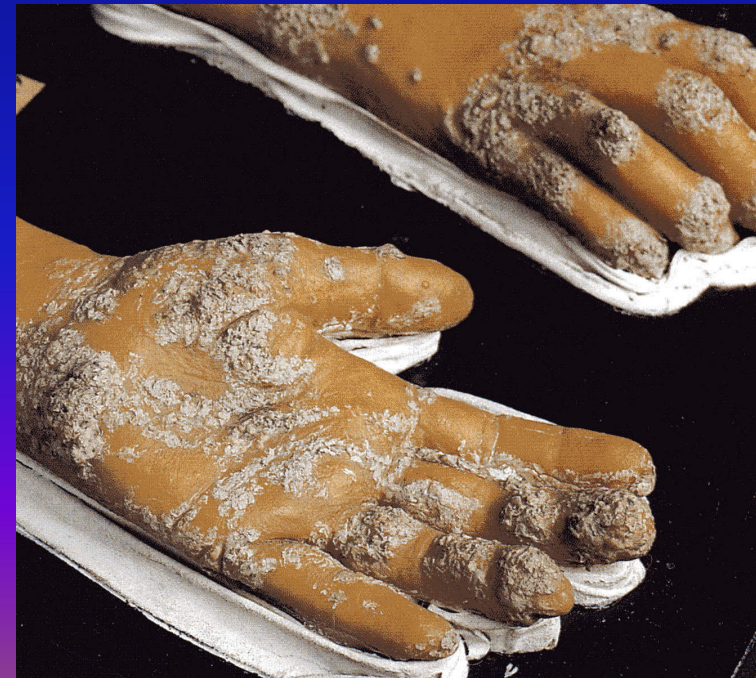
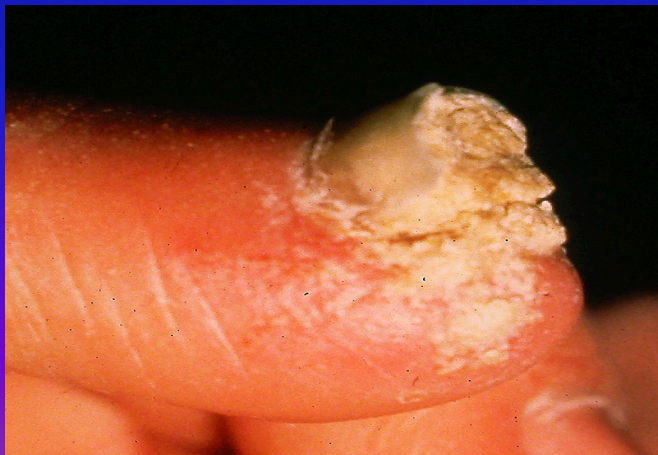
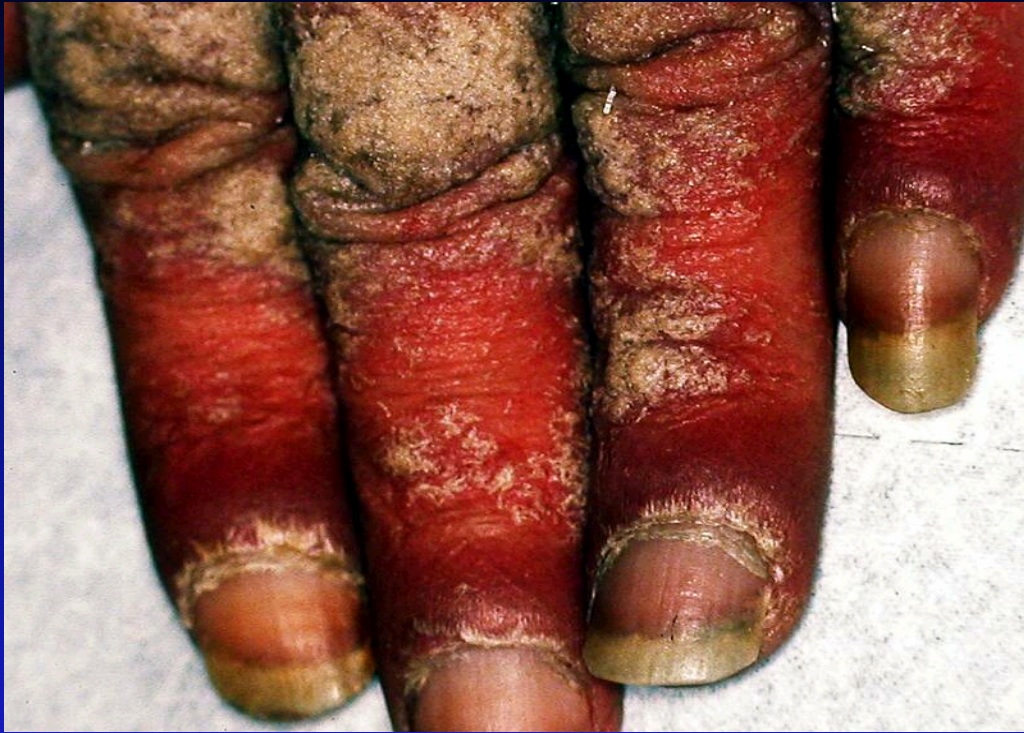

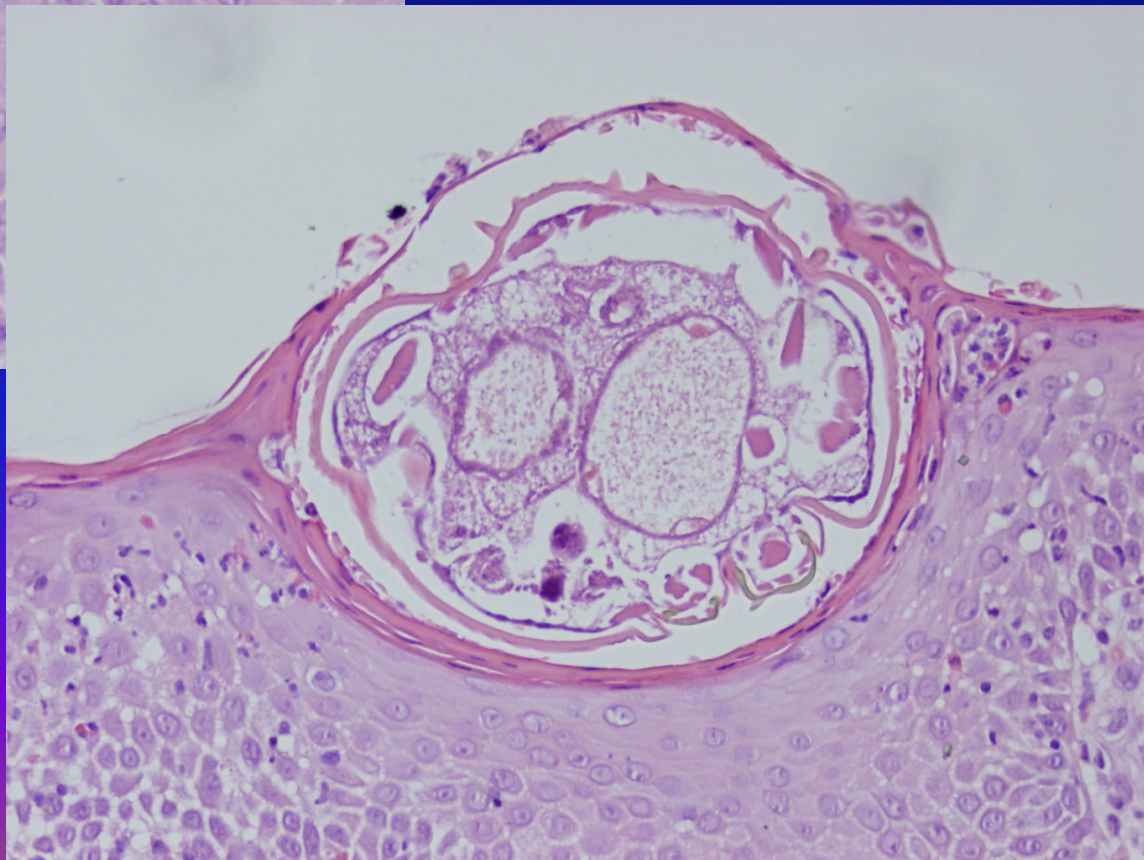
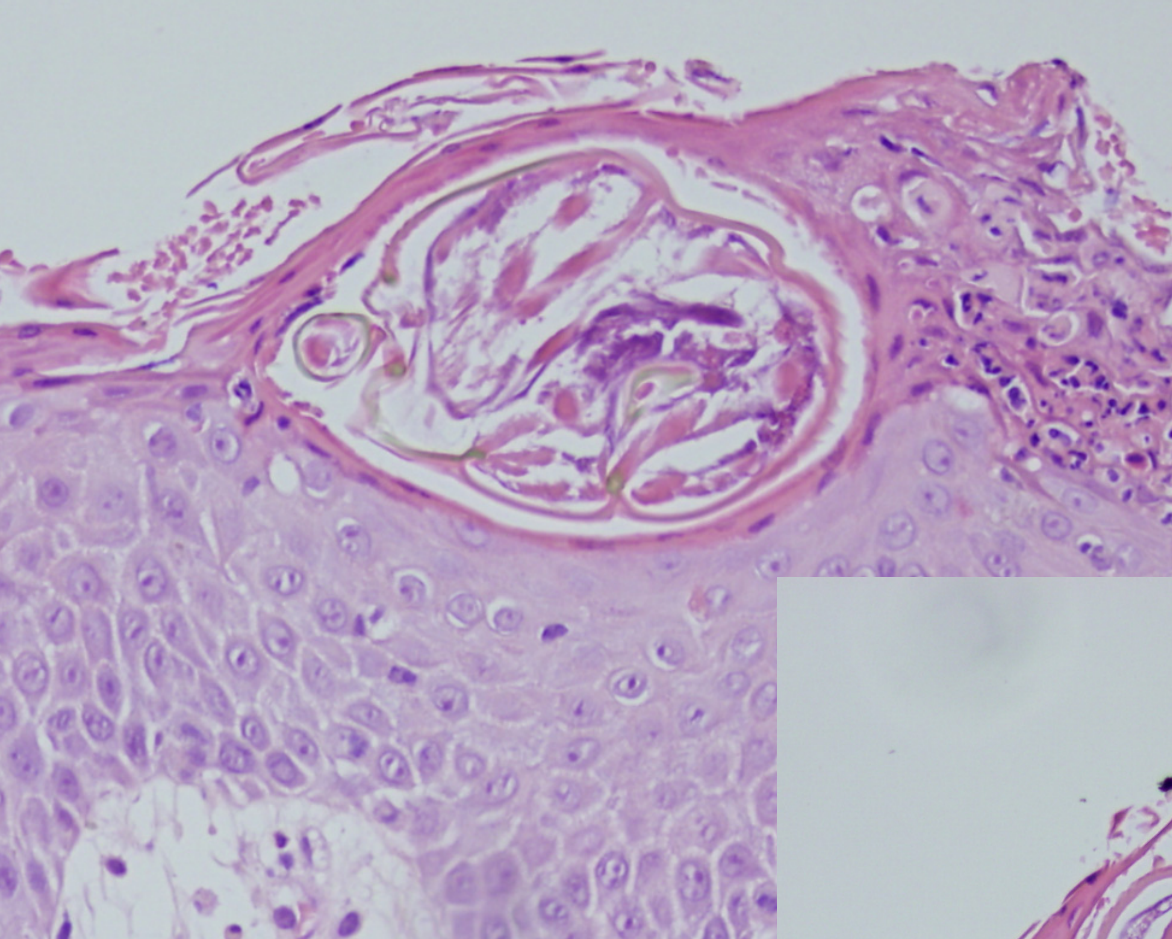







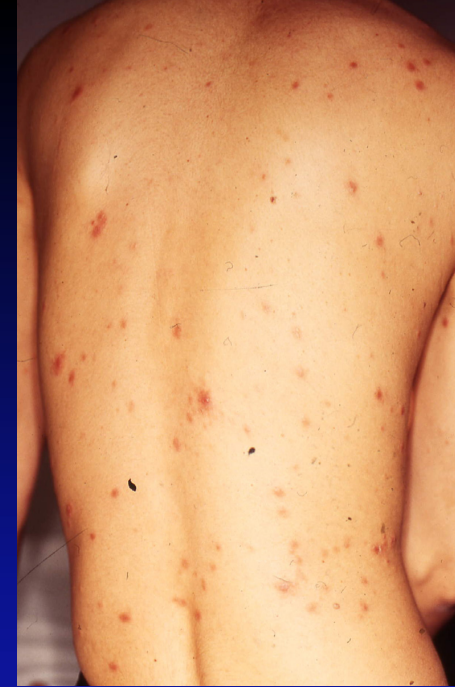
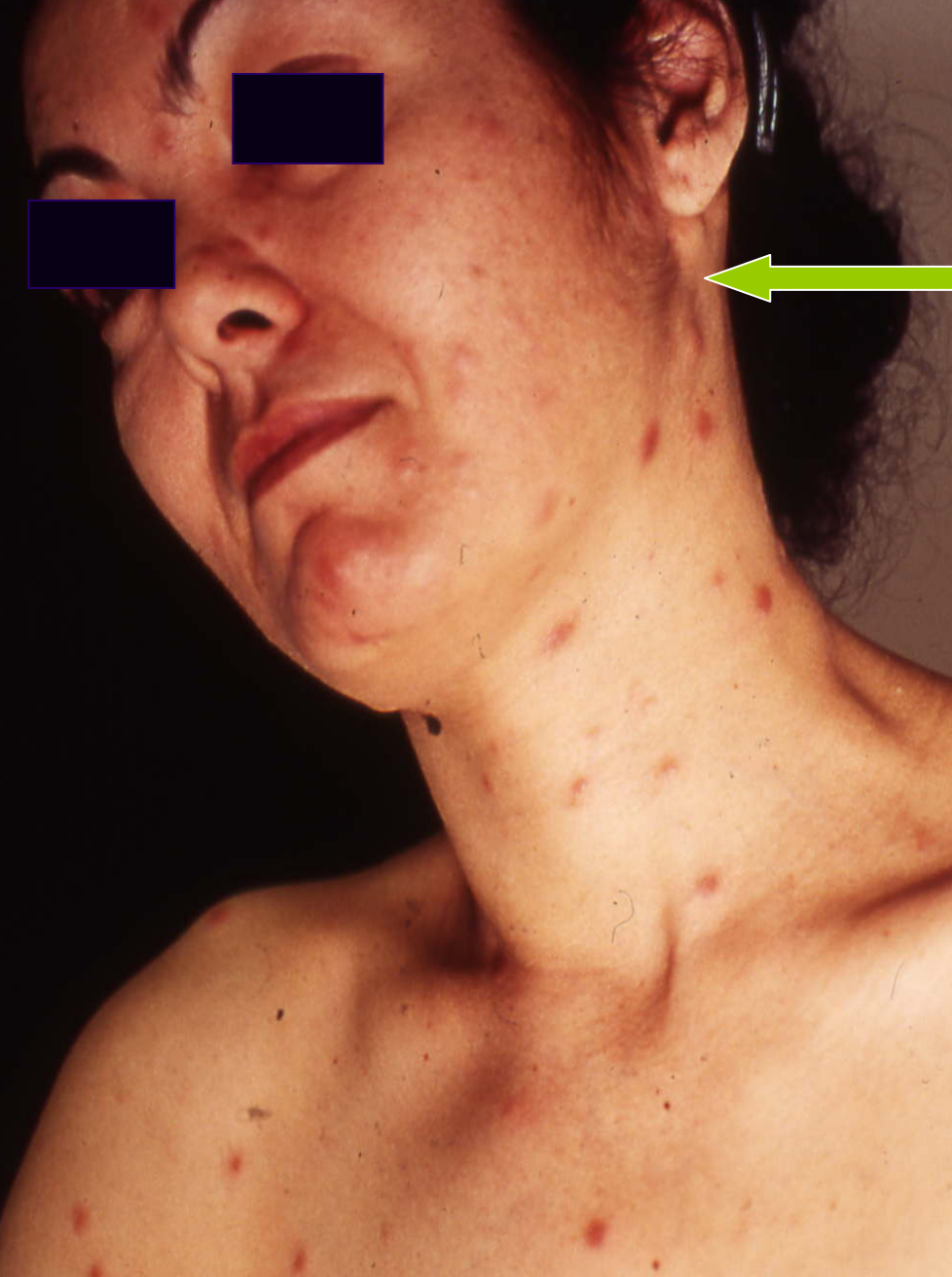

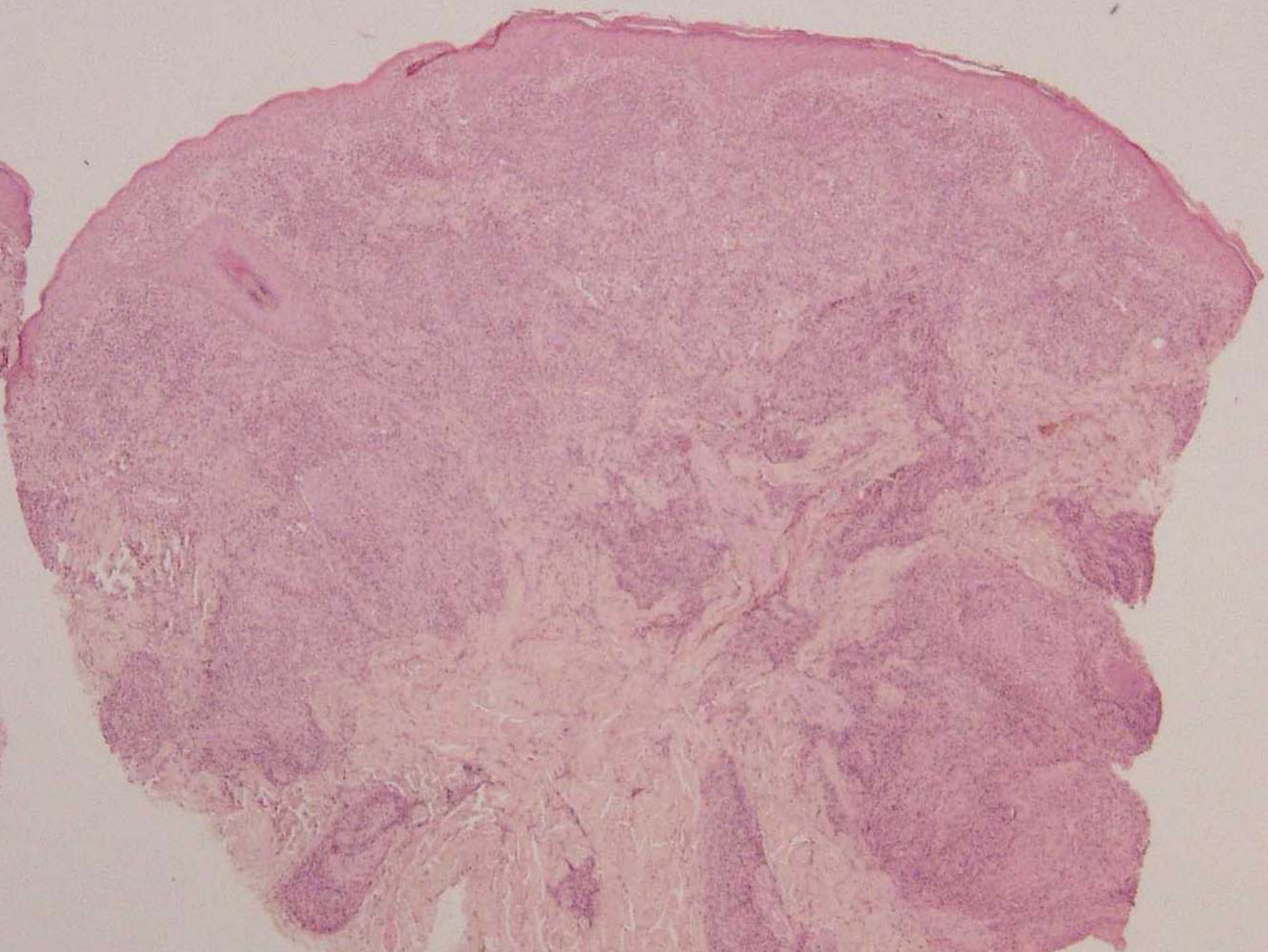




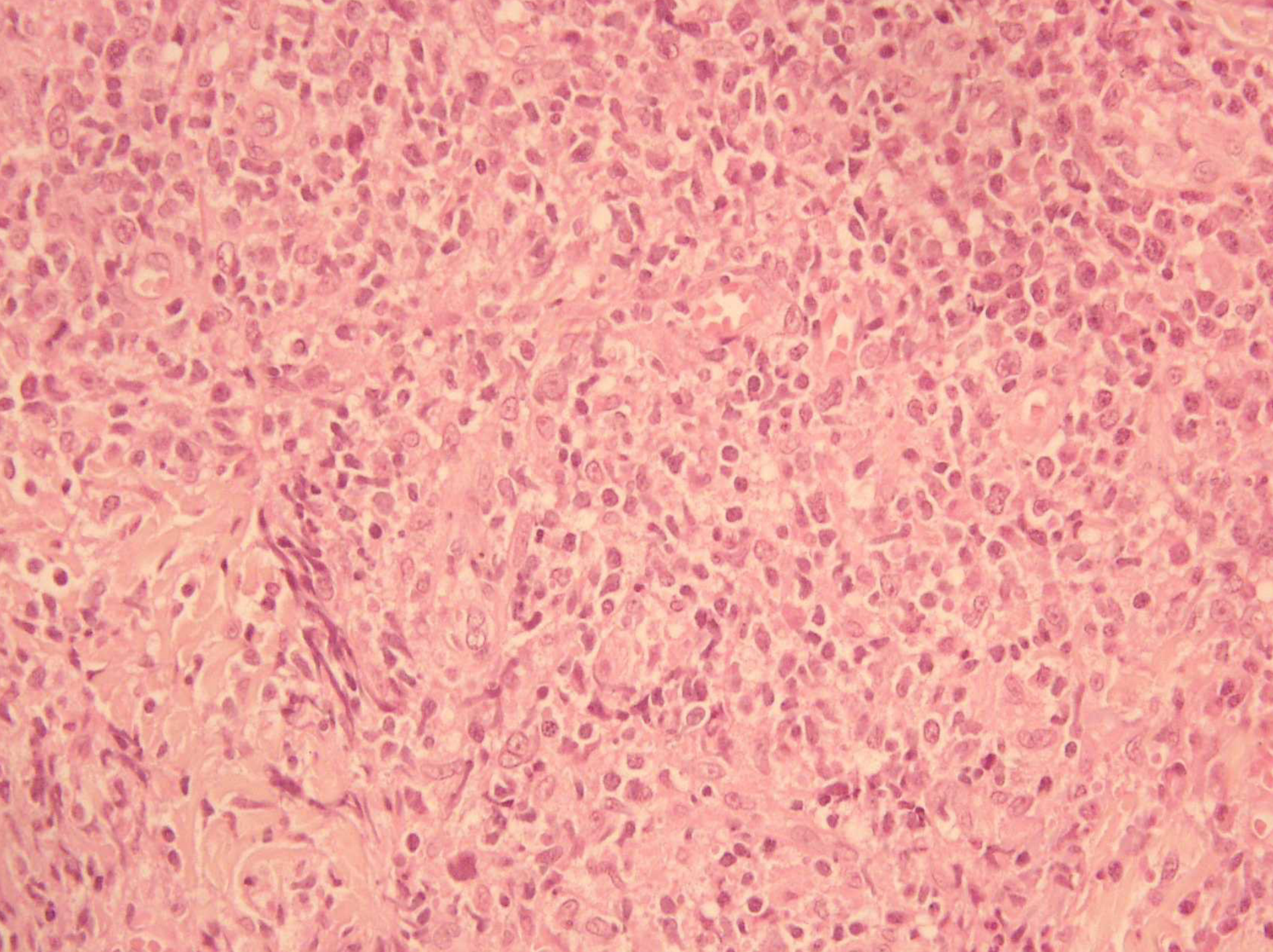


35 year-old female  
Maculo-papular eruption  
Weakness + weight loss  
Adenopathy

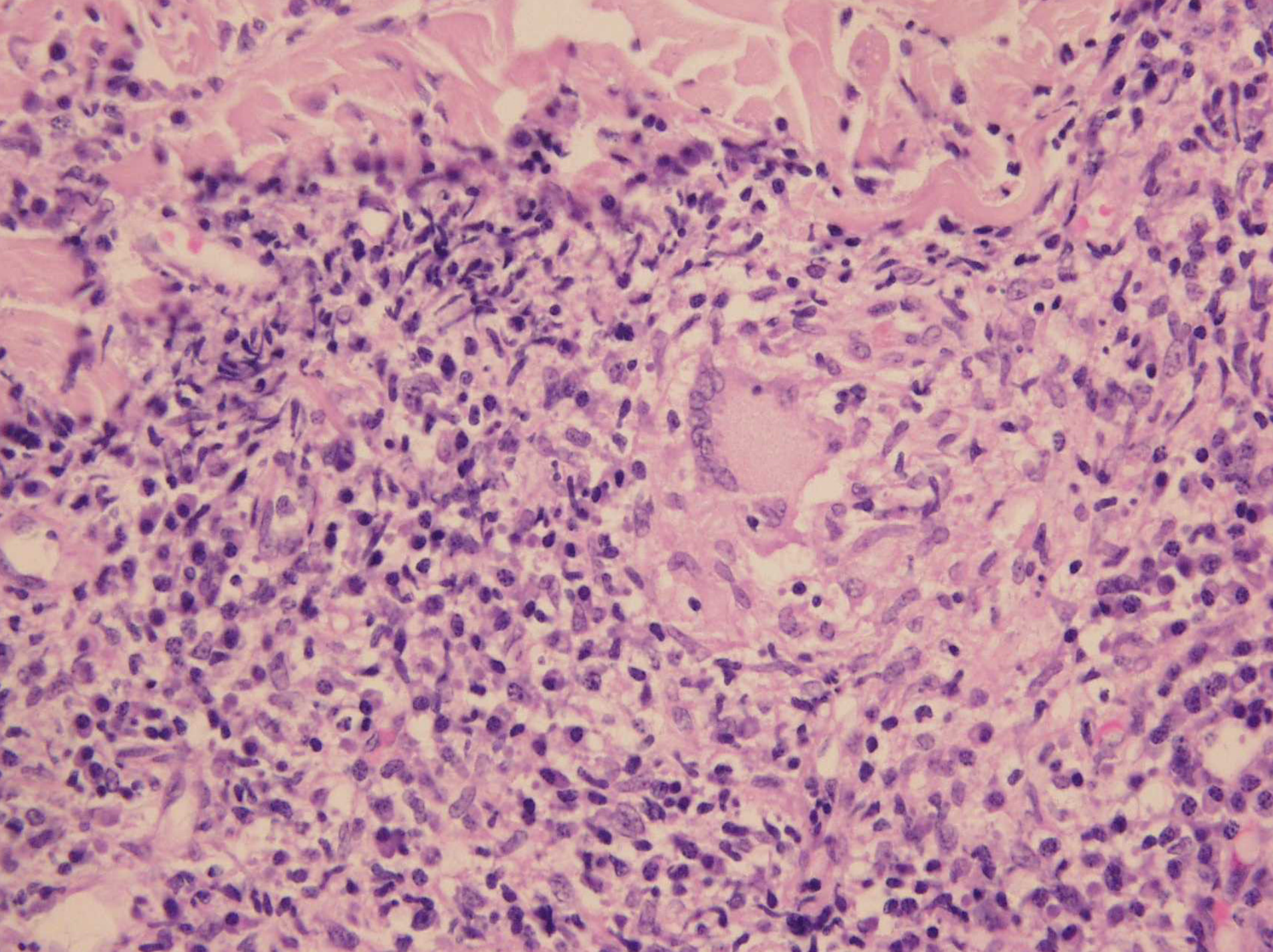




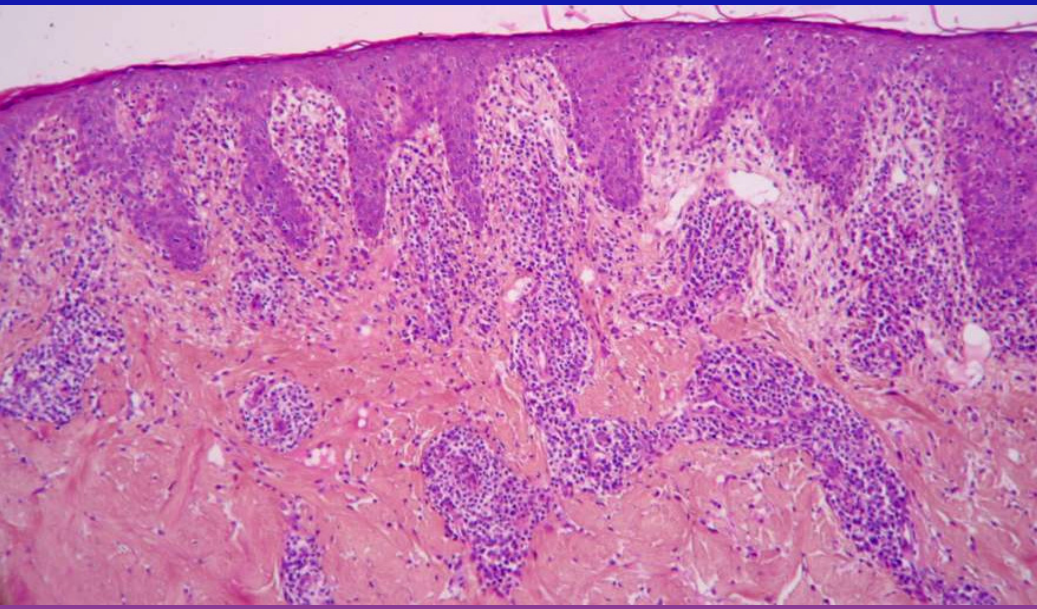
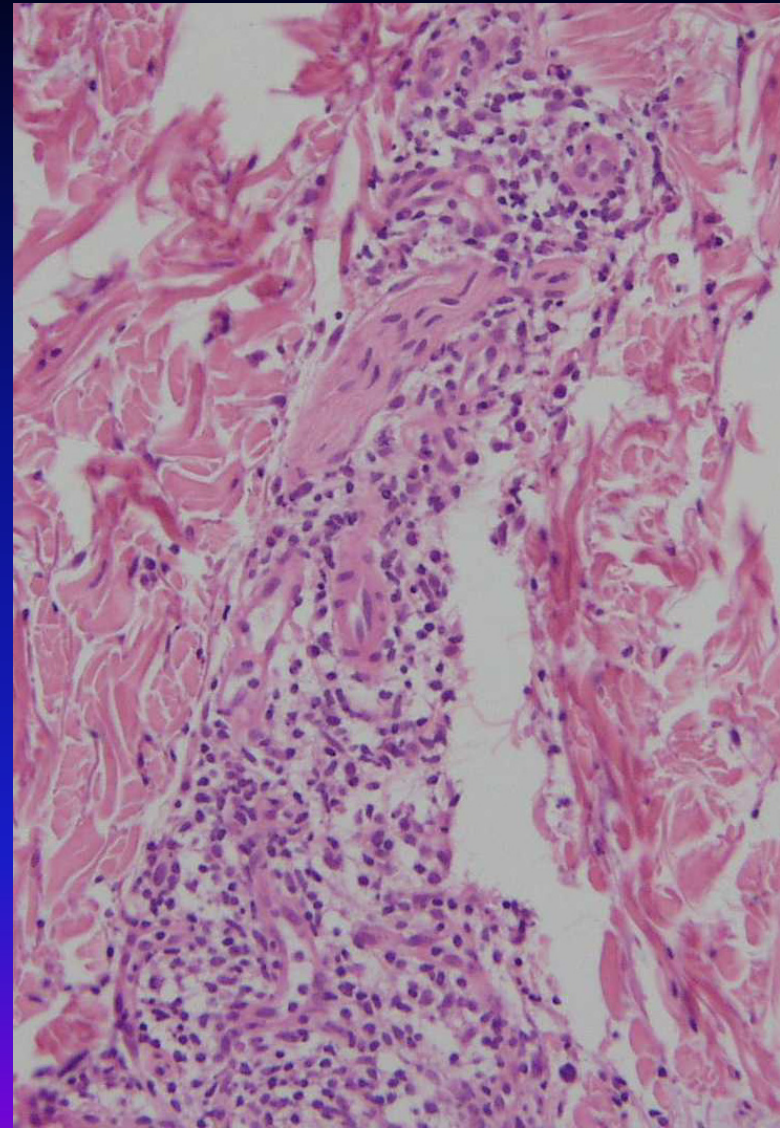
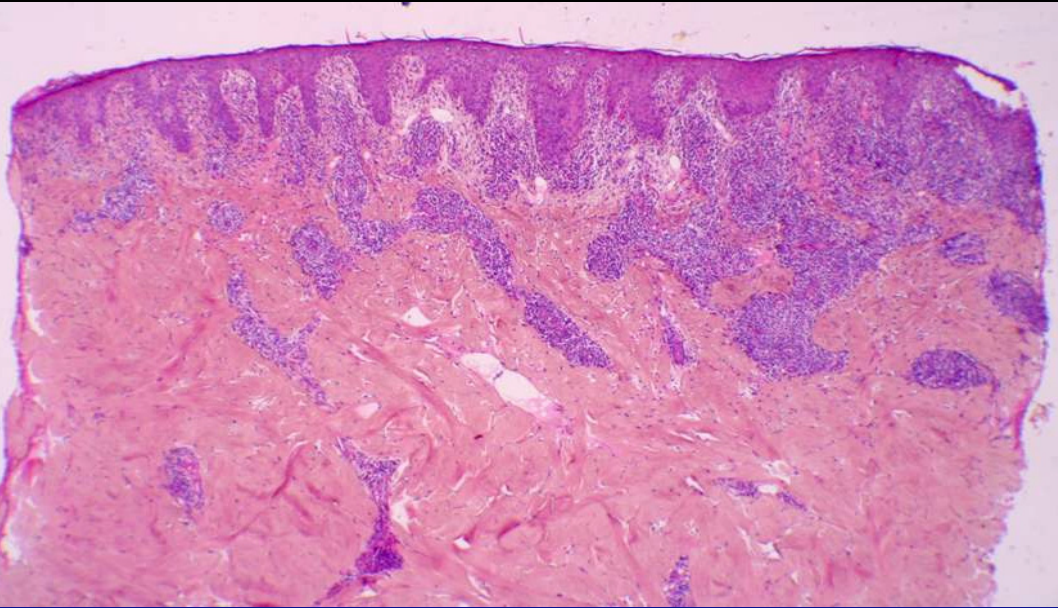






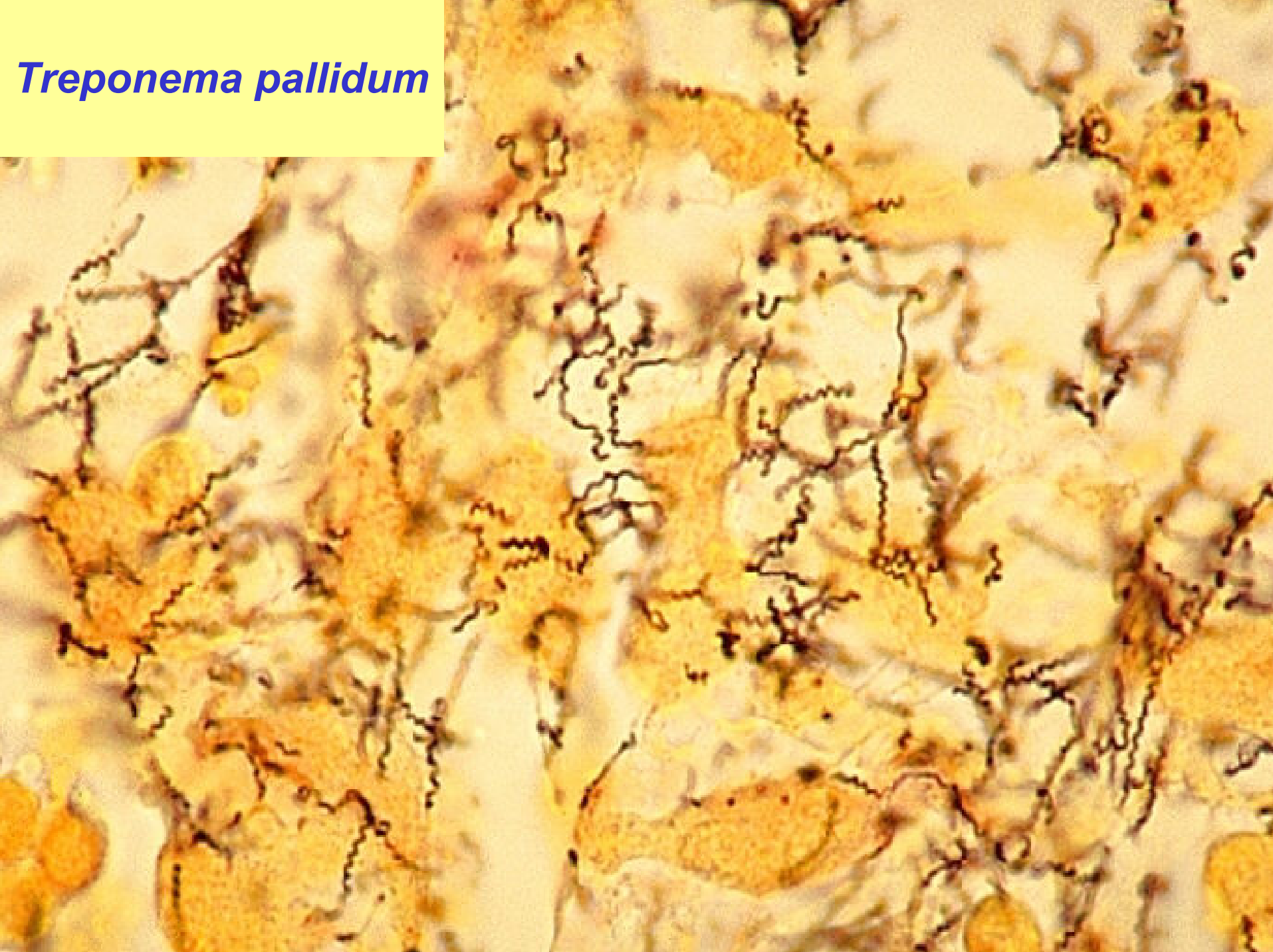






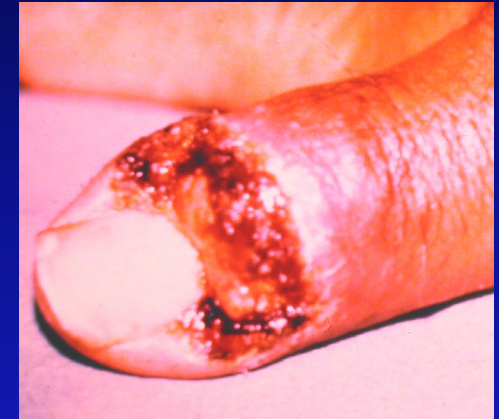
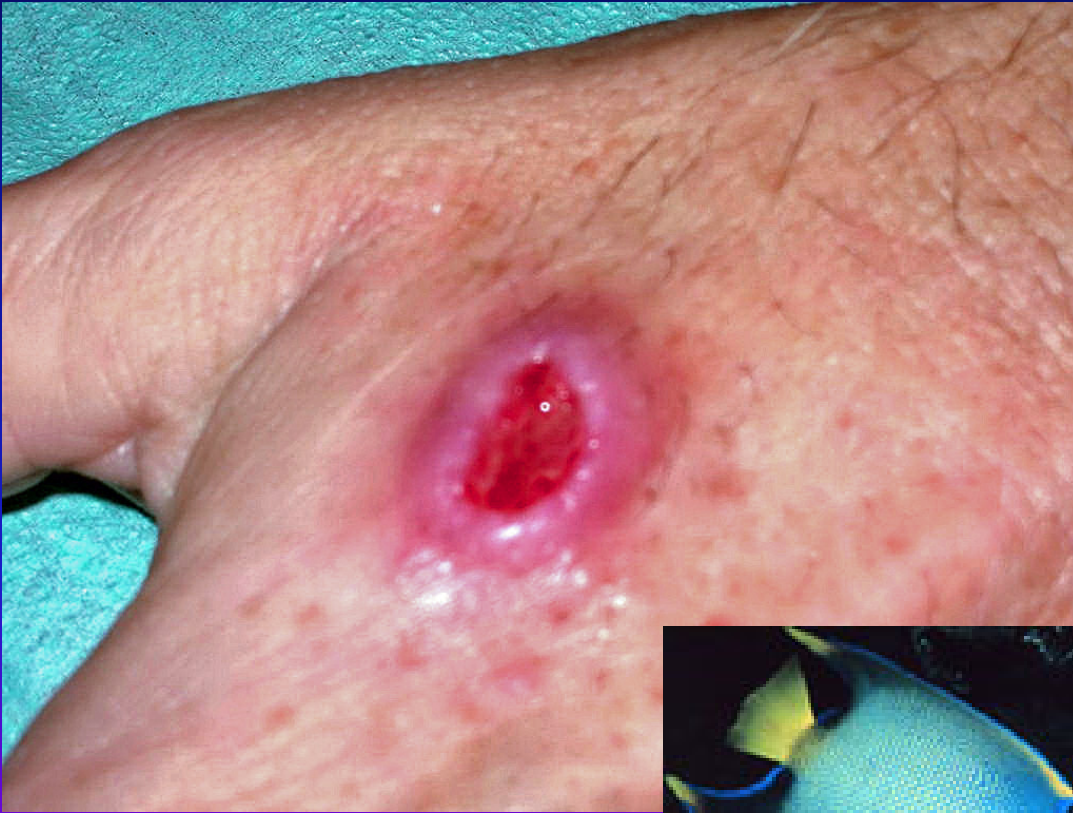
*Treponema pallidum*





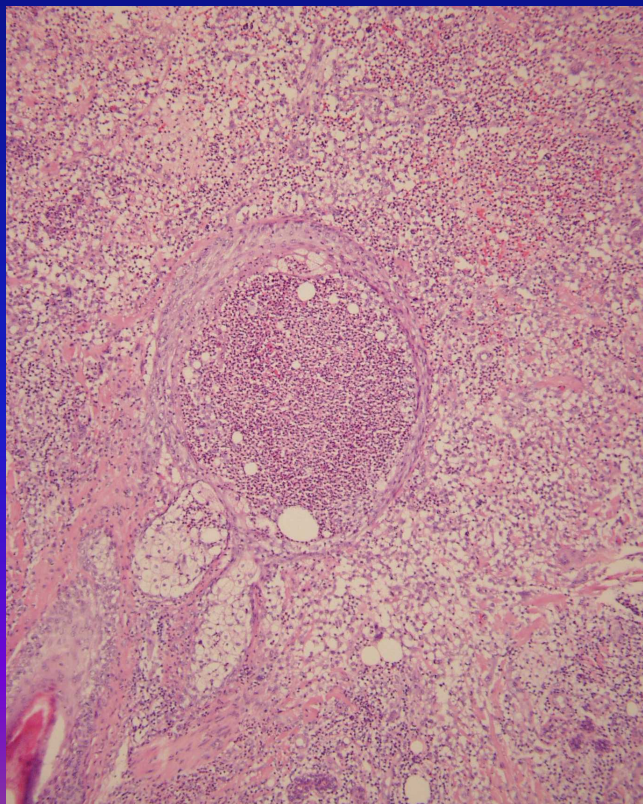
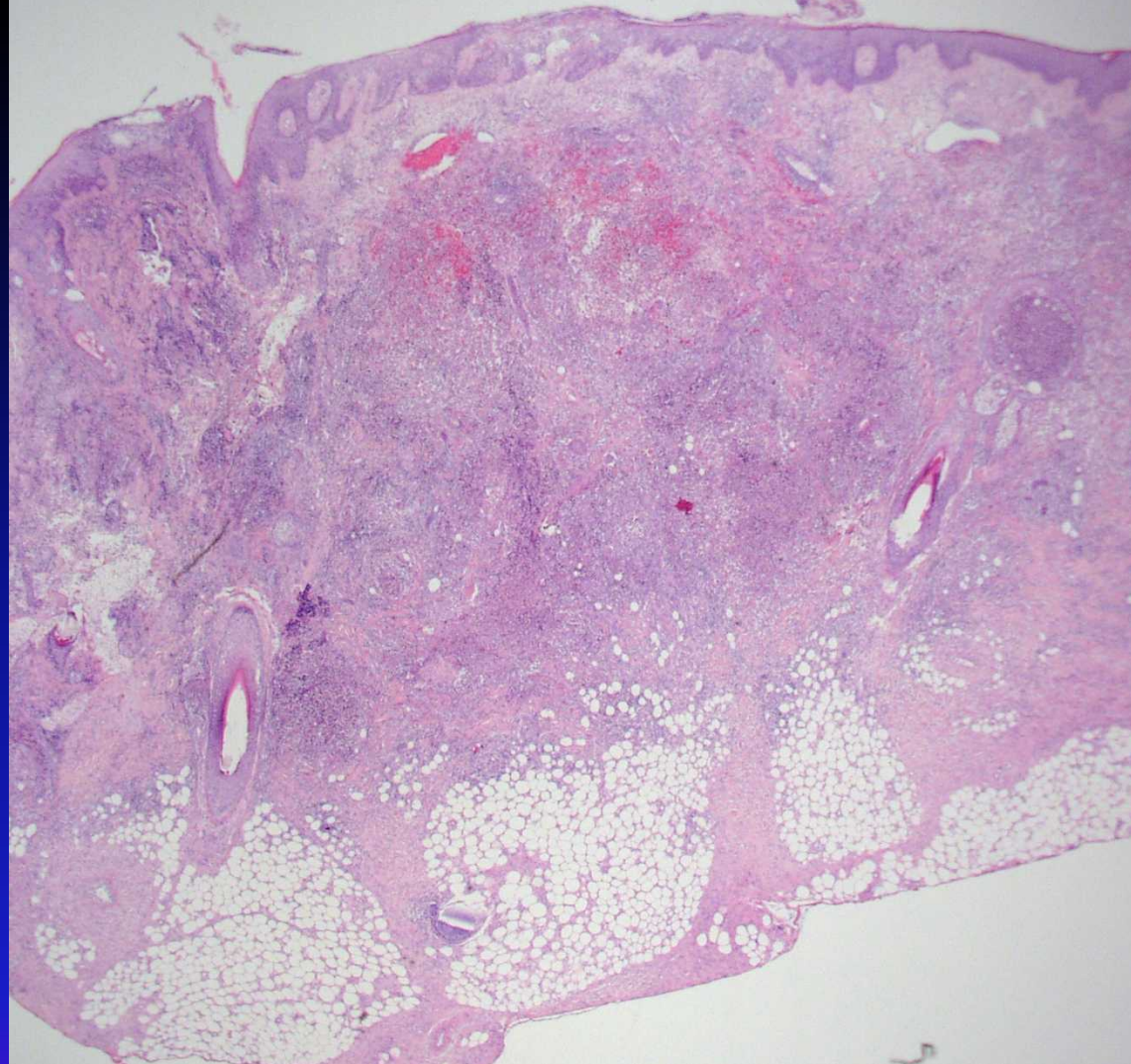
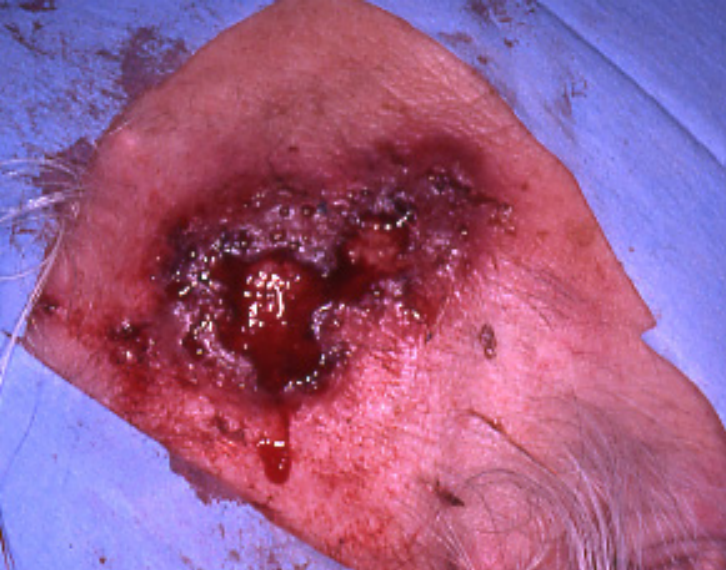# Ulcerative lesions



↑ Coll C. Arroyo,  
Columbia



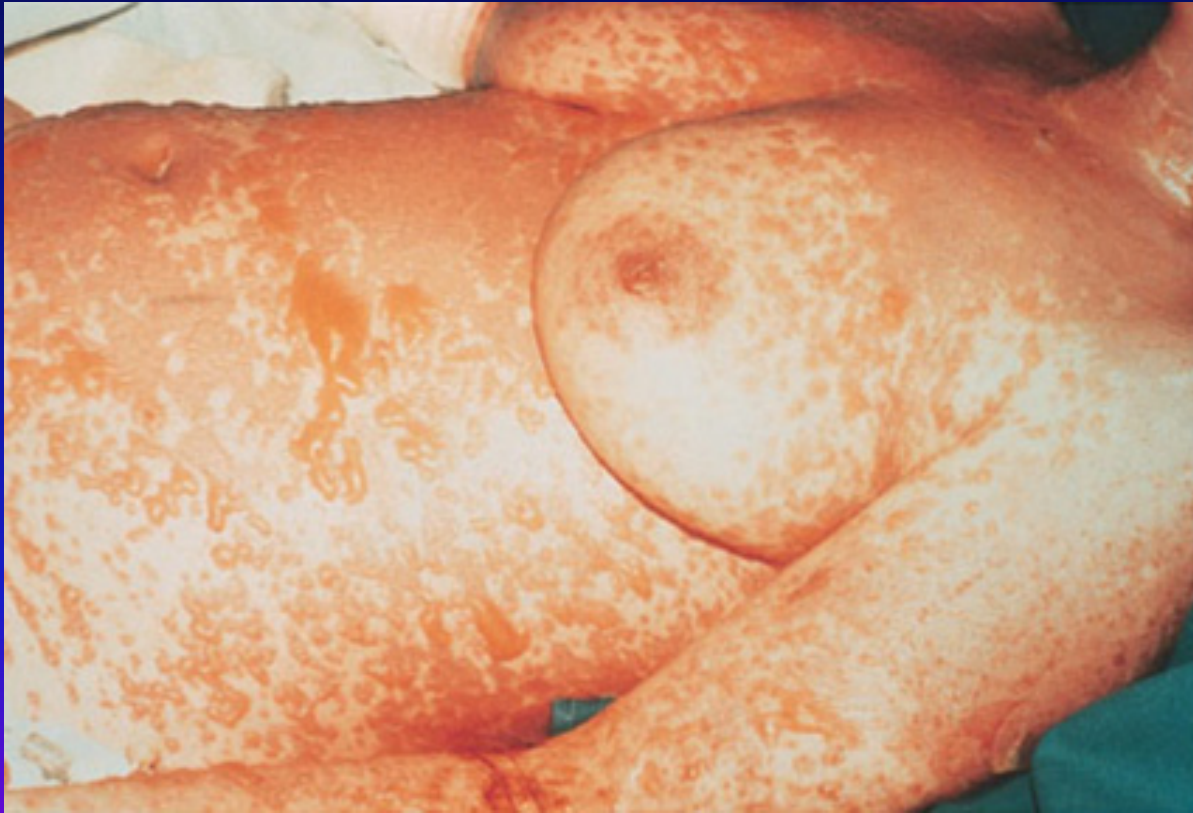



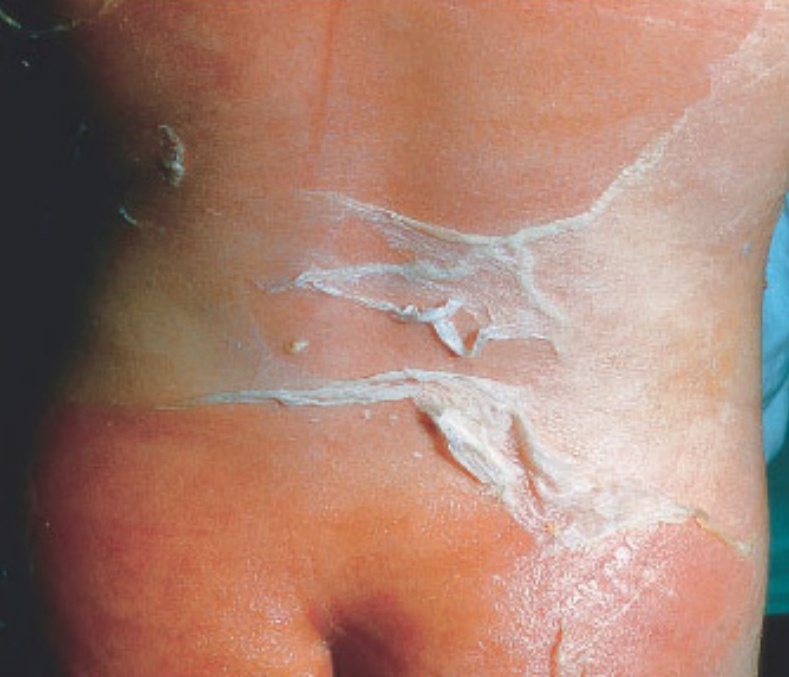**Pyoderma gangrenosum**



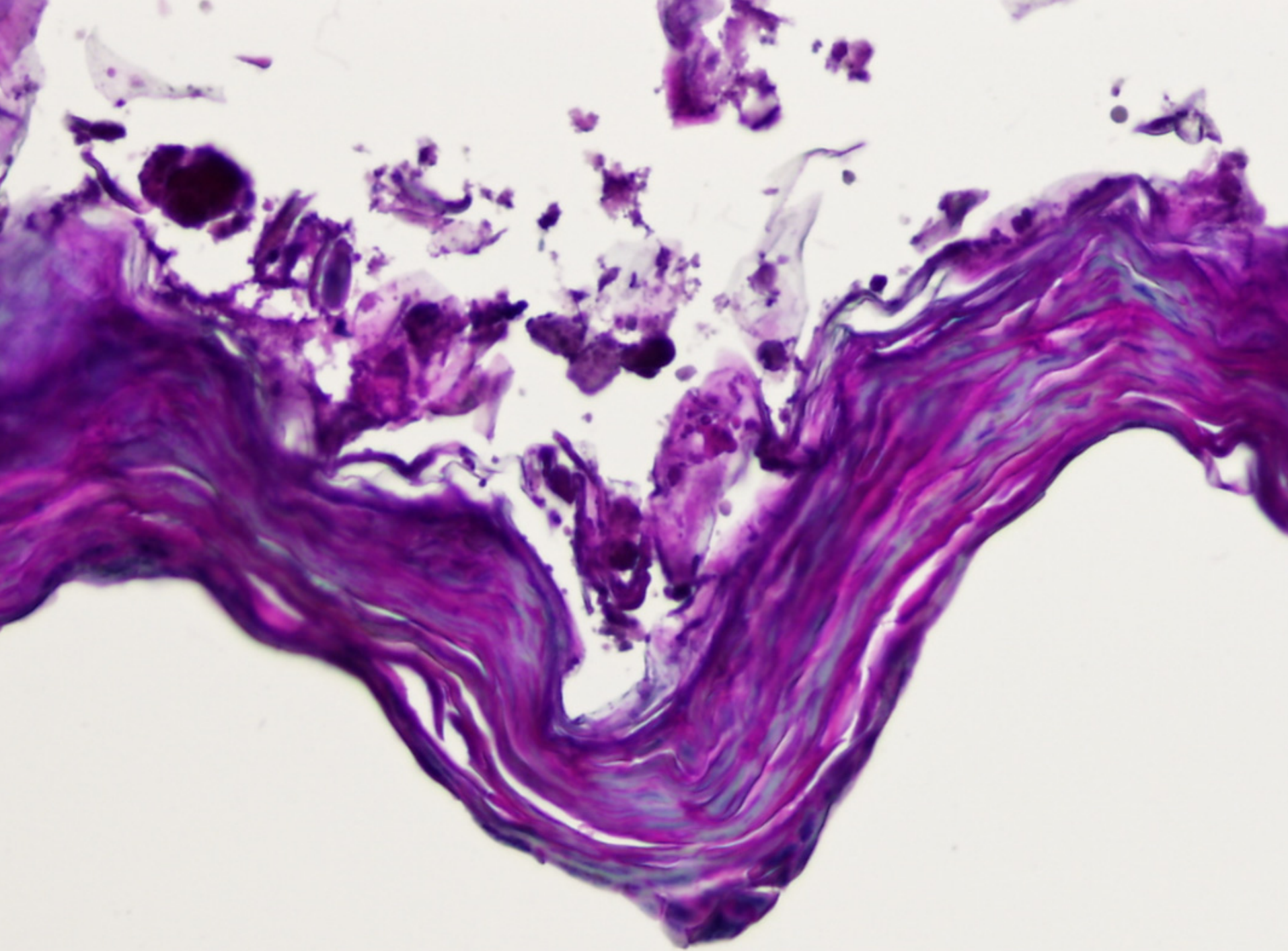
# Blistering Lesions



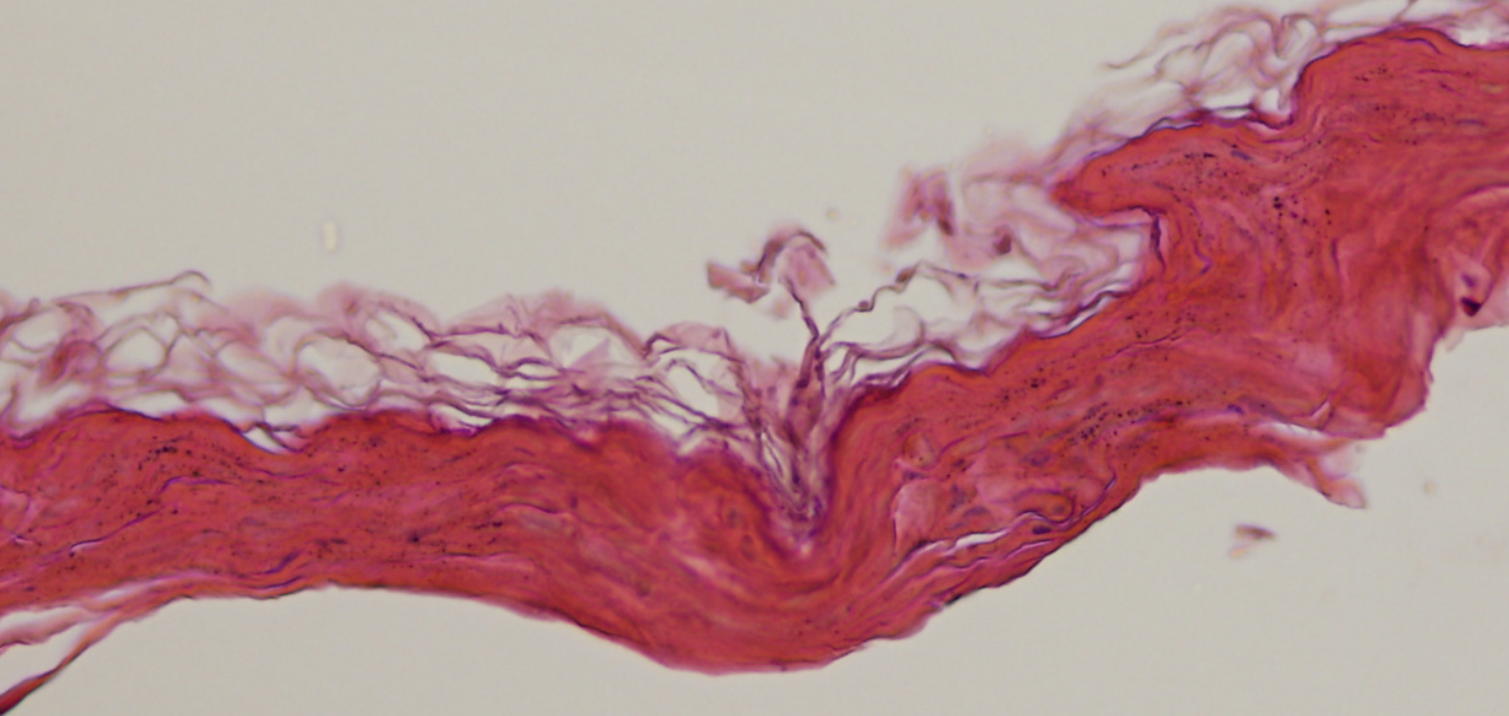




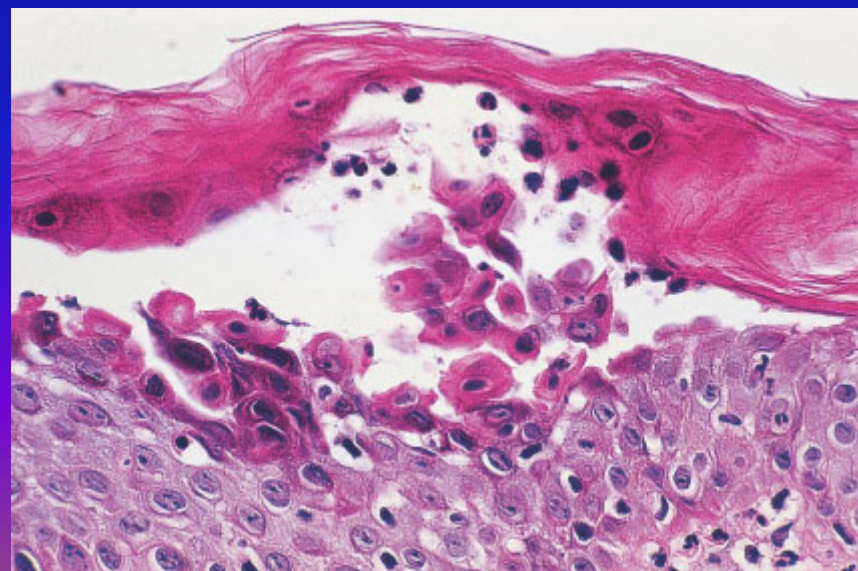




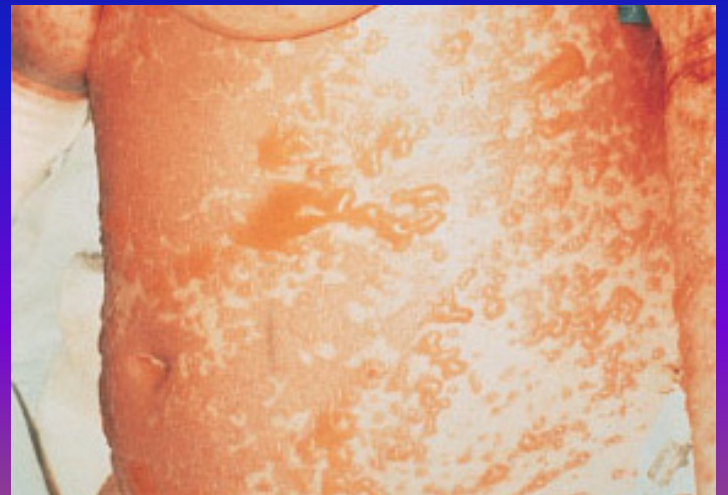
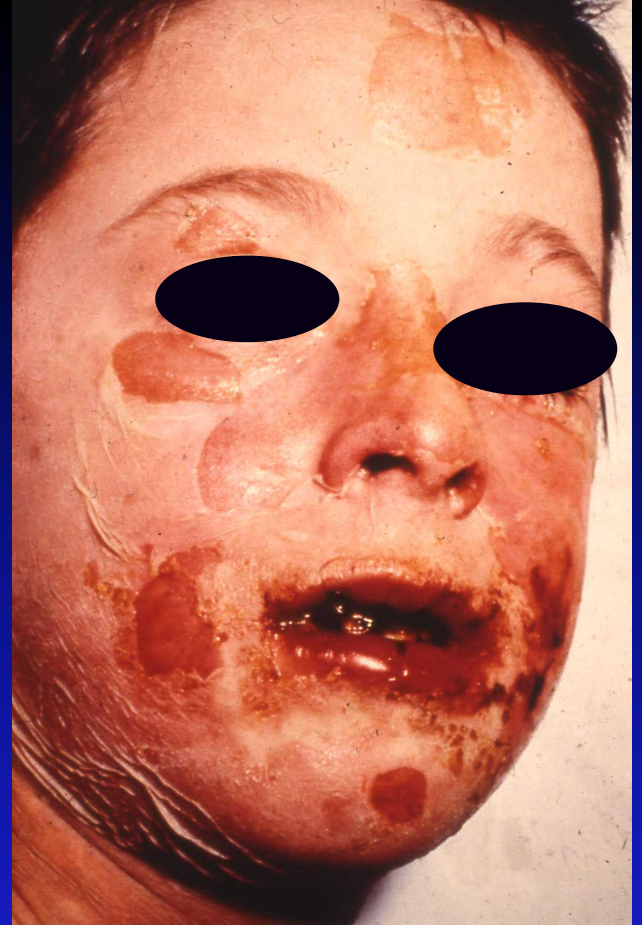
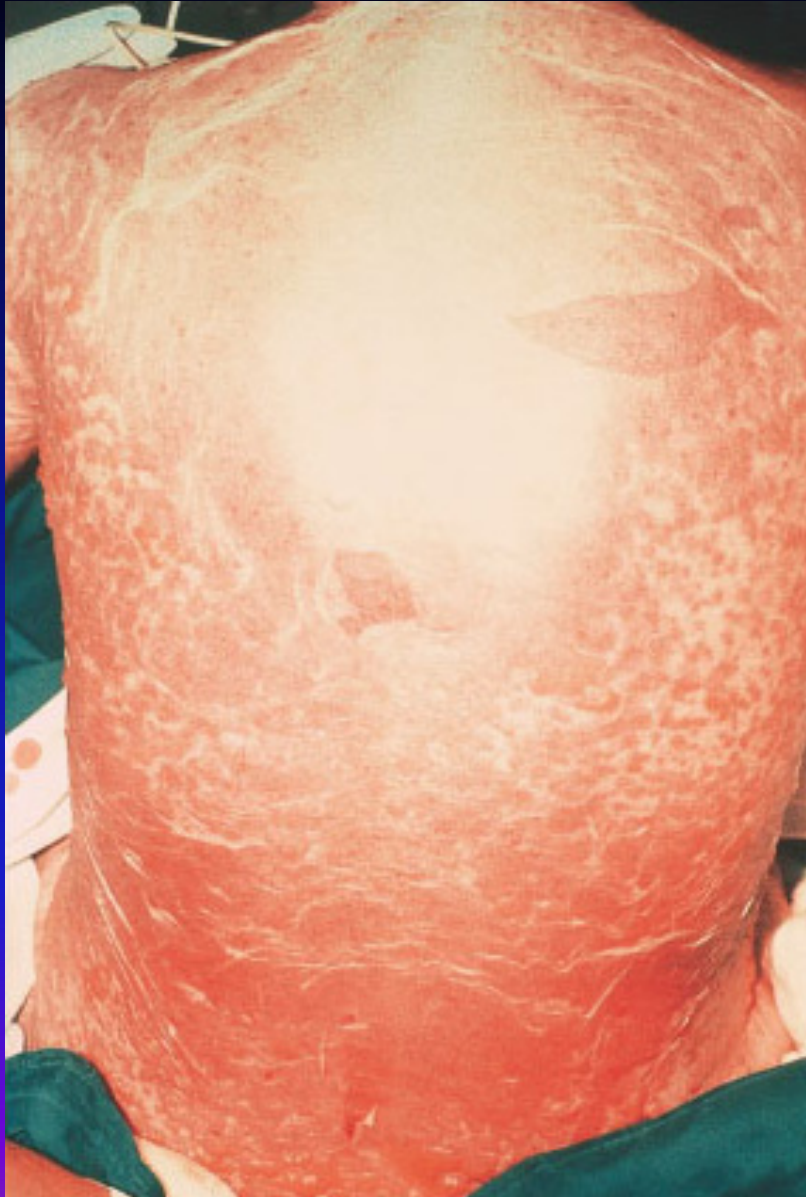

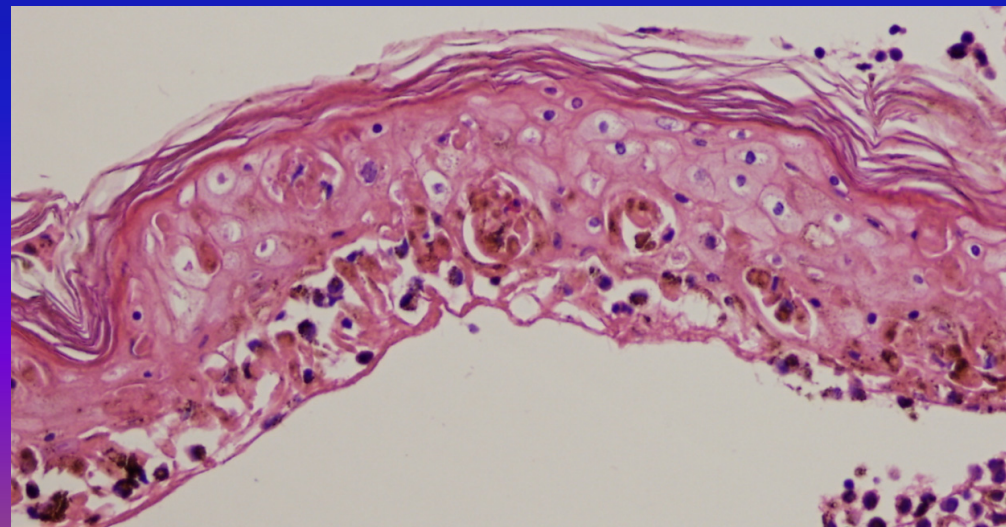
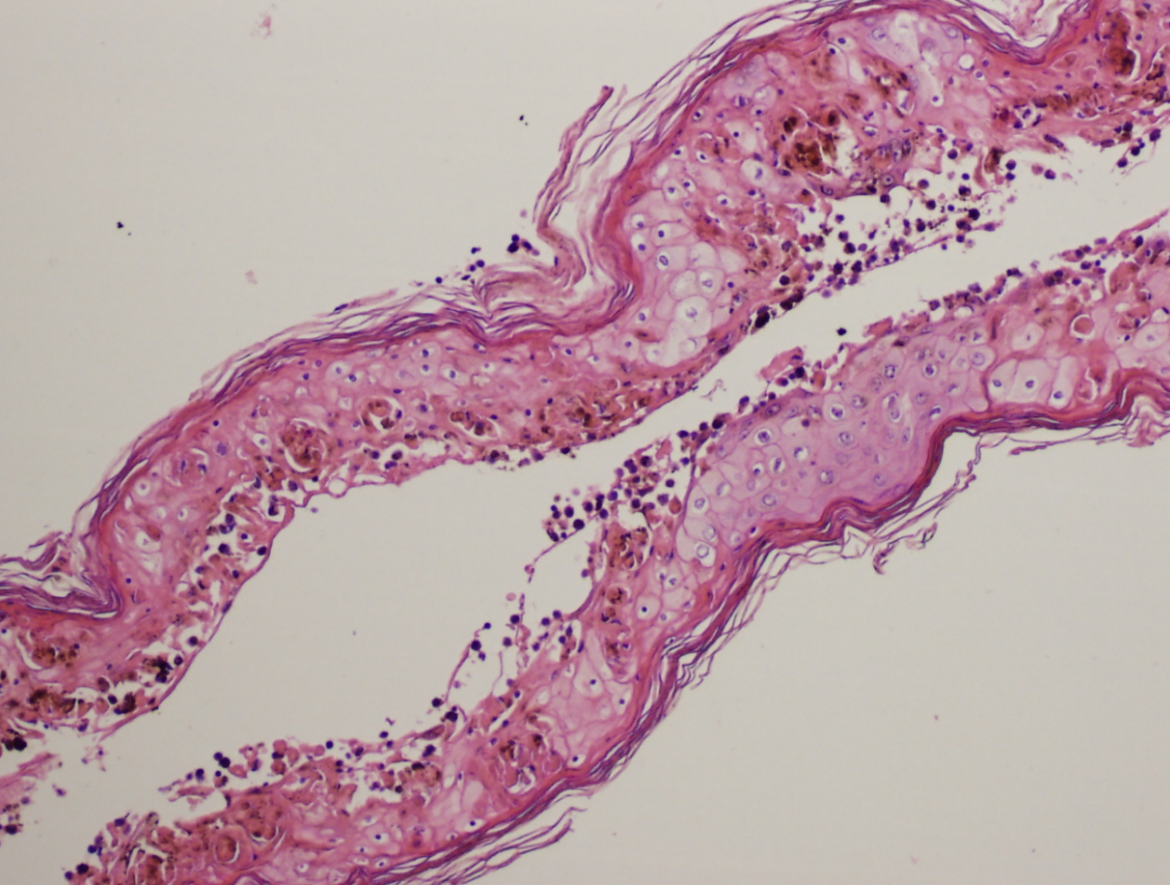
*Staphylococcus aureus*  
SSSS





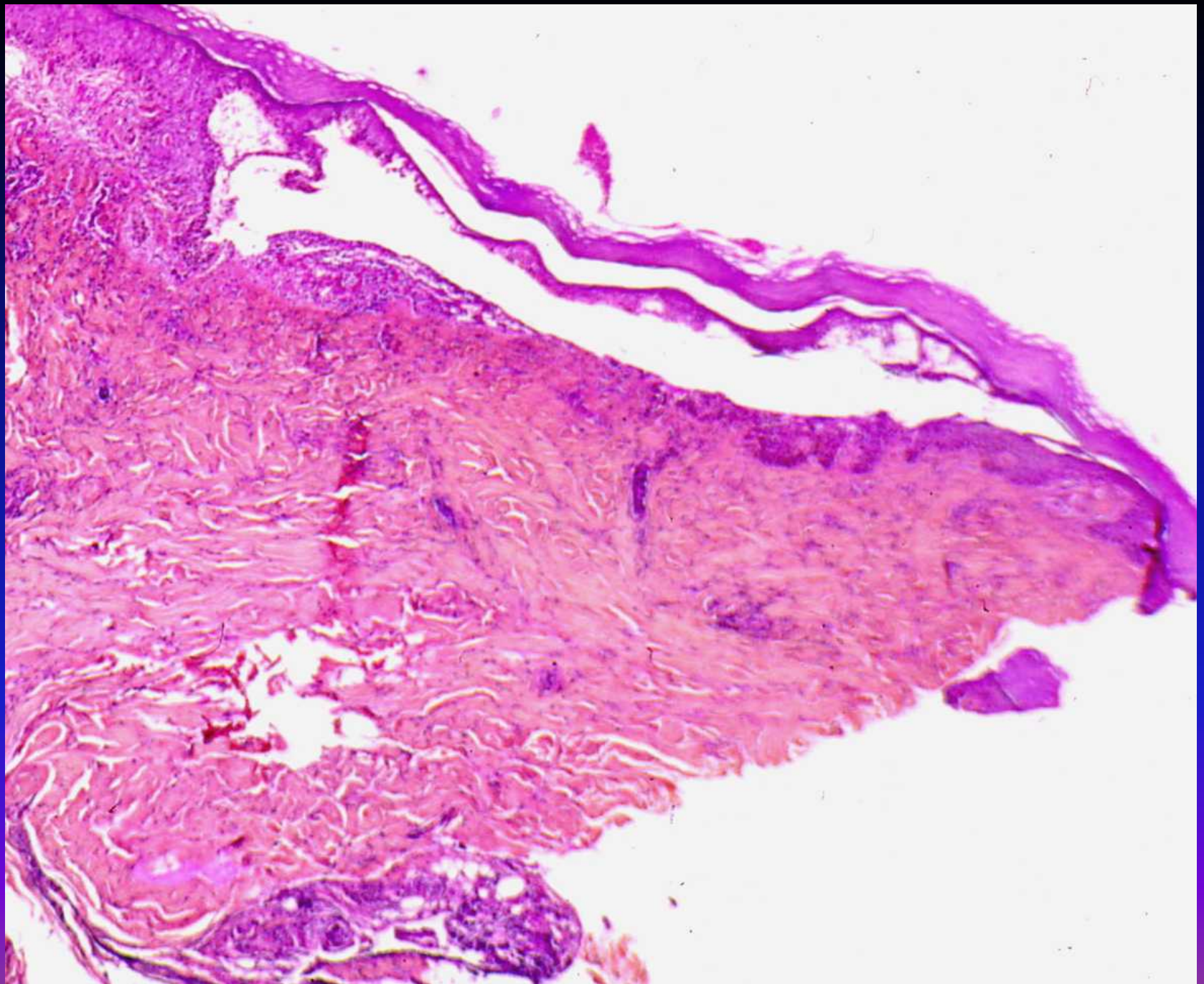






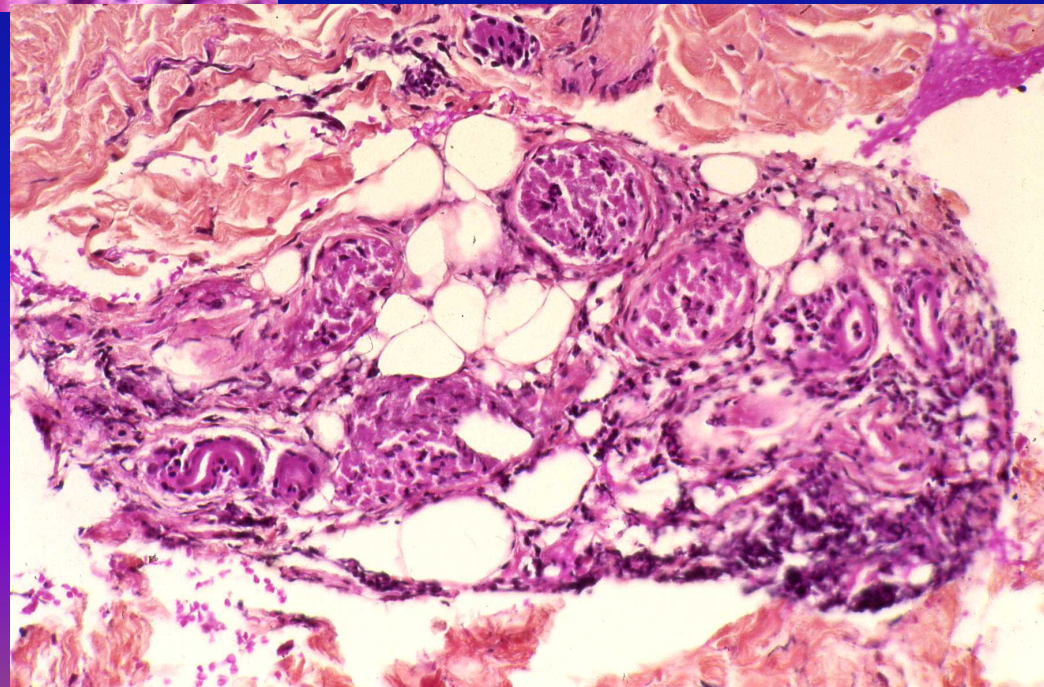
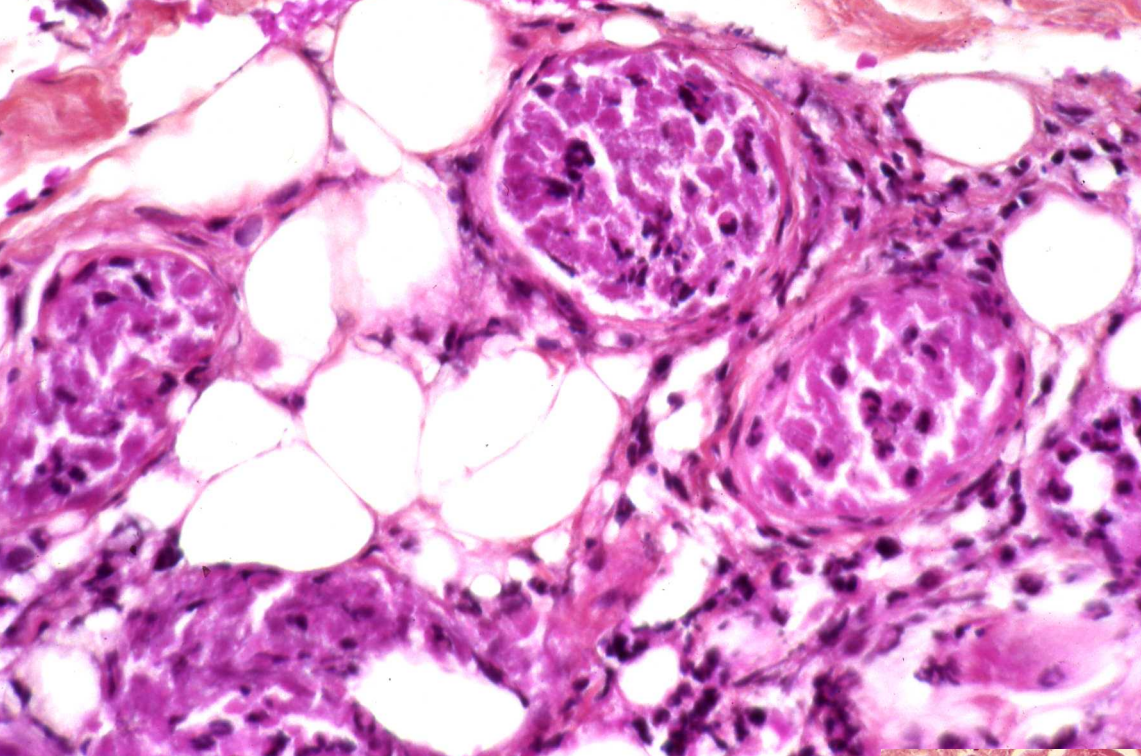
**Toxic epidermal necrolysis  
(TEN)**





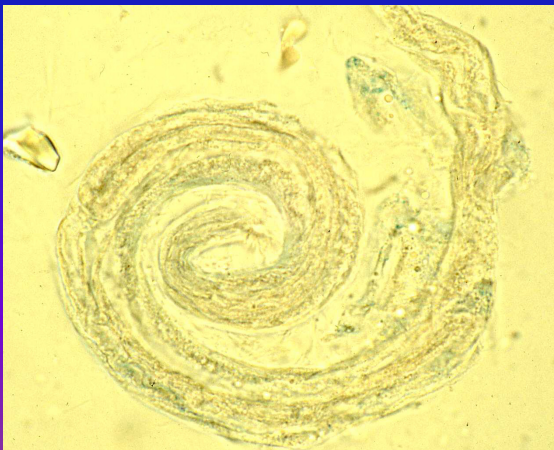
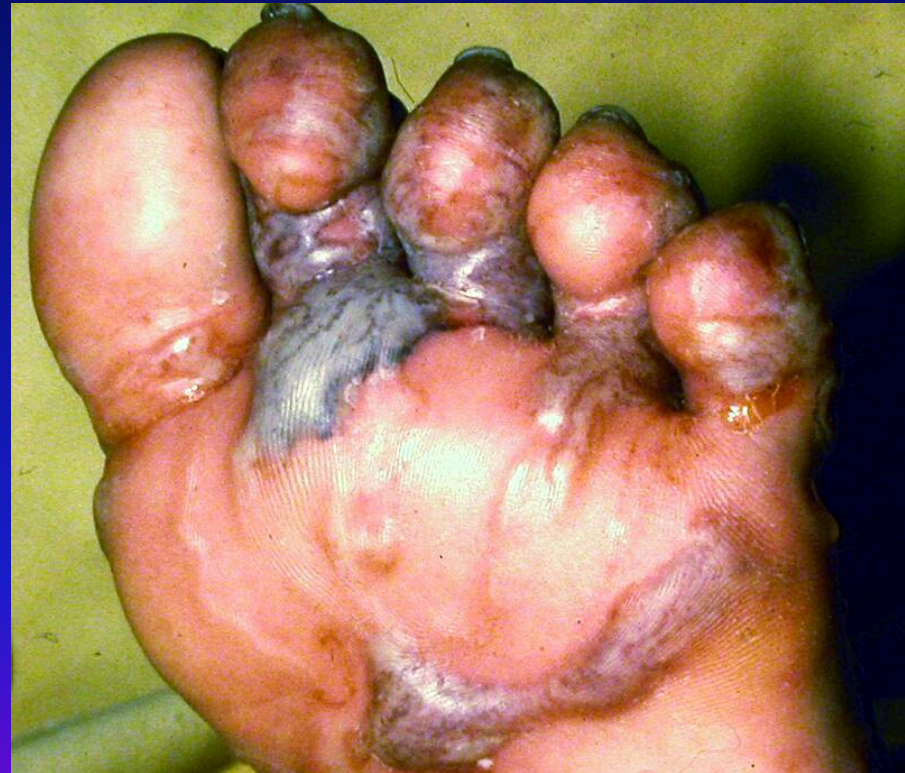
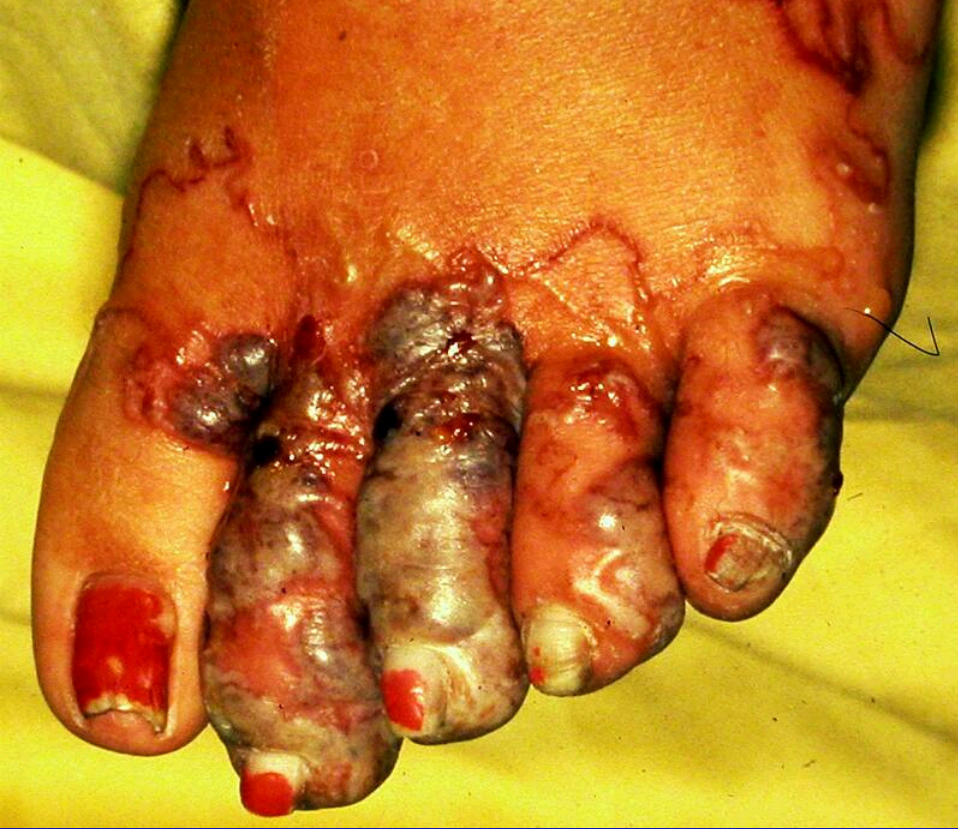
## Septic emboli





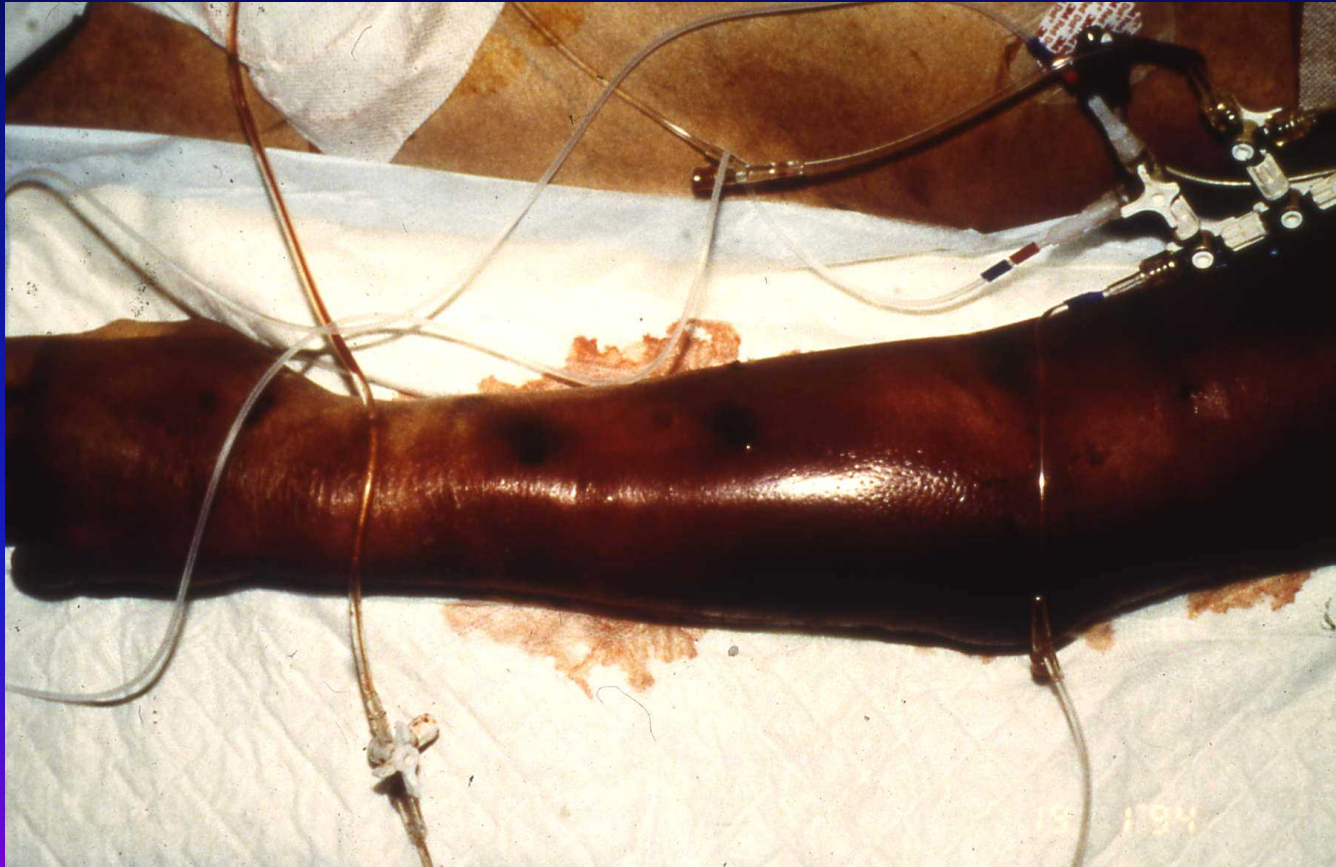
Coll Dr Keystone, Canada



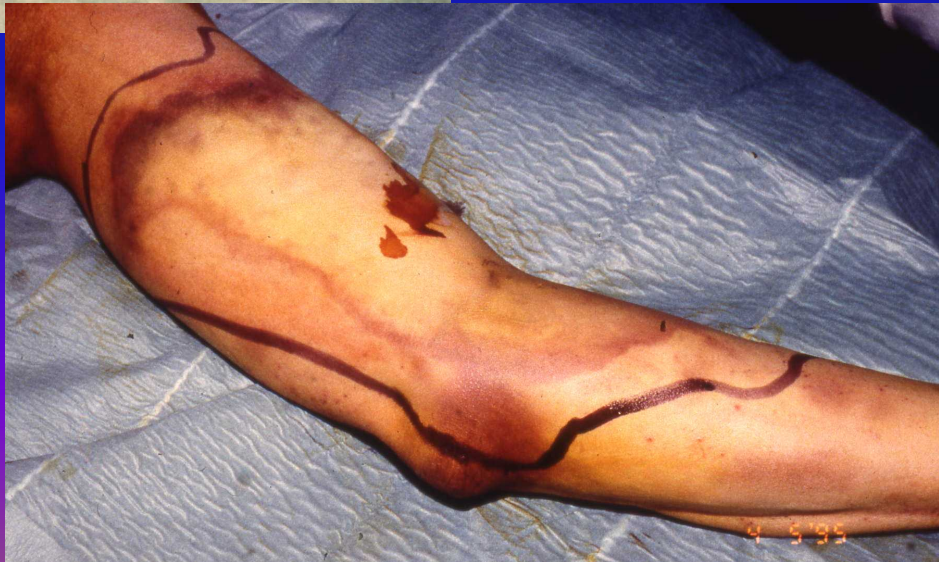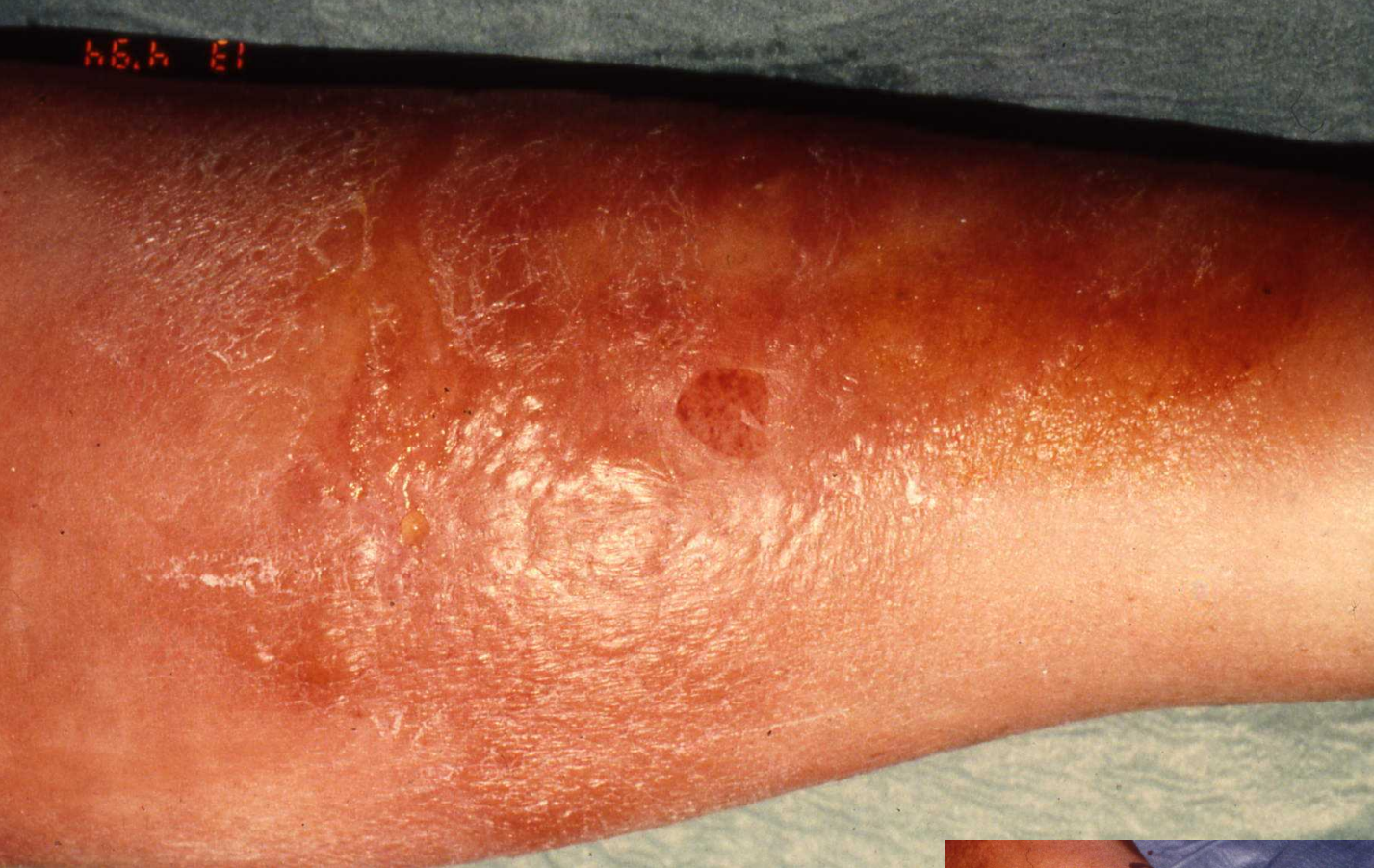**Ankylostoma (Larva migrans)**



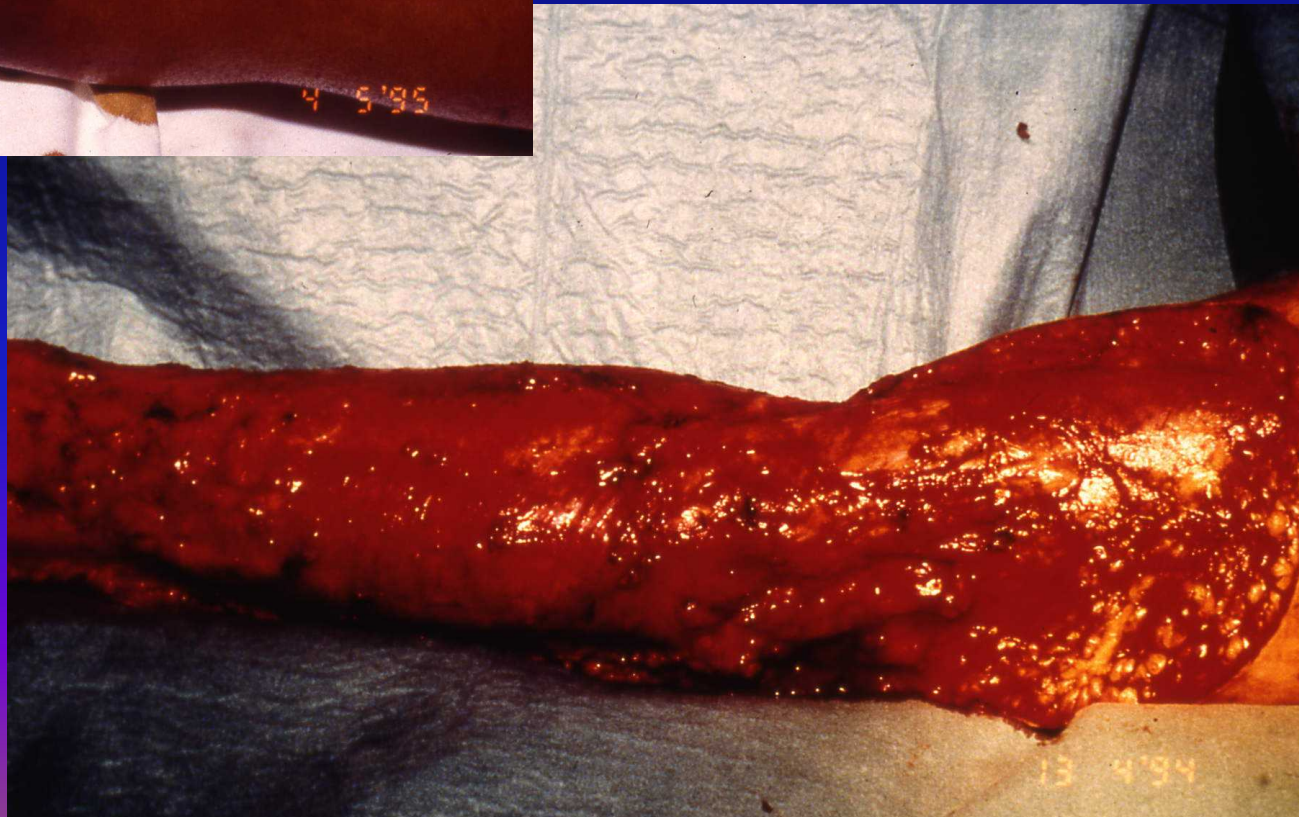
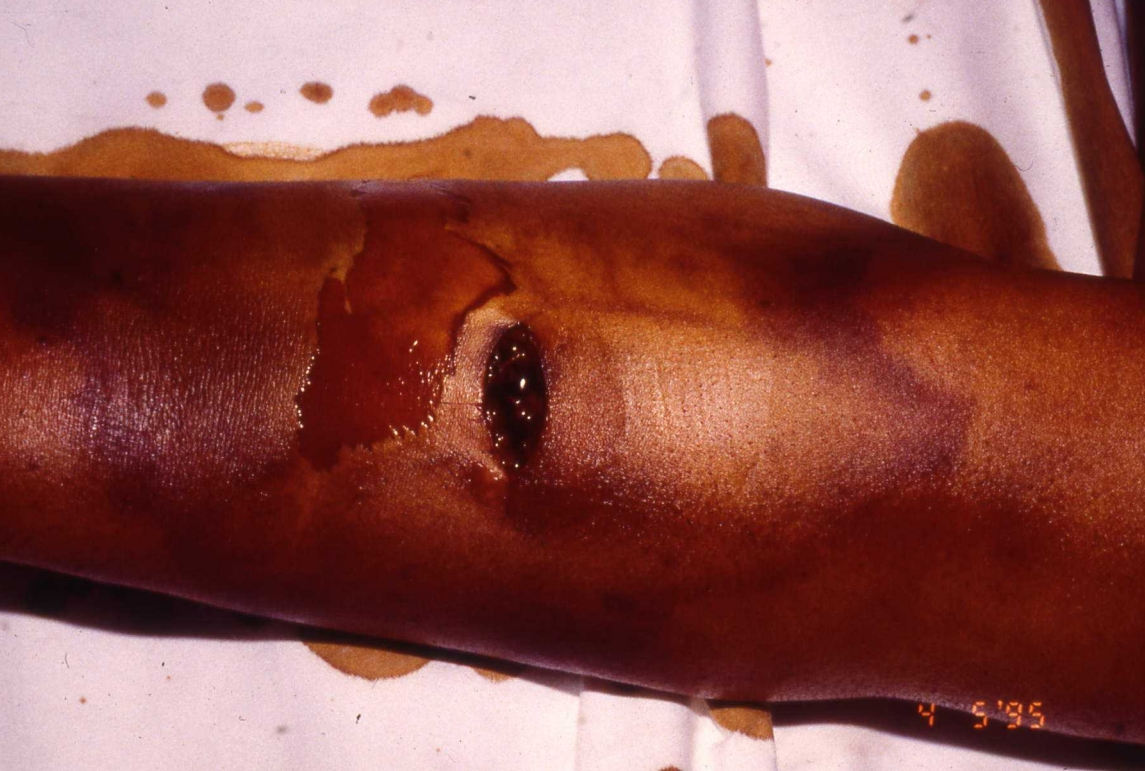# Fasciitis





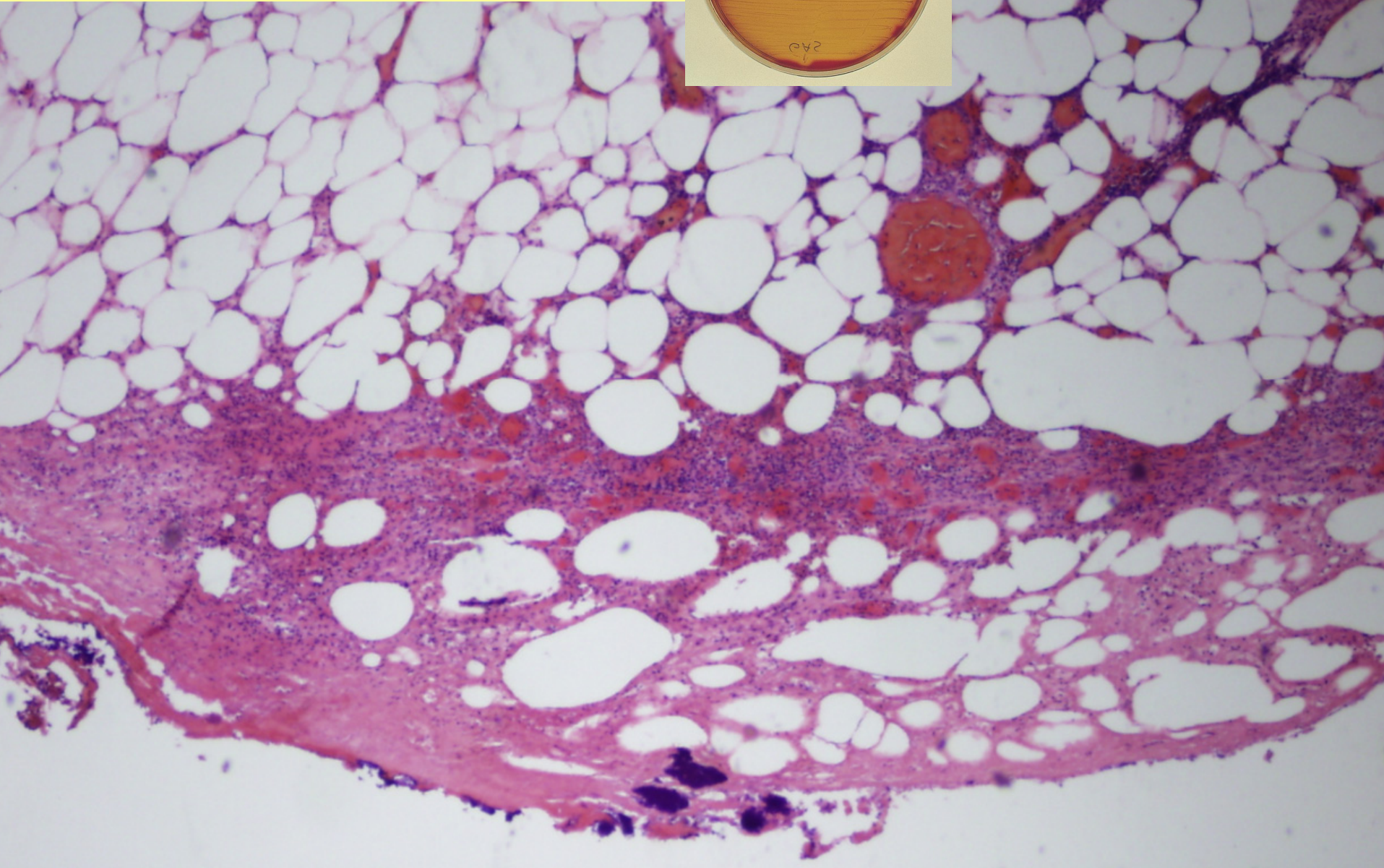
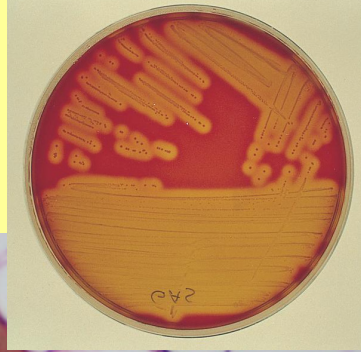




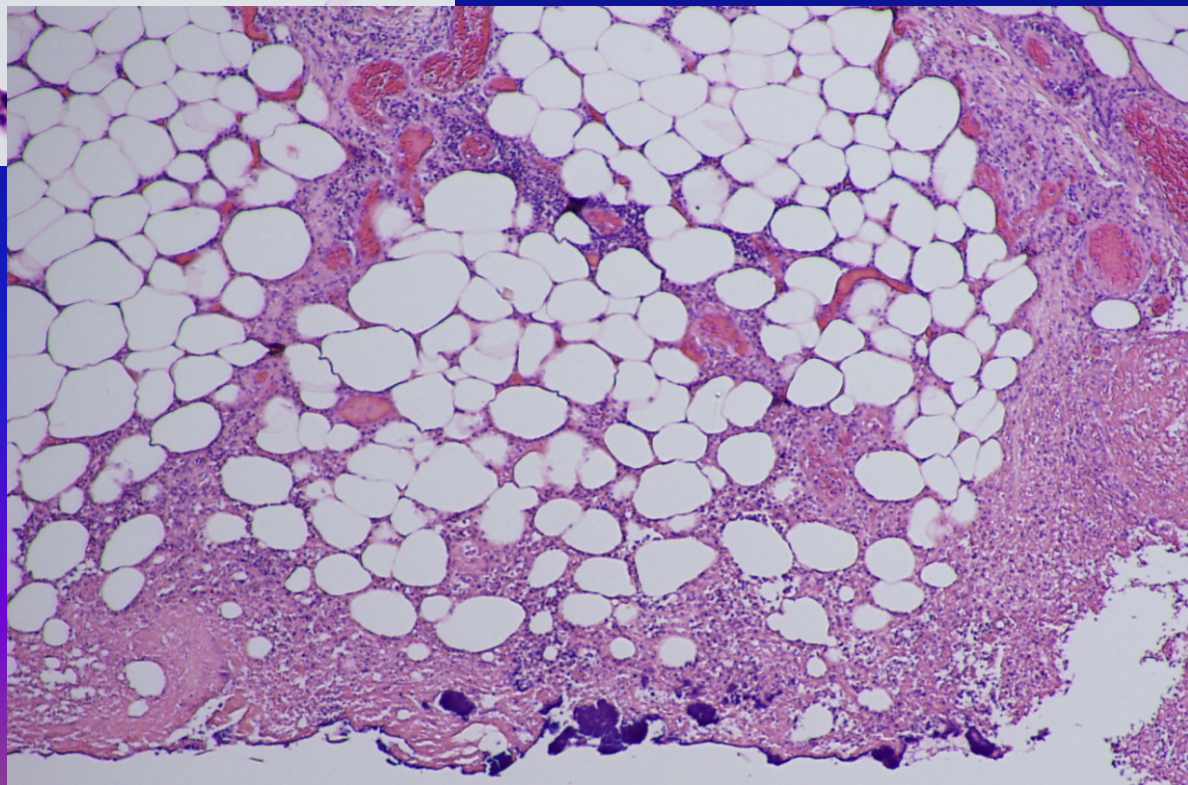
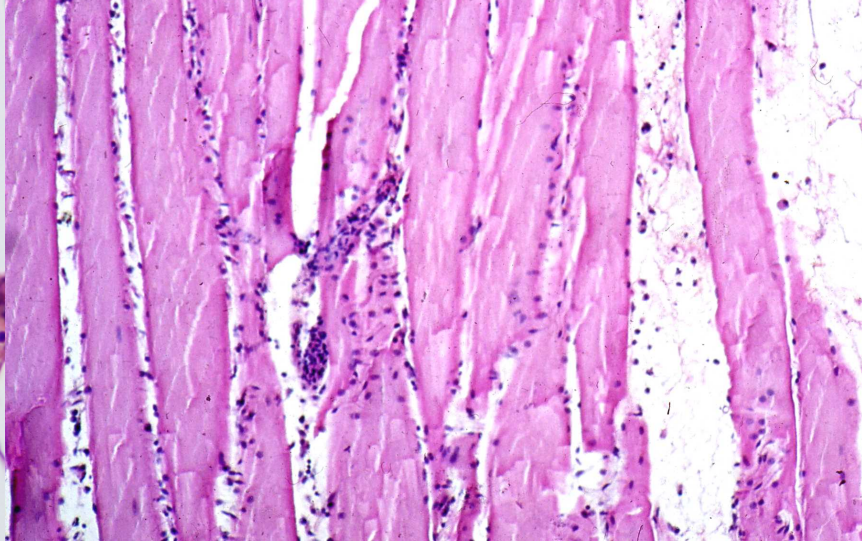
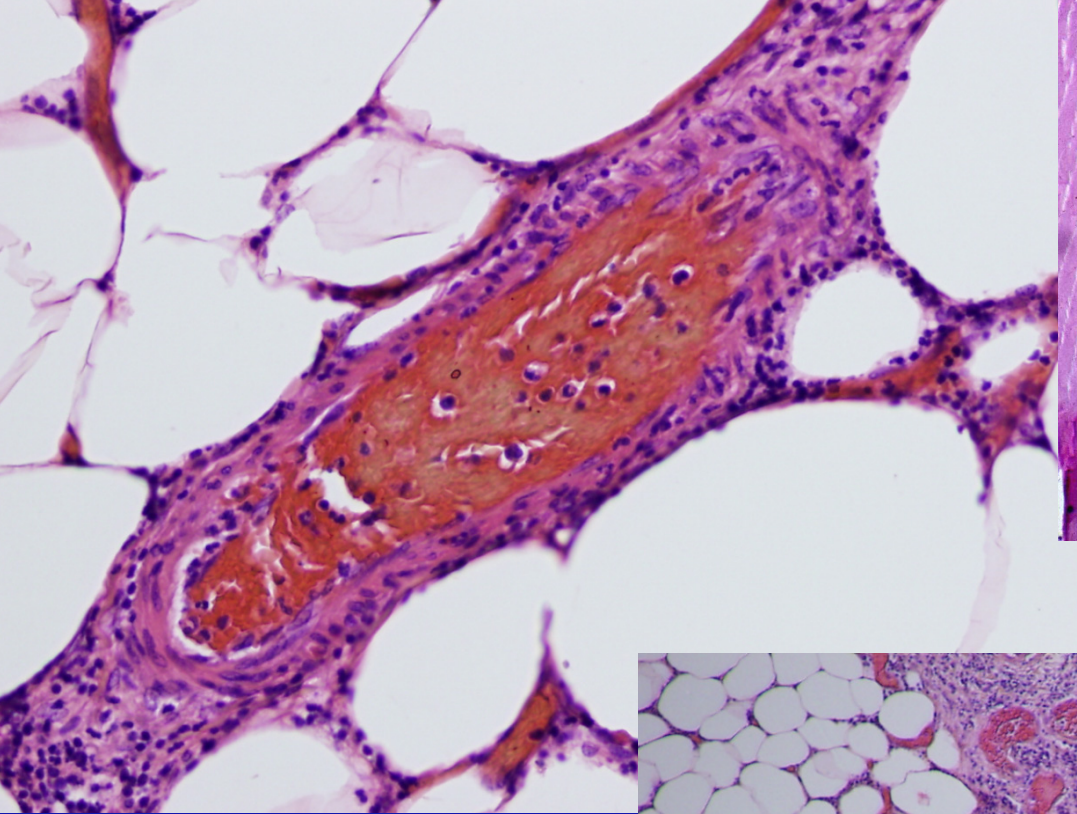




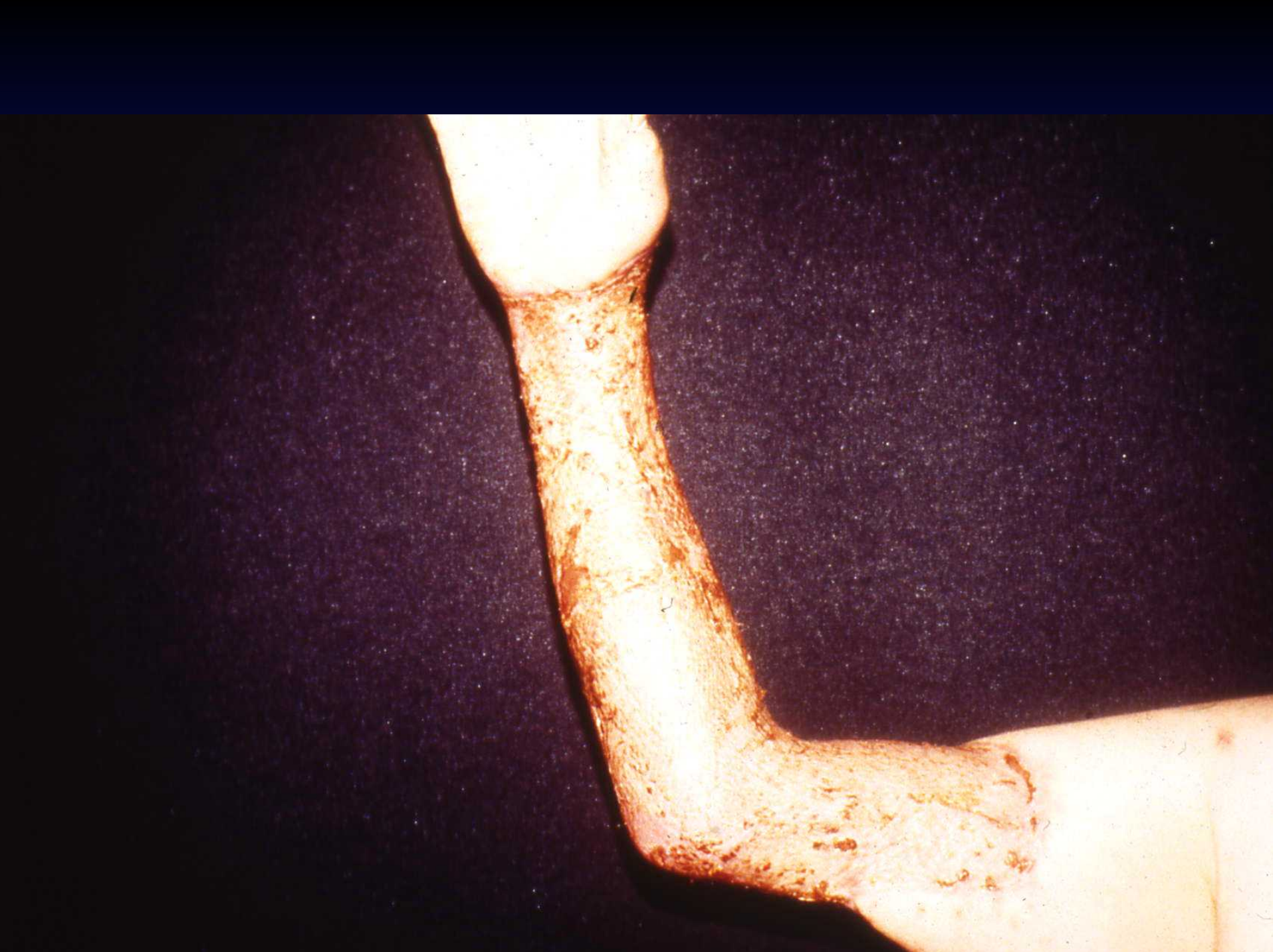# *Streptococcus pyogenes*



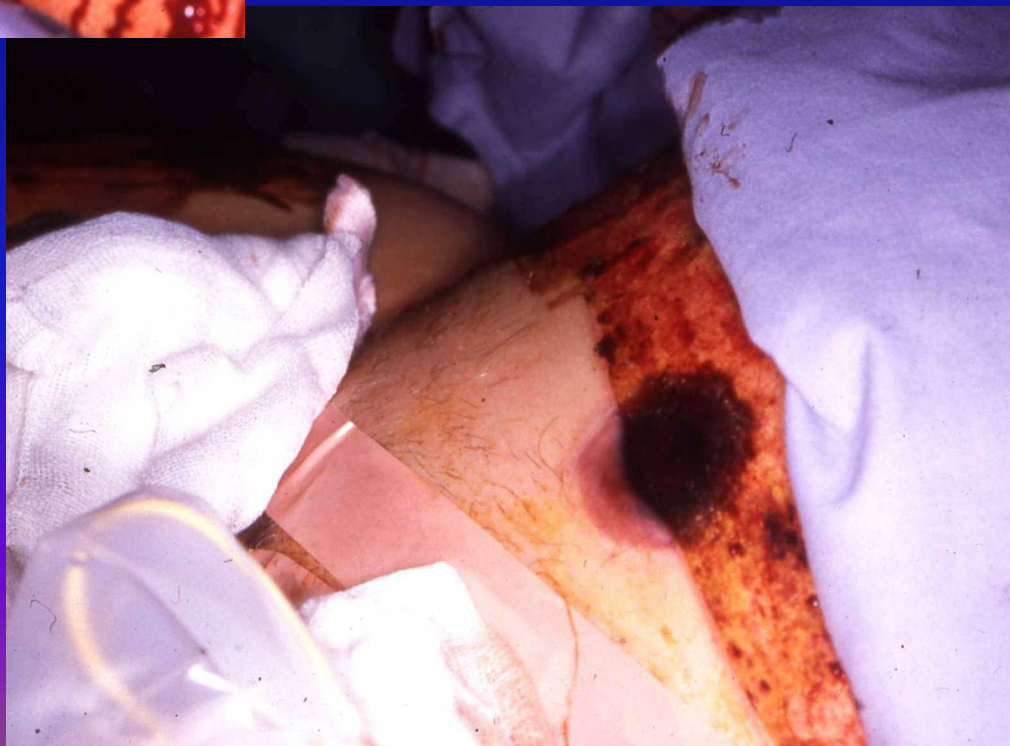
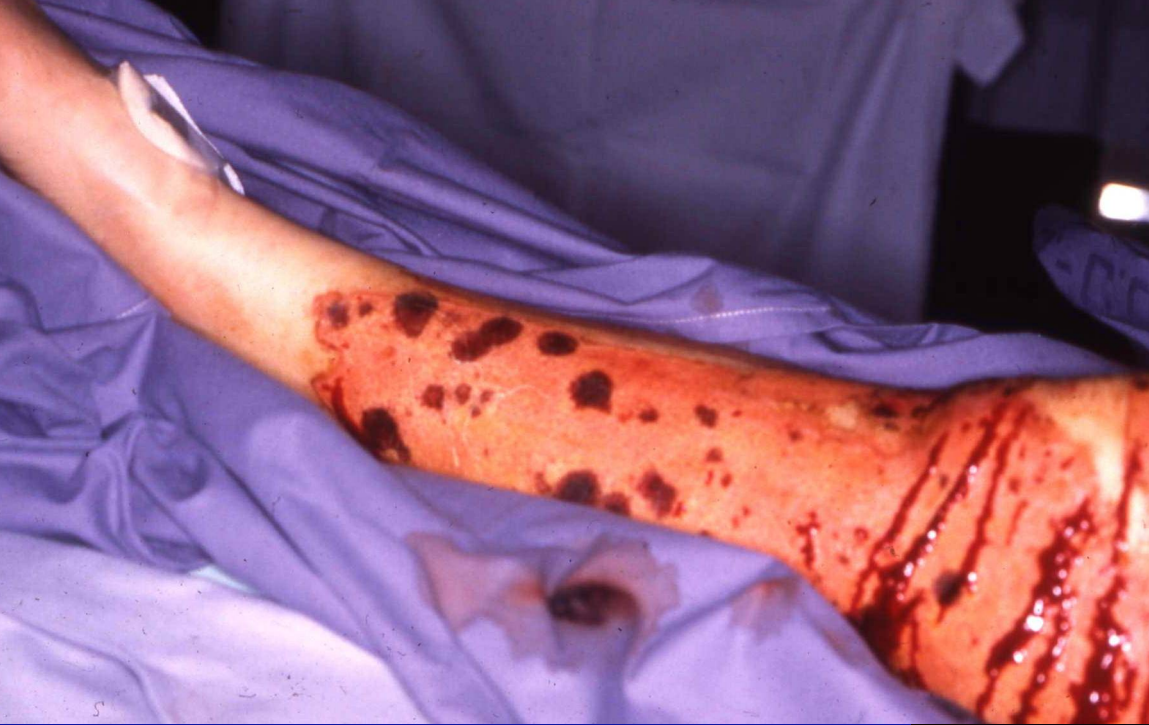


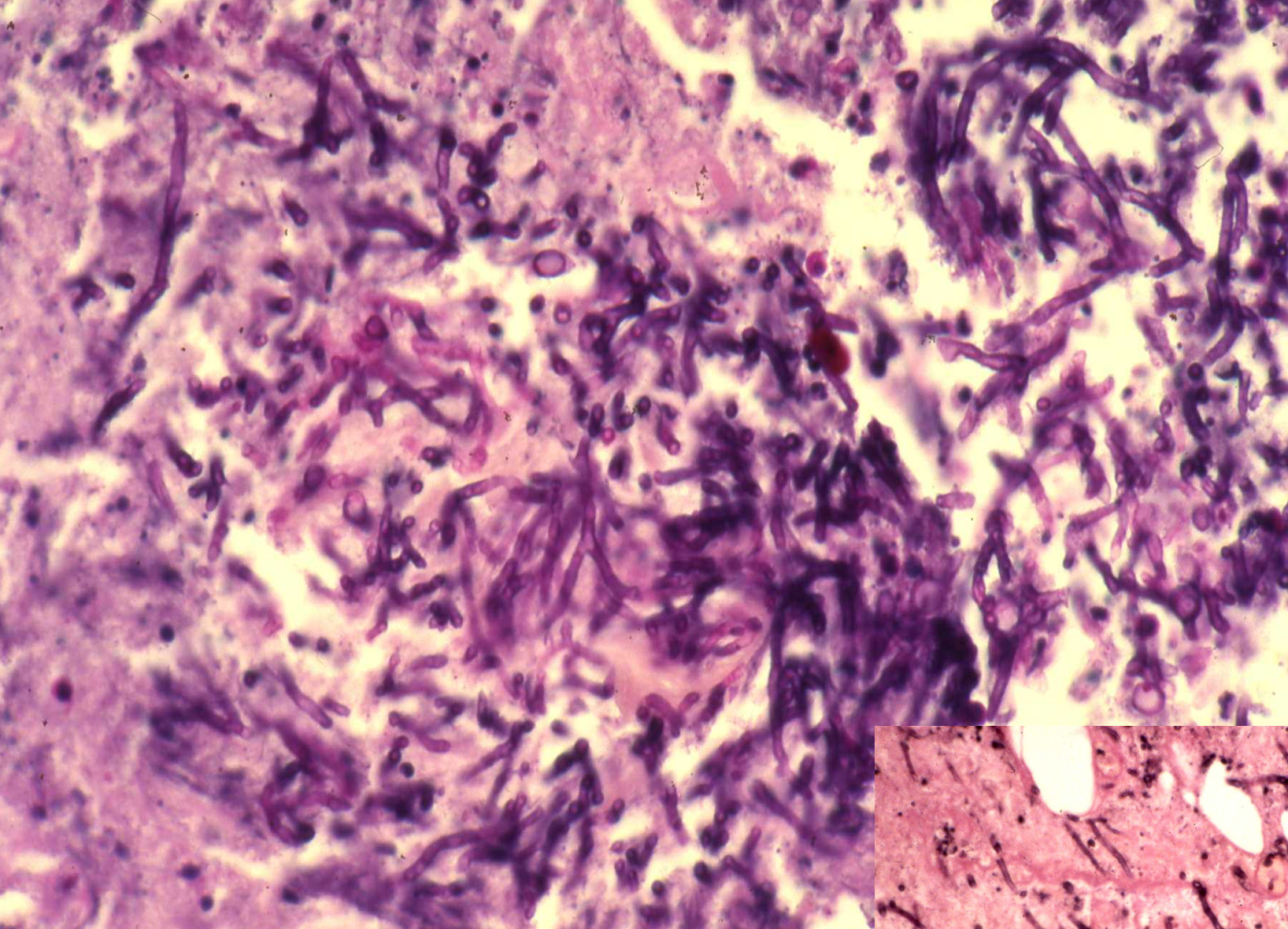




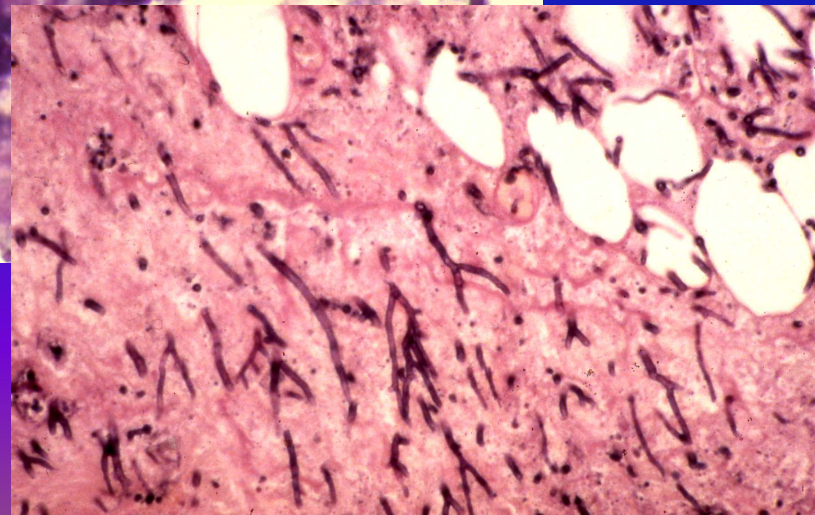




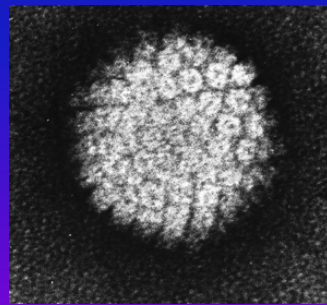
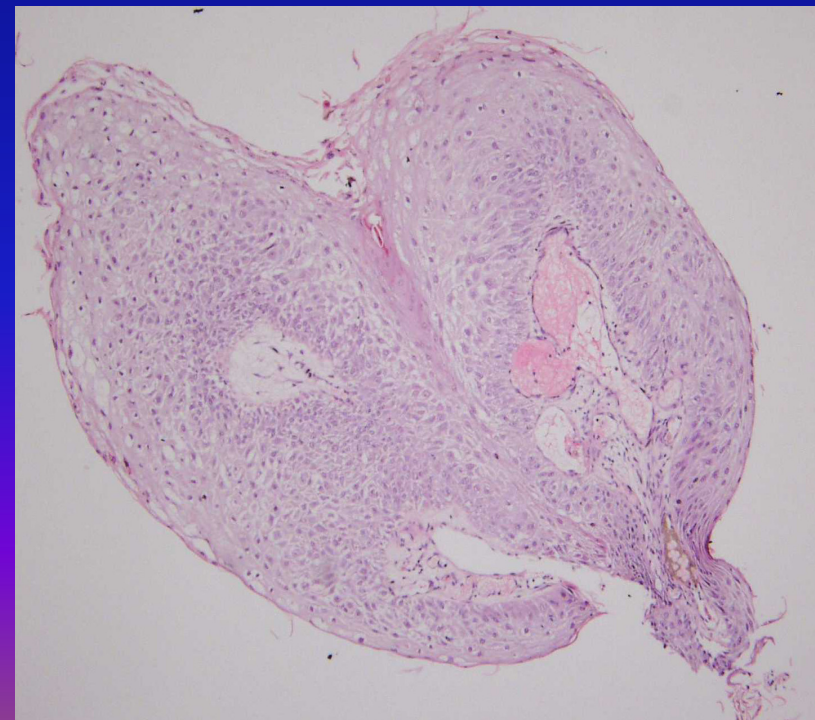
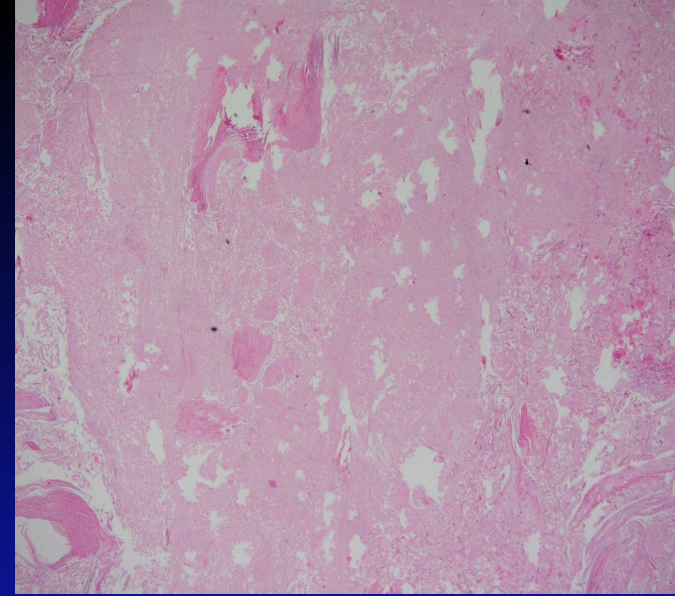
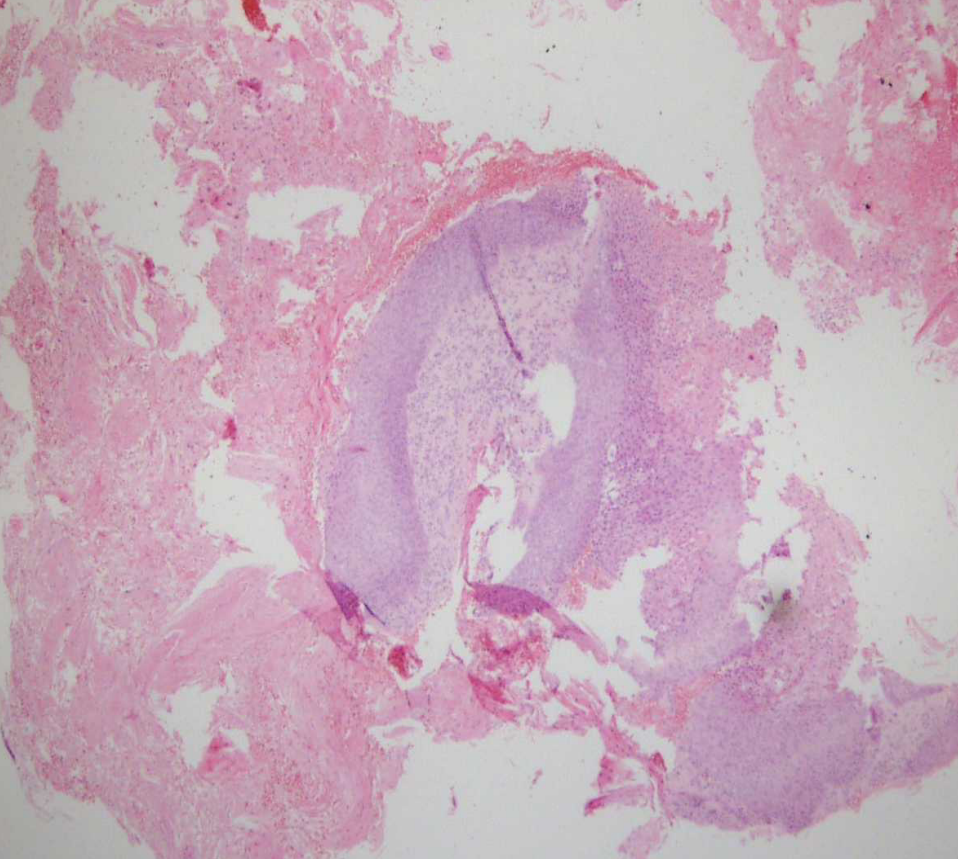




**Aspergillus**

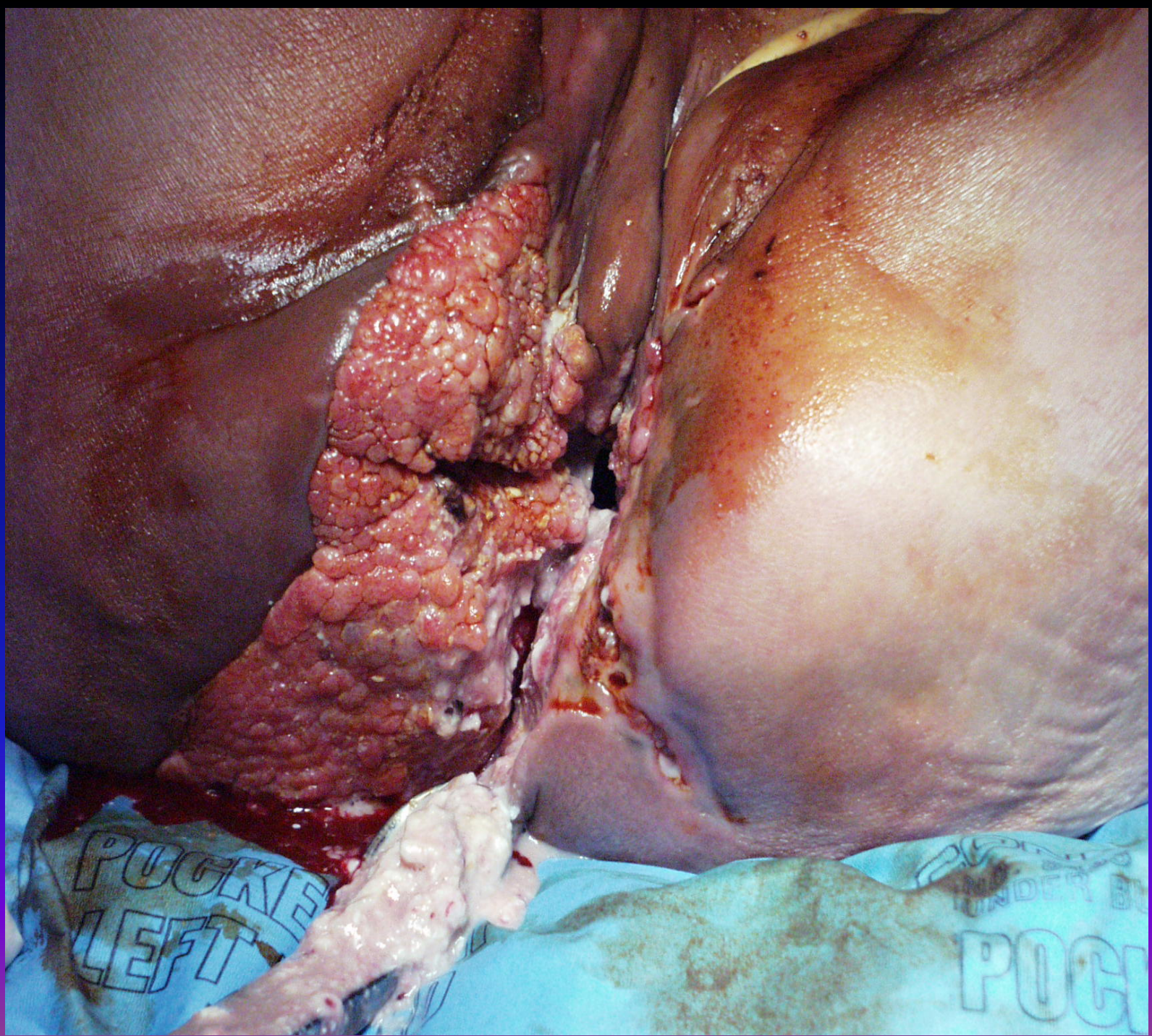






**HPV low grade**







# Conclusion

- Interest of the dermatopathology in the diagnosis of some infectious diseases
- Biopsy including subcutaneous fat
- Ulcerations: biopsy in the edge
- Blistering lesions: blister roof and biopsy at the periphery
- Frozen sections (fresh tissue)
  - Differential Diagnosis SSSS – TEN
  - Fasciitis : diagnosis and margins evaluation



# Acknowledgements

J. Borgerse

B. Cribier

J.L. Dargent

G. De Dobelear

D. Delpace

J. Demaubeuge

O. Denis

A. Kolivras

M. Laporte

N. Lateur

D. Murillo

C. Pishoudt

B. Richert

M. Song

J. Van Geertruyden

