


# A case of Acute Interstitial Nephritis and Autoimmune Hemolytic Anemia

**Denys Bart<sup>1</sup>, Caluwe Rogier<sup>1</sup>, De Raeve Hendrik<sup>2</sup>, Billiow Jean-Marie<sup>1</sup>, Van Vlem Bruno<sup>1</sup>**

<sup>1</sup> Department of Nephrology, OLV Hospital Aalst

<sup>2</sup> Department of Histopathology, OLV Hospital Aalst



**Bart Denys MD**  
Department of Nephrology  
OLV Hospital Aalst



# Case

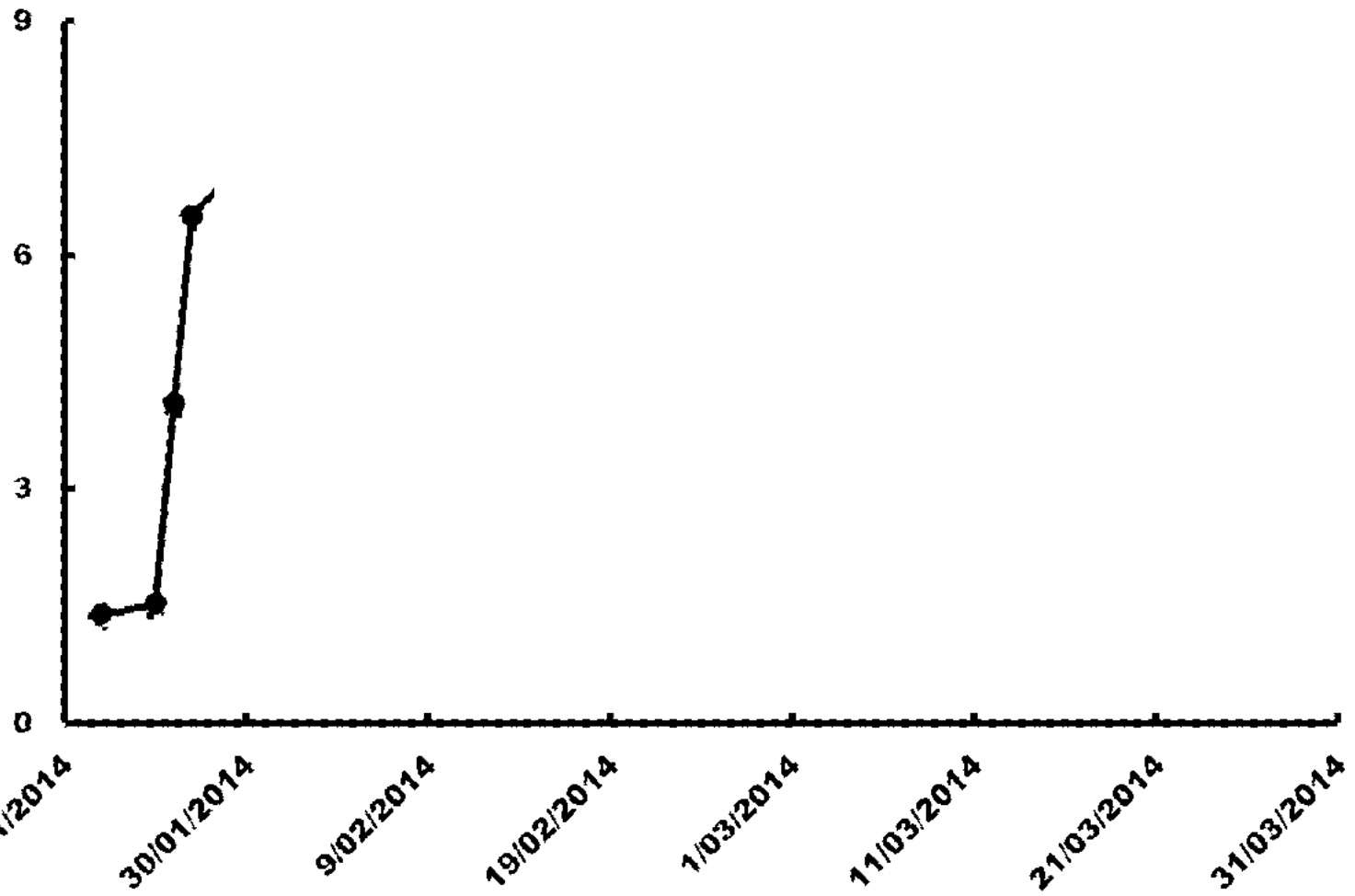
- **Man, 79 yrs**
- **22/01/2014: Emergency department: fever/chills since 2012, more frequent last months -> Gastro-enterology**
- **Chronic therapy:**
  - Asaflow 80 mg q24h
  - Simvastatin 20 mg q24h
- **Medical history:**
  - Appendectomy
  - 9/2010: Infrarenal AAA R/aneurysmectomy + prosthesis
- **Physical findings upon admission:**
  - RR 118/56; P 89 bpm; O<sub>2</sub>sat 97%; T 36.2°C
  - Negative except discrete bilateral pulmonary crepitations and bilateral pedal edema

# Case

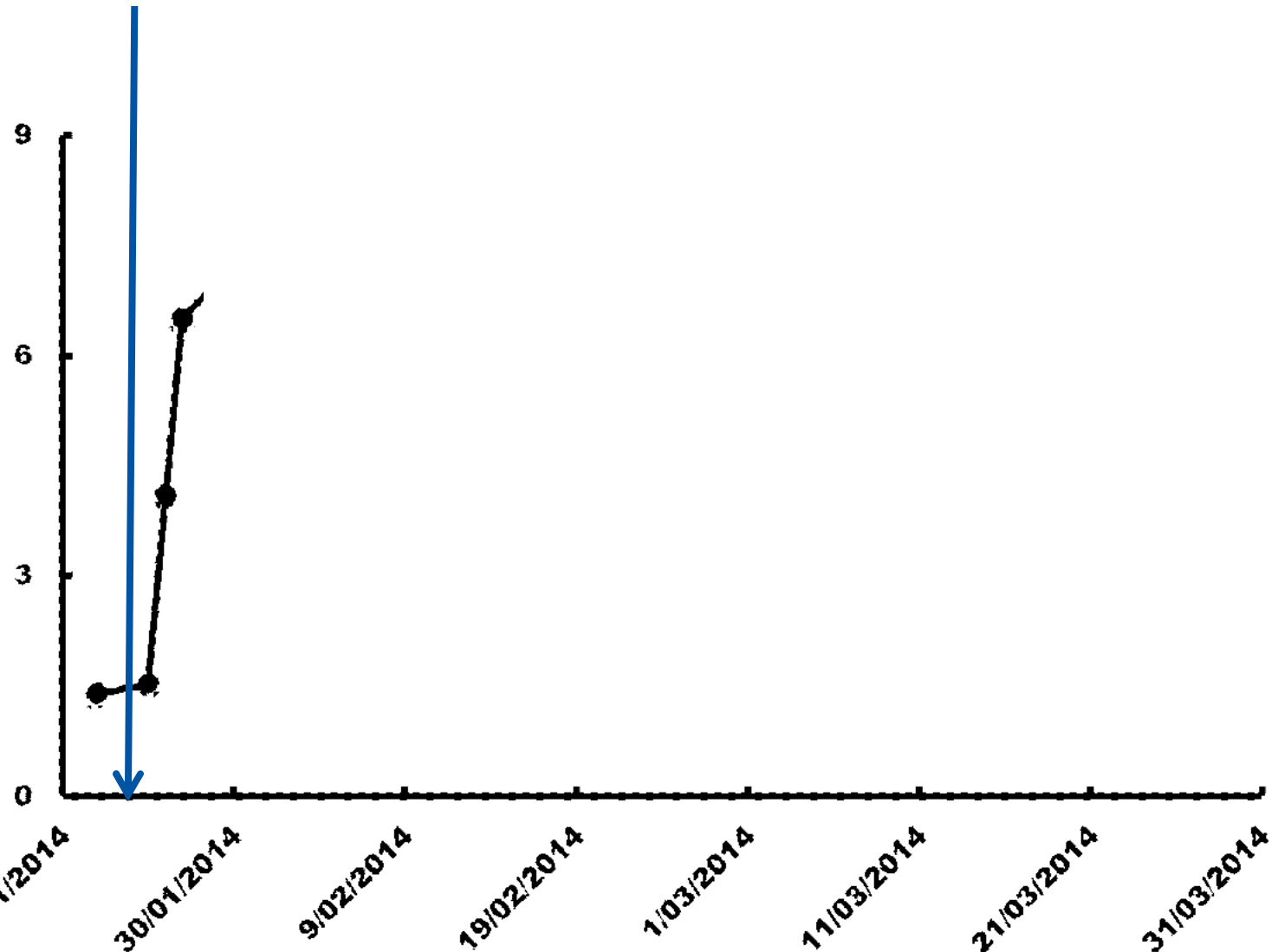
- **Laboratory values:**
  - Hb 12.4 g/dl**
  - Wbc 10200/ $\mu$ l**
    - Neutr 8710/ $\mu$ l**
    - Lymph 700/ $\mu$ l**
  - Platelets 111000/ $\mu$ l**
  - PT 95%**
  - Creat 1.39 mg/dl eGFR 49 (11/2012: 1.02 mg/dl eGFR 71)**
  - K 5.4**
  - AST 84 U/l ALT 34 U/l gGT 55 U/l AF 72 U/l LDH 438 U/l**
  - CRP 85.4 mg/l**
- **Urinary sediment/culture: negative**
- **Blood cultures: negative**
- **Radiography thorax: bilateral pleural fluid, minor**

# Case

- **Abdominal ultrasound: Splenomegaly 16x14x7 cm**
- **23/01 CT thorax/abdomen:**
  - slightly enlarged hilar adenopathy bilateral
  - some infiltration of para-aortic fat
- **TEE: no endocarditis**
- **FDG-PET: negative**
- **24-25/01: T 38.5°C -> blood cultures (neg) R/  
amoxicillin-clavulanate 4x1g IV**
- **26/01: Nephrological advice**

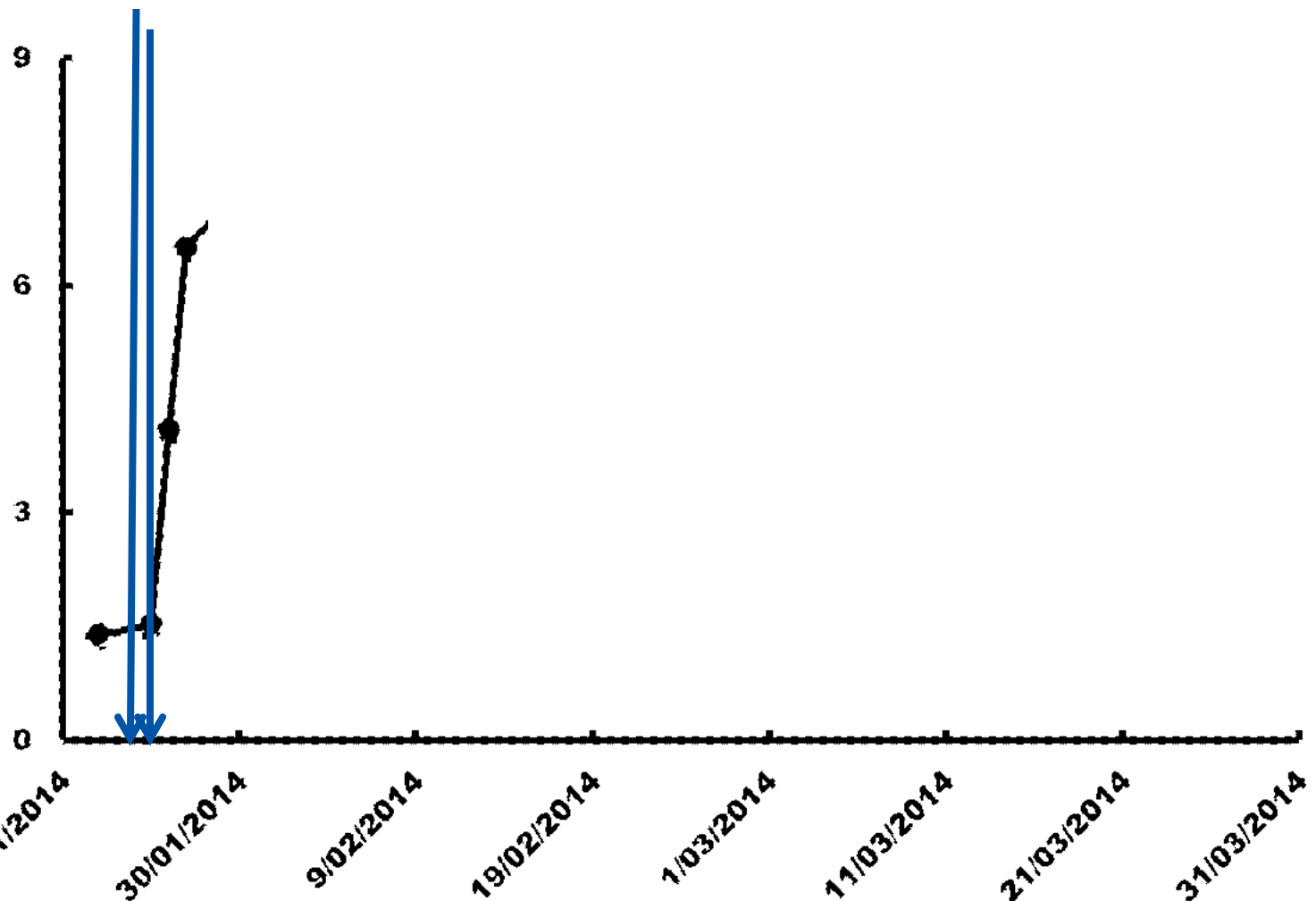


CT + contrast



— Screat (mg/dl)

CT + contrast  
|  
Amox/Clav

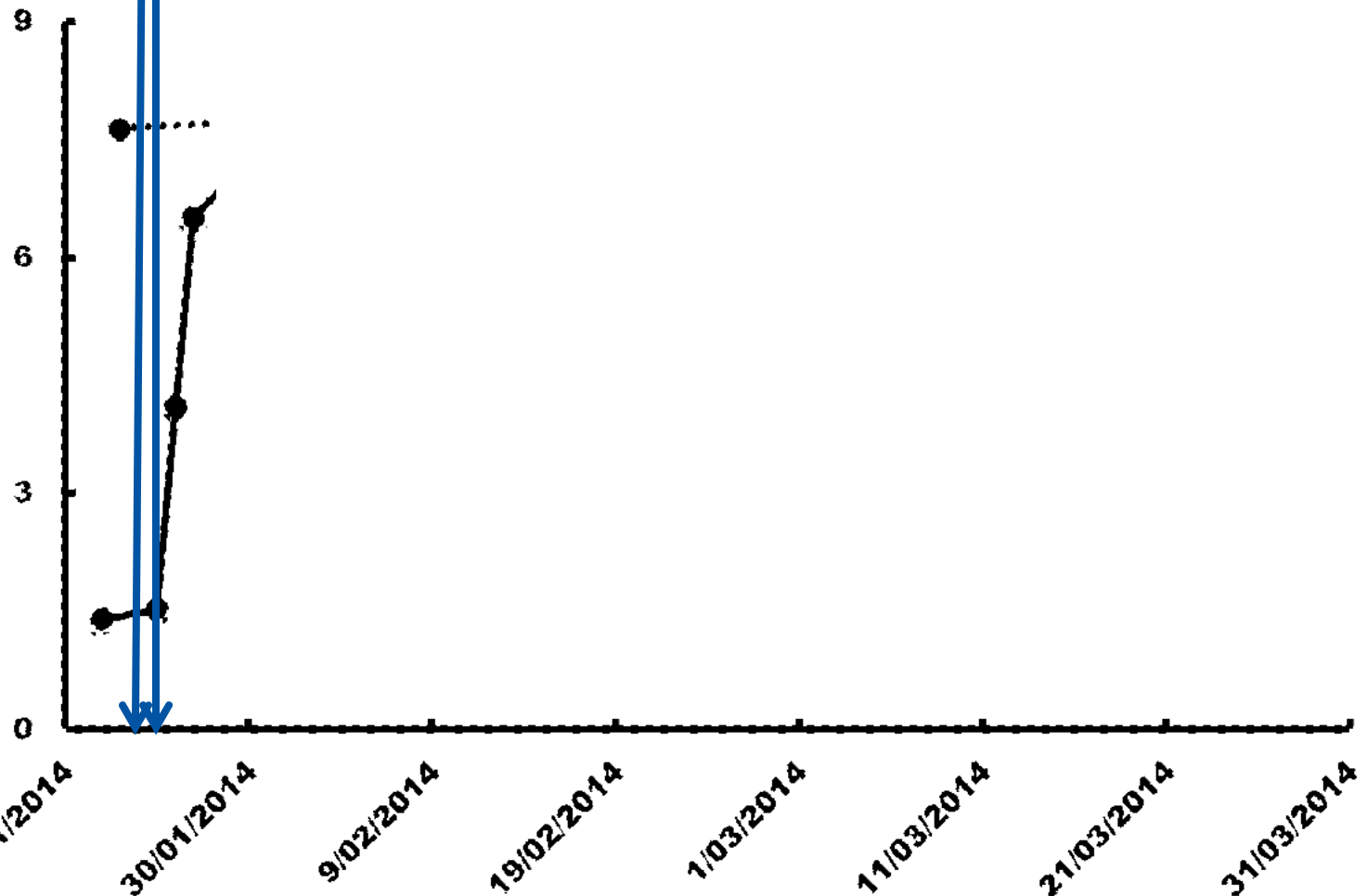


Bart Denys MD  
Department of Nephrology  
OLV Hospital Aalst

— Screat (mg/dl)



CT + contrast  
|  
Amox/Clav



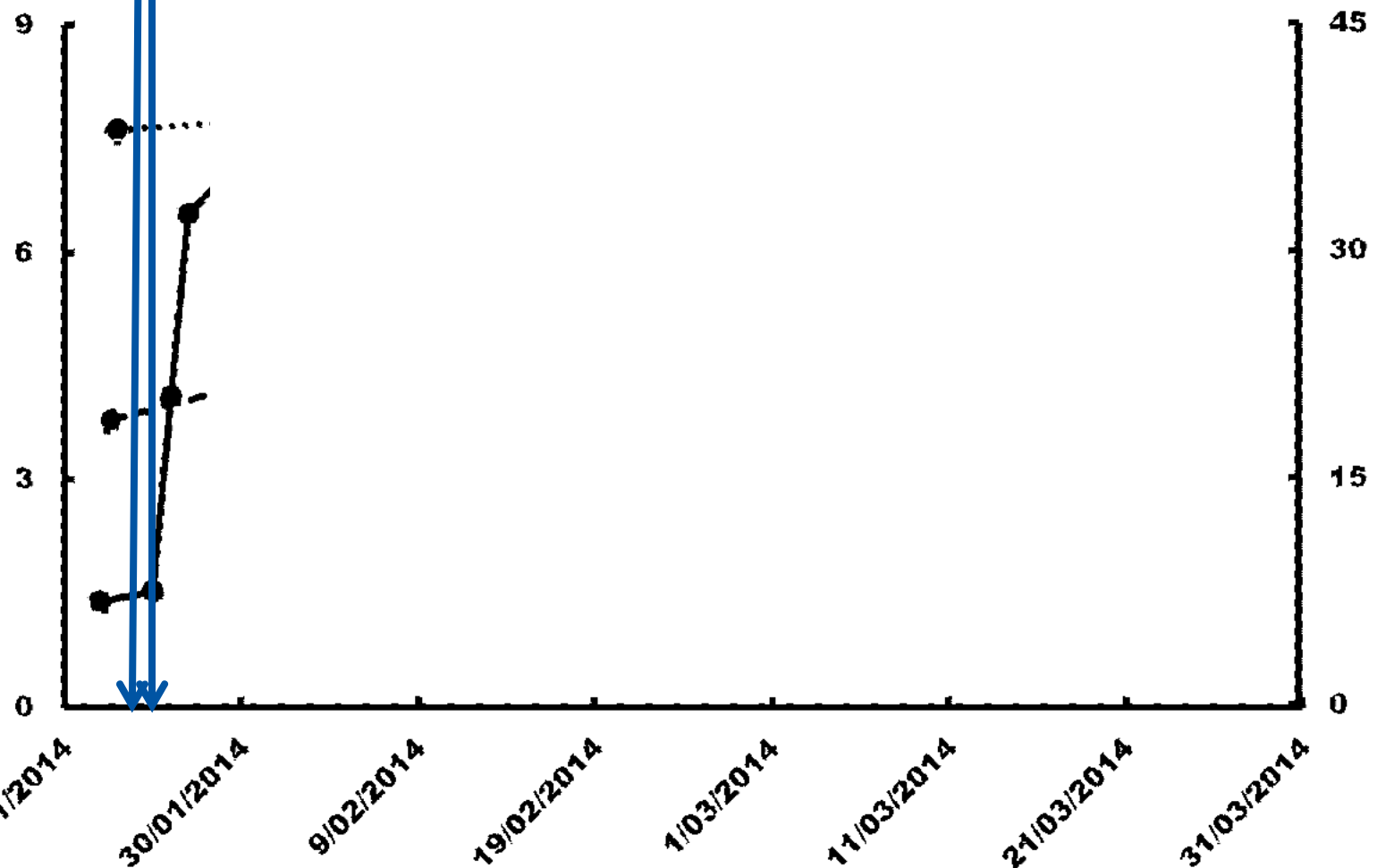
Bart Denys MD  
Department of Nephrology  
OLV Hospital Aalst

— Screat (mg/dl)  
... Proteinuria (g/g creat)





CT + contrast  
|  
Amox/Clav

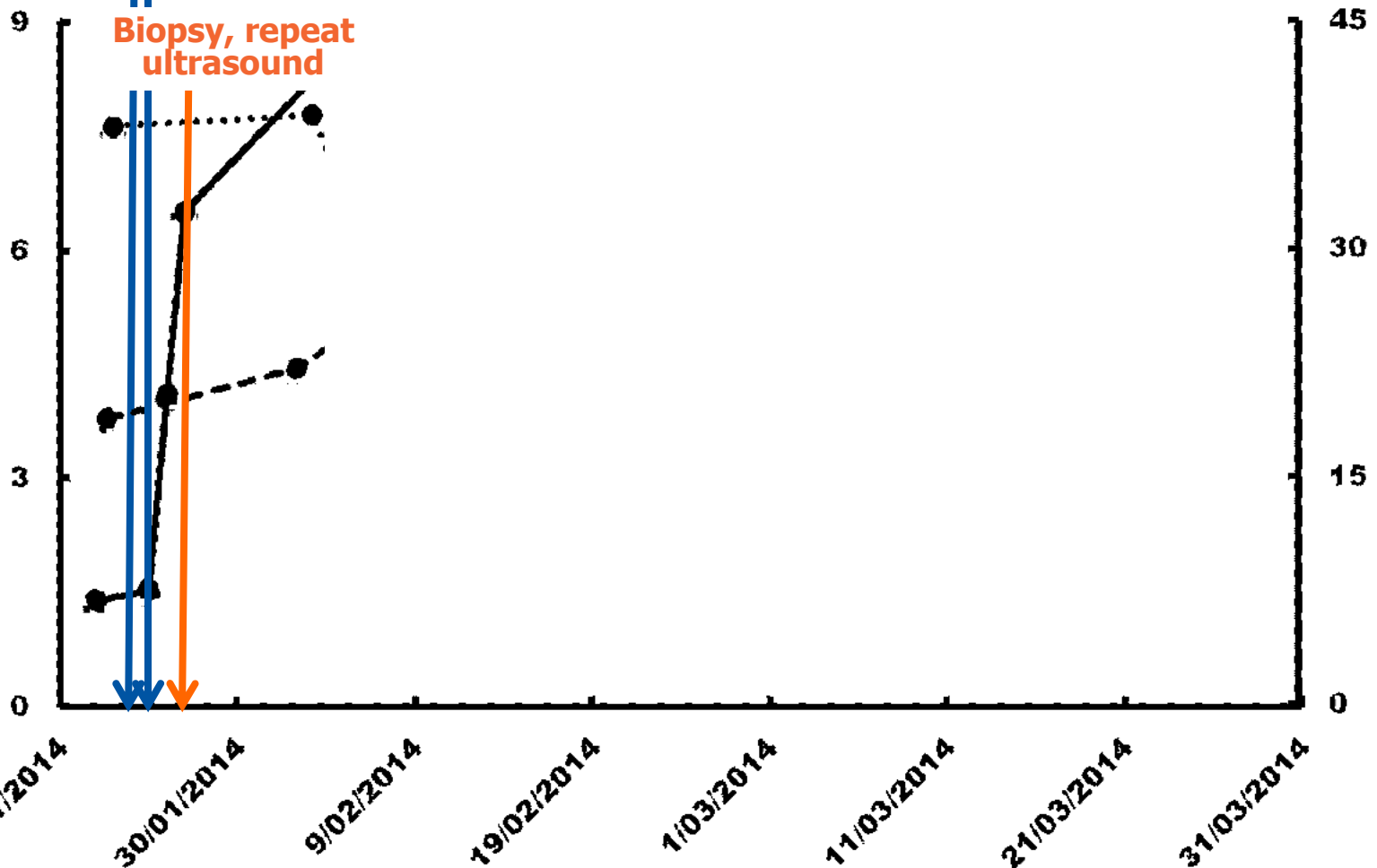


CT + contrast

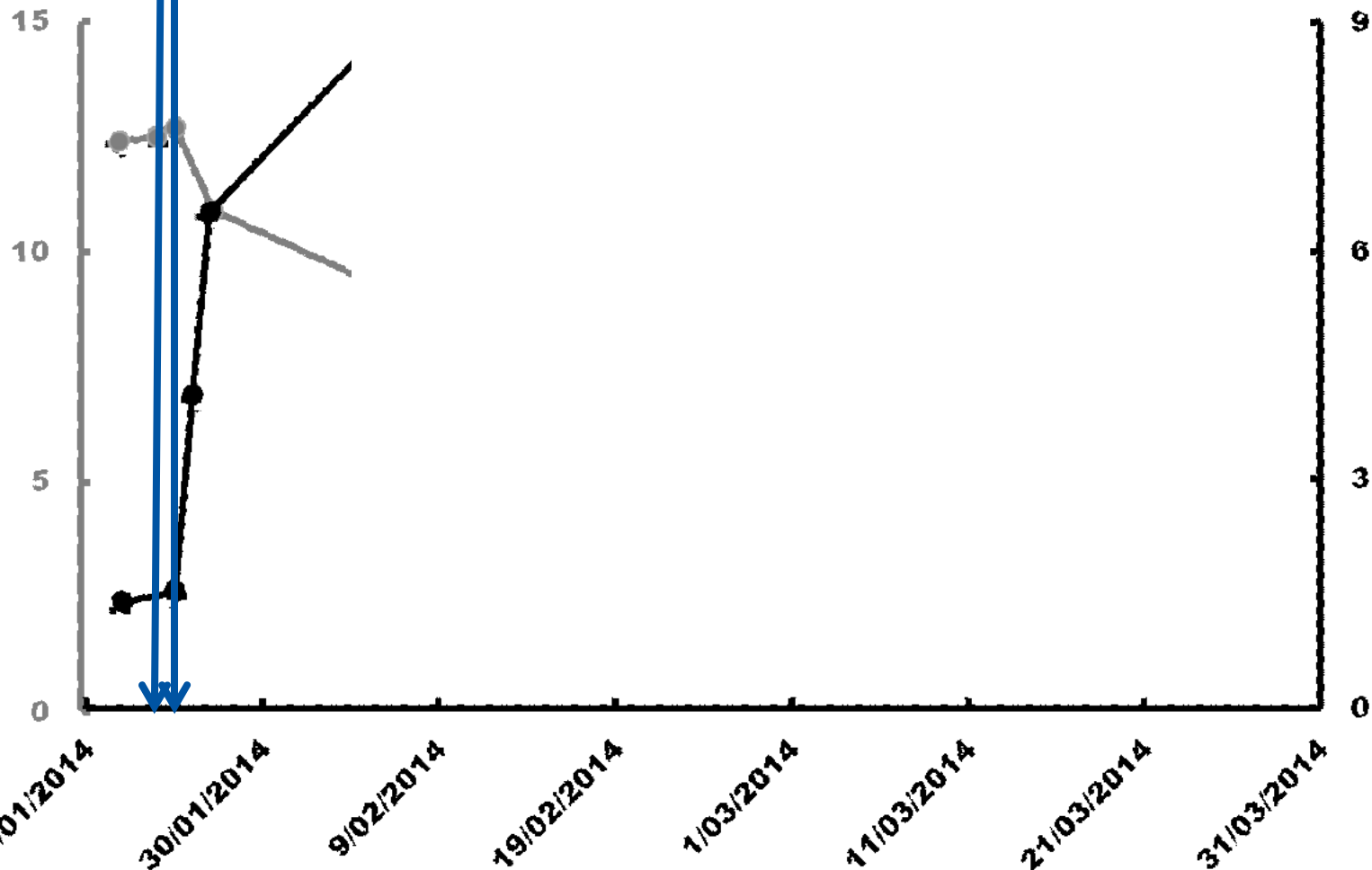
Amox/Clav

Dialysis

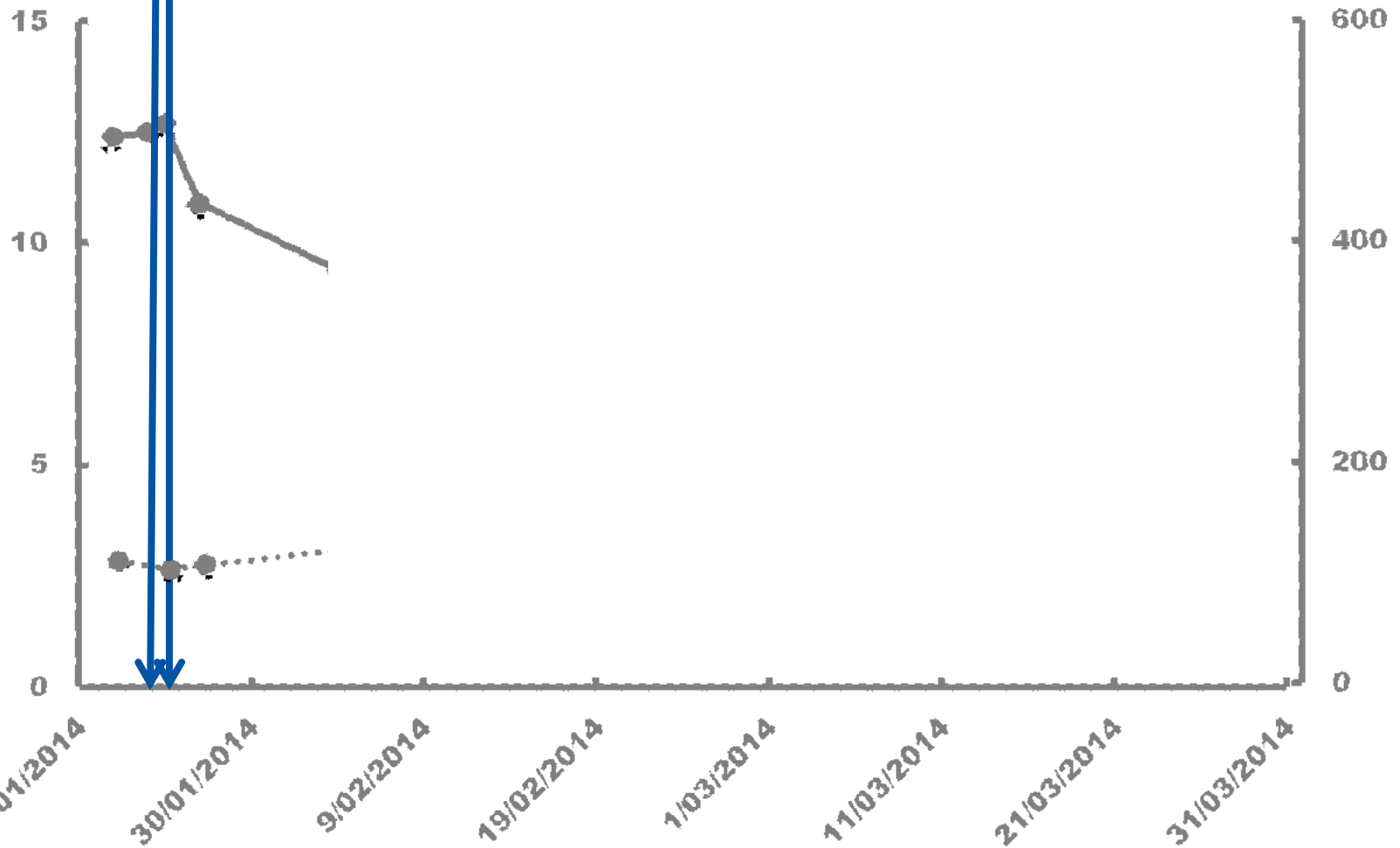
Biopsy, repeat  
ultrasound



CT + contrast  
|  
Amox/Clav



CT + contrast  
|  
Amox/Clav

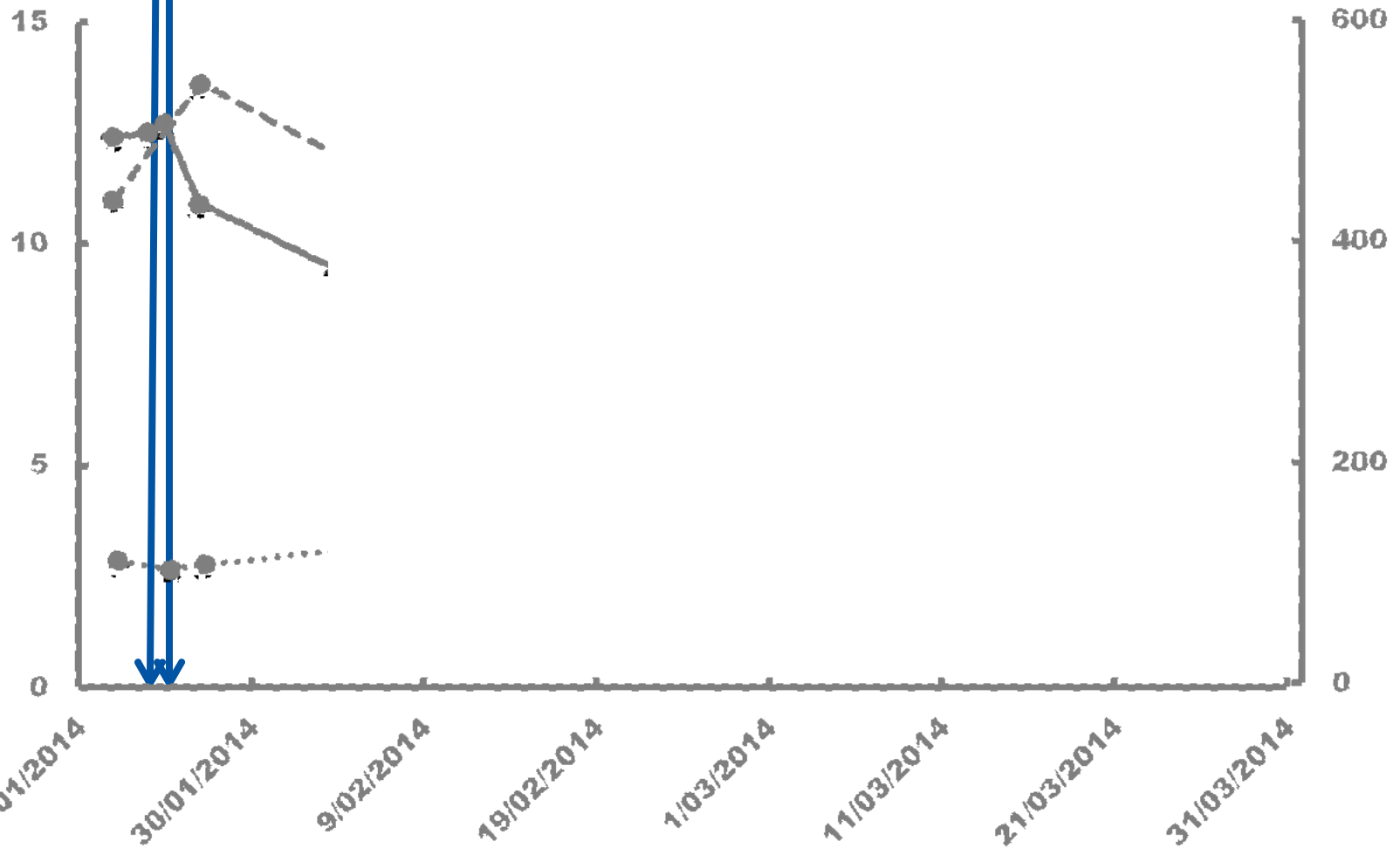


Bart Denys MD  
Department of Nephrology  
OLV Hospital Aalst

— Hb (g/dl)  
... Plt (x1000/μl)



CT + contrast  
|  
Amox/Clav

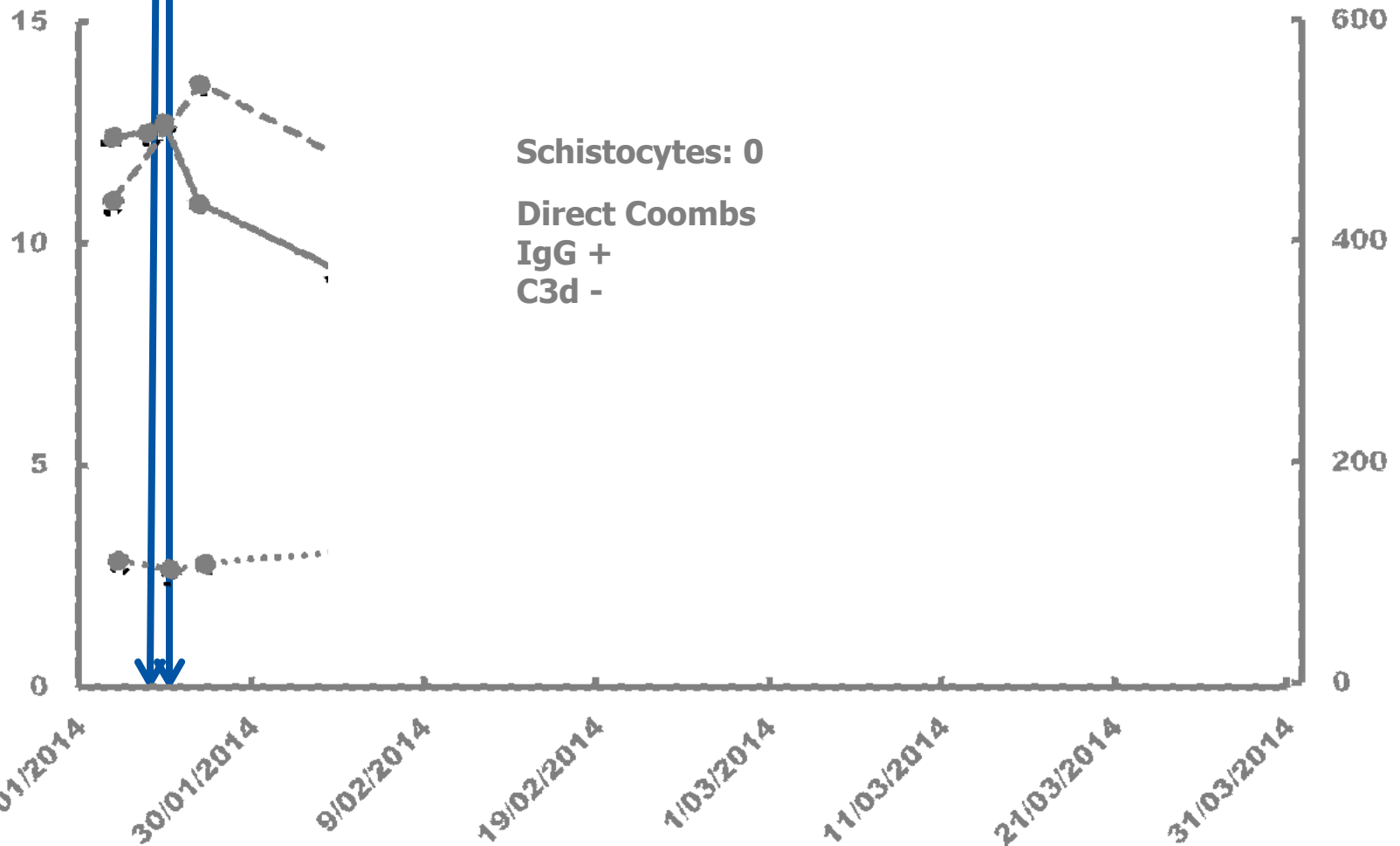


Bart Denys MD  
Department of Nephrology  
OLV Hospital Aalst

— Hb (g/dl)  
... Plt (x1000/ $\mu$ l)  
--- LDH (U/l)

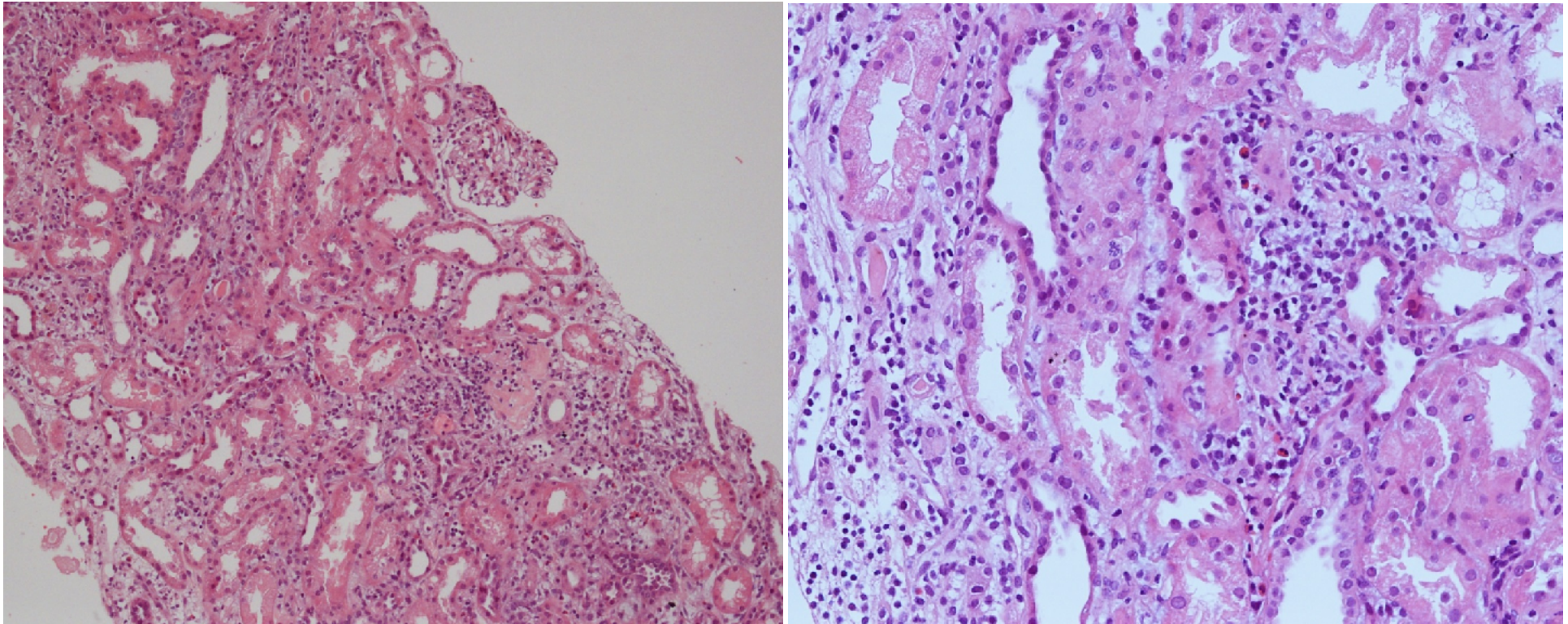


CT + contrast  
|  
Amox/Clav



Schistocytes: 0

Direct Coombs  
IgG +  
C3d -



**LM:**

**19 glomeruli, 3 sclerosed, normal cellularity, normal basement membrane, normal capillaries**

**Tubuli: minority atrophy, protein cylinders**

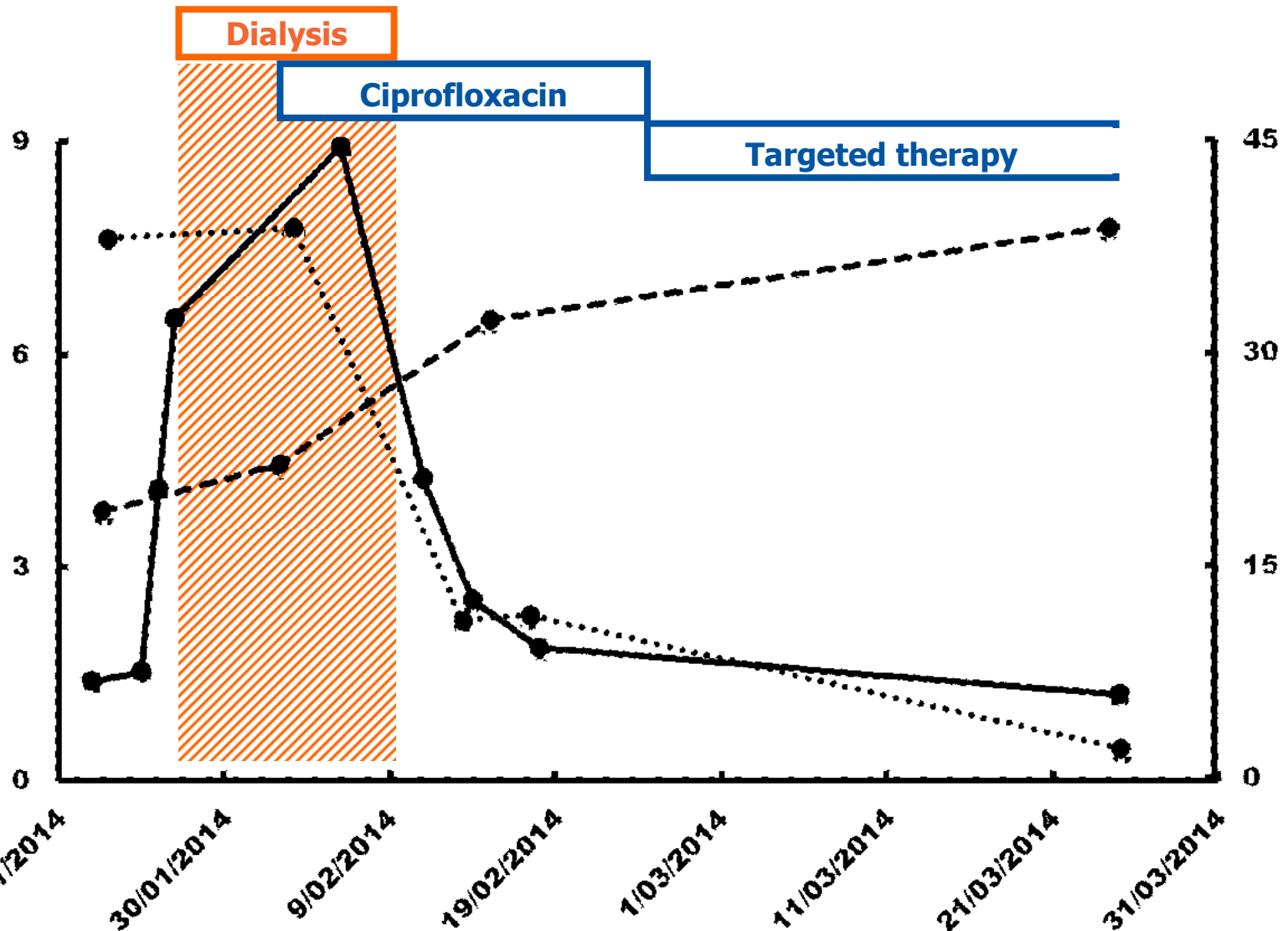
**Interstitium: some fibrosis, infiltrate (lymphocytes, plasmacells, eosinophils)**

**IF:**

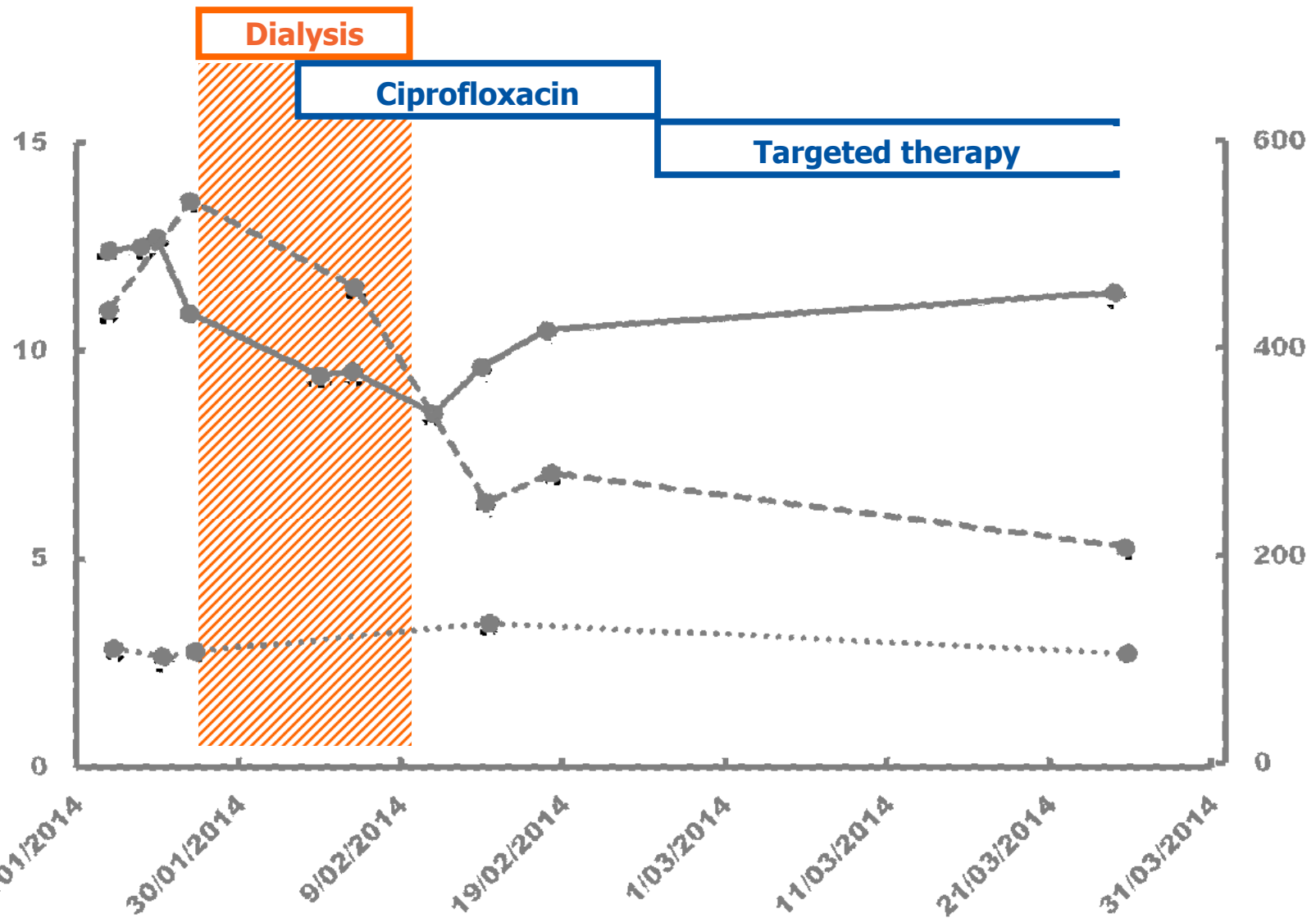
**Trace C3 and C1q. IgG, IgA, IgM, kappa, lambda negative**

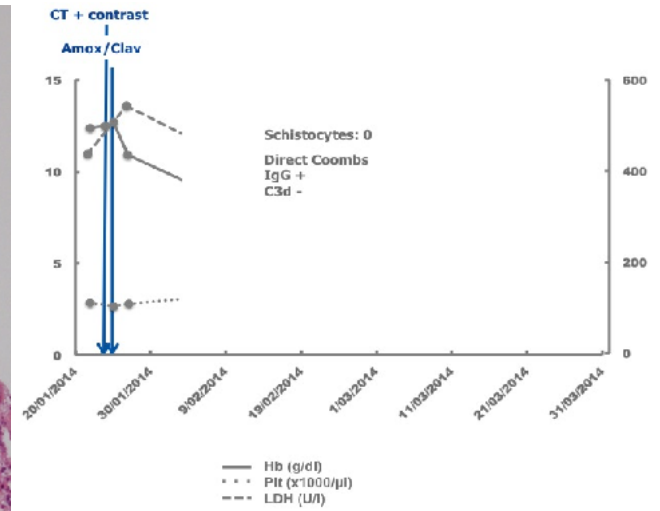
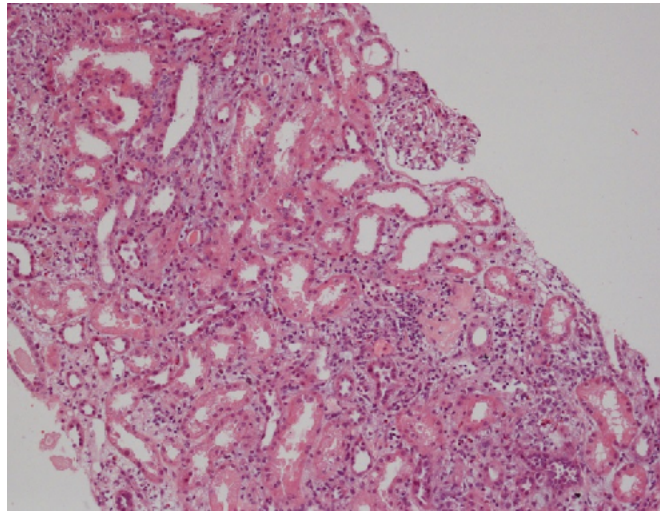
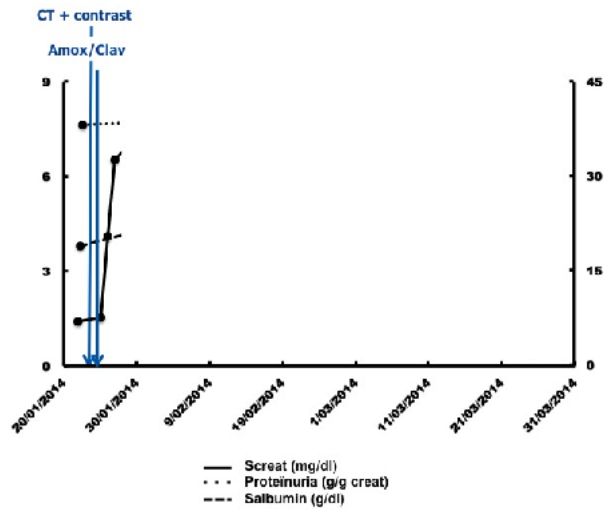
**Congo red negative**

**-> AIN**





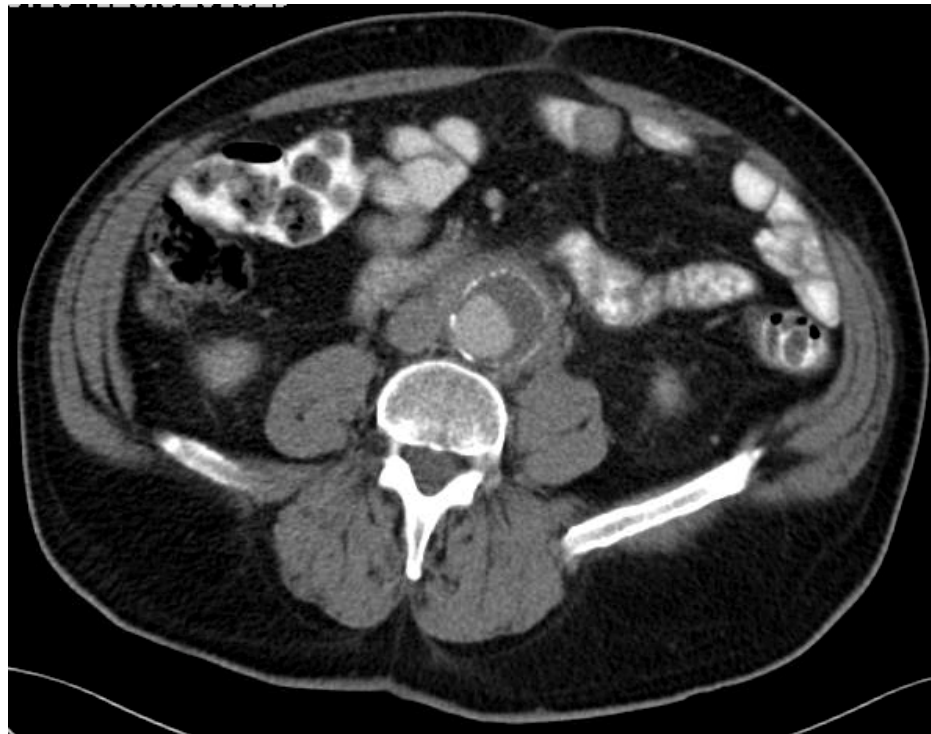



- **Man, 79 yrs**
- **Recurrent fever**
- **AIN + AIHA, splenomegaly**
  - **Etiology?**
    - **Drugs? NSAID? (-)**
    - **(AI) systemic disease? (ANF: aspecific, C3C4 nl, normocalcemia, FDG-PET -, biopsy no IgG)**
    - **Infection?**

- **Man, 79 yrs**
- **22/01/2014: Emergency department: fever/chills since 2011, more frequent last months -> Gastro-enterology**
- **Chronic therapy:**
  - **Asaflow 80 mg/d**
  - **Simvastatin 20 mg 1/d**
- **Medical history:**
  - **Appendectomy**
  - **9/2010: Infrarenal AAA R/aneurysmectomy + prosthesis**
- **Physical findings upon admission:**
  - **RR 118/56; P 89 bpm; O<sub>2</sub>sat 97%; T°C 36.2**
  - **Negative except bilateral pulmonary crepitations and bilateral pedal edema**

- **Medical history:**
  - **Appendectomy**
  - **9/2010: Infrarenal AAA R/aneurysmectomy + prosthesis**



**Infrarenal "Mycotic" AAA**

**"Mycotic" AAA**

**Fever, weight loss**

**Blood cult neg  
(incl Mycology)  
Cult res spec neg**

**CT: infection  
Ao prosthesis  
Blood cult neg**

**CT Tx/Abd: neg  
FDG-PET: small hot  
spot Ao prosthesis  
Blood cult neg**

**Resection  
Ao prosthesis**

**R/ TMP-SMX**

**R/ Expectatio**

**Good clinical/CT graphic response**

**Intermittent self-limiting fever**

09/2010

10/2010

07/2011

07/2012

11/2012

**Bart Denys MD**  
Department of Nephrology  
OLV Hospital Aalst



# Primary aortoduodenal fistula and

?

Vascular Medicine  
18(6) 347–349  
© The Author(s) 2013  
Reprints and permissions:  
sagepub.co.uk/journalsPermissions.nav  
DOI: 10.1177/1358863X13508337  
vmj.sagepub.com  


**Tim A Sigterman<sup>1</sup>, Bianca LW Bendermacher<sup>2</sup>,  
Rob JThj Welten<sup>1</sup>, Attila Krasznai<sup>1</sup> and Lee H Bouwman<sup>1</sup>**

# Microbiological Challenges in the Diagnosis of

?

Linda M. Kampschreur,<sup>a,b</sup> Jan Jelrik Oosterheert,<sup>a</sup> Annemarie M. C. Koop,<sup>a</sup> Marjolijn C. A. Wegdam-Blans,<sup>c</sup> Corine E. Delsing,<sup>d</sup> Chantal P. Bleeker-Rovers,<sup>d</sup> Monique G. L. De Jager-Leclercq,<sup>e</sup> Cornelis A. R. Groot,<sup>f</sup> Tom Sprong,<sup>d,g,h</sup> Marringje H. Nabuurs-Franssen,<sup>h</sup> Nicole H. M. Renders,<sup>i</sup> Marjo E. van Kasteren,<sup>j</sup> Yvonne Soethoudt,<sup>k</sup> Sybrandus N. Blank,<sup>l</sup> Marjolijn J. H. Pronk,<sup>m</sup> Rolf H. H. Groenwold,<sup>n</sup> Andy I. M. Hoepelman,<sup>a</sup> and Peter C. Wever<sup>i</sup>

# Unusual manifestations of

## autoimmune hemolytic anemia and tubulointerstitial nephritis

?

Serdal Korkmaz<sup>1,4\*</sup>, Nazif Elaldi<sup>2</sup>, Mansur Kayatas<sup>1</sup>, Mehmet Sencan<sup>1</sup> and Esin Yildiz<sup>3</sup>

Isolate	Co-trimoxazole	Rifampin	Tetracycline	Doxycycline	Ciprofloxacin
Nine Mile	S	S	S	S	S
Priscilla	S	S	S	S	I
Q212	S	S	S	S	I
ME1	S	S	S	S	S
ME12	S	S	S	S	I
ME3	S	S	S	S	S
ME4	S	S	S	S	I
ME5	S	S	S	S	I
ME6	S	S	S	S	I
MP7	S	S	S	S	S
ME8	S	S	S	S	S
ME9	S	S	S	S	I
MAN10	S	S	S	S	I

**Bart Denys MD**  
Department of Nephrology  
OLV Hospital Aalst



# Primary aortoduodenal fistula and Q-fever

Vascular Medicine  
18(6) 347–349  
© The Author(s) 2013  
Reprints and permissions:  
sagepub.co.uk/journalsPermissions.nav  
DOI: 10.1177/1358863X13508337  
vmj.sagepub.com  


**Tim A Sigterman<sup>1</sup>, Bianca LW Bendermacher<sup>2</sup>,  
Rob JThj Welten<sup>1</sup>, Attila Krasznai<sup>1</sup> and Lee H Bouwman<sup>1</sup>**

## Microbiological Challenges in the Diagnosis of Chronic Q Fever

Linda M. Kampschreur,<sup>a,b</sup> Jan Jelrik Oosterheert,<sup>a</sup> Annemarie M. C. Koop,<sup>a</sup> Marjolijn C. A. Wegdam-Blans,<sup>c</sup> Corine E. Delsing,<sup>d</sup> Chantal P. Bleeker-Rovers,<sup>d</sup> Monique G. L. De Jager-Leclercq,<sup>e</sup> Cornelis A. R. Groot,<sup>f</sup> Tom Sprong,<sup>d,g,h</sup> Marringje H. Nabuurs-Franssen,<sup>h</sup> Nicole H. M. Renders,<sup>i</sup> Marjo E. van Kasteren,<sup>j</sup> Yvonne Soethoudt,<sup>k</sup> Sybrandus N. Blank,<sup>l</sup> Marjolijn J. H. Pronk,<sup>m</sup> Rolf H. H. Groenwold,<sup>n</sup> Andy I. M. Hoepelman,<sup>a</sup> and Peter C. Wever<sup>i</sup>

## Unusual manifestations of acute Q fever: autoimmune hemolytic anemia and tubulointerstitial nephritis

Serdal Korkmaz<sup>1,4\*</sup>, Nazif Elaldi<sup>2</sup>, Mansur Kayatas<sup>1</sup>, Mehmet Sencan<sup>1</sup> and Esin Yildiz<sup>3</sup>

Isolate	Co-trimoxazole	Rifampin	Tetracycline	Doxycycline	Ciprofloxacin
Nine Mile	S	S	S	S	S
Priscilla	S	S	S	S	I
Q212	S	S	S	S	I
ME1	S	S	S	S	S
ME12	S	S	S	S	I
ME3	S	S	S	S	S
ME4	S	S	S	S	I
ME5	S	S	S	S	I
ME6	S	S	S	S	I
MP7	S	S	S	S	S
ME8	S	S	S	S	S
ME9	S	S	S	S	I
MAN10	S	S	S	S	I

ANTIMICROBIAL AGENTS AND CHEMOTHERAPY, Oct. 1991, p. 2070–2077

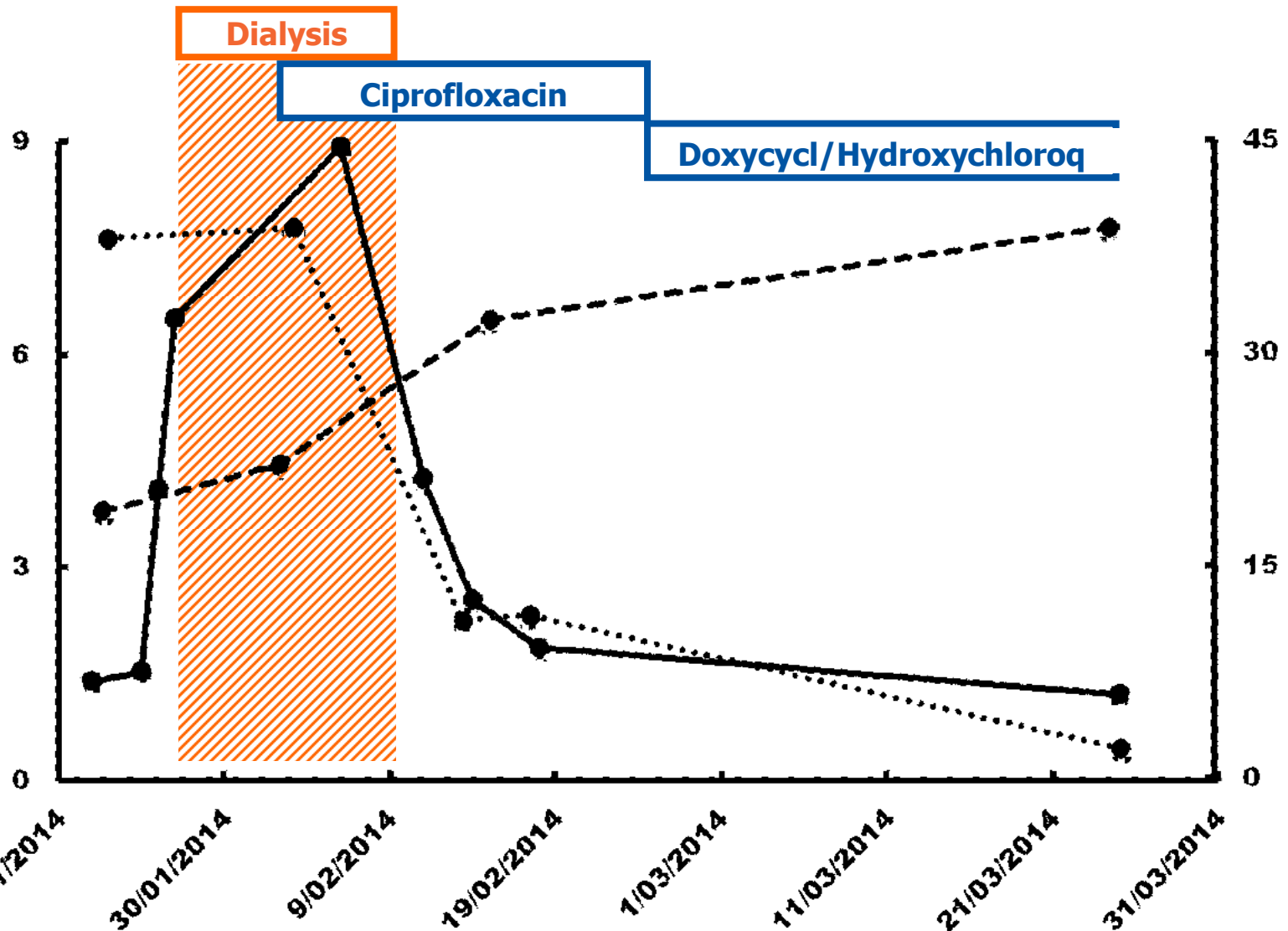
**Bart Denys MD**  
Department of Nephrology  
OLV Hospital Aalst



## **C. Burnetii**

<b>IgG Phase I</b>	<b>1/1024</b>
<b>IgG Phase II</b>	<b>1/256</b>
<b>IgM Phase I</b>	<b>&lt;1/32</b>
<b>IgM Phase II</b>	<b>&lt;1/32</b>







**Bart Denys MD**  
Department of Nephrology  
OLV Hospital Aalst

